

## Pulmonary Alveolar Microlithiasis in Saudi Child: A Case Report

Abdullah Al-Shamrani<sup>1</sup>, Safa Eltahir<sup>2</sup>, Gawahir Mukhtar<sup>3</sup>, Mohammed Al-Belawi<sup>4</sup>, Wadha Alotaibi<sup>5</sup>

<sup>1</sup>Prince Sultan Medical Military City (PSMMC), <sup>2</sup>Pediatric Pulmonary Division, King Fahad Medical City (KFMC), <sup>3</sup> Pediatric Pulmonary Division, KFMC, <sup>4</sup> Pediatric Pulmonary Fellow, KFMC, <sup>5</sup>Pediatric Pulmonary and Sleep Physician, Head of the Pulmonary Unit, KFMC, KSA

Corresponding author: Abdullah Al-Shamrani, Email: Shamrani999@hotmail.com, Orcid.org/0000-0001-7157-1706, Mobile no.: 00966553367555

### ABSTRACT

**Background:** Pulmonary alveolar microlithiasis (PAM) is a rare but not uncommon disease; it showed worldwide distribution either familial or sporadic, the most reported cases in Europe, especially in Turkey. The presence of round shaped little bodies containing concentric calcareous lamellas in pulmonary alveolus is the hallmark of the disease. With this study, we report a case of PAM in Arabic descent, a Saudi child, who represented the most characteristics of the disease in dissociation between definite radiological pattern of the lungs and relatively poor clinical symptoms. **Case Presentation:** A-9-year-old Arabic female, presented with occasional nonproductive cough for one year, the patient suspected miliary TB and received antituberculous therapy. Examination: Revealed well pleasant child with finger clubbing and clear chest. The patient followed for two years, with marginal deterioration in her general condition. **Conclusion:** Here, we reported a sporadic case of PAM in Saudi child that presented with nonspecific clinical picture, which resulted in misdiagnosis and consequently improper management. The case proves the slowly progression of the disease.

**Keywords:** Pulmonary alveolar microlithiasis. PAM, Saudi origin, Pediatrics.

### INTRODUCTION

Pulmonary Alveolar Microlithiasis (PAM) is a rare but not uncommon disease, it showed a worldwide distribution <sup>(1)</sup>, it is caused by mutation of the *SLC34A2* gene encoding type IIb sodium phosphate receptor in the alveolar type II cells, sporadic cases were reported too <sup>(2)</sup>. The presence of round shaped little bodies containing concentric calcareous lamellas in pulmonary alveolus is the hallmark of the disease <sup>(3)</sup>. Although it is common between 20-30 years of age but pediatric and neonatal cases were reported (Mariani with Lopez <sup>(4)</sup>). It affects both genders equally. PAM considered idiopathic in spite of the various etiological theories that were reported in the literature. Genetic theory was the most accepted one, with autosomal recessive mode of inheritance. Genetic analysis revealed that there is heterogeneous mutation of *SLC34A2* gene, which is responsible for the familial PAM <sup>(5)</sup>. The most characteristics of the disease is **disassociation between definite x-ray pattern of lungs and relative poor clinical symptoms**. PAM showed varies scenarios and clinical presentations that may make it undiagnosed for a long time. Moreover, being rare it usually comes at the bottom list of differential diagnosis that may further delay early diagnosis. The disease is a progressive disease and can lead to serious respiratory complications and pulmonary hypertension <sup>(6)</sup>.

### CASE PRESENTATION

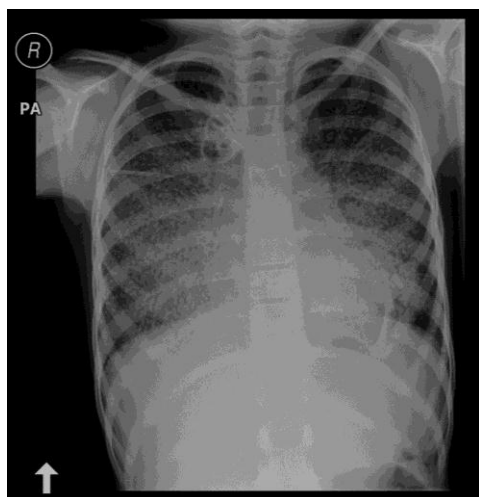
A 9 years old Arabic female presented with occasional cough that is dry without any

precipitating or relieving factors for one year. The patient suspected to be a case of miliary TB for which she received anti-TB therapy for almost 3 months with no improvement. Family history did not show similar or respiratory chronic conditions.

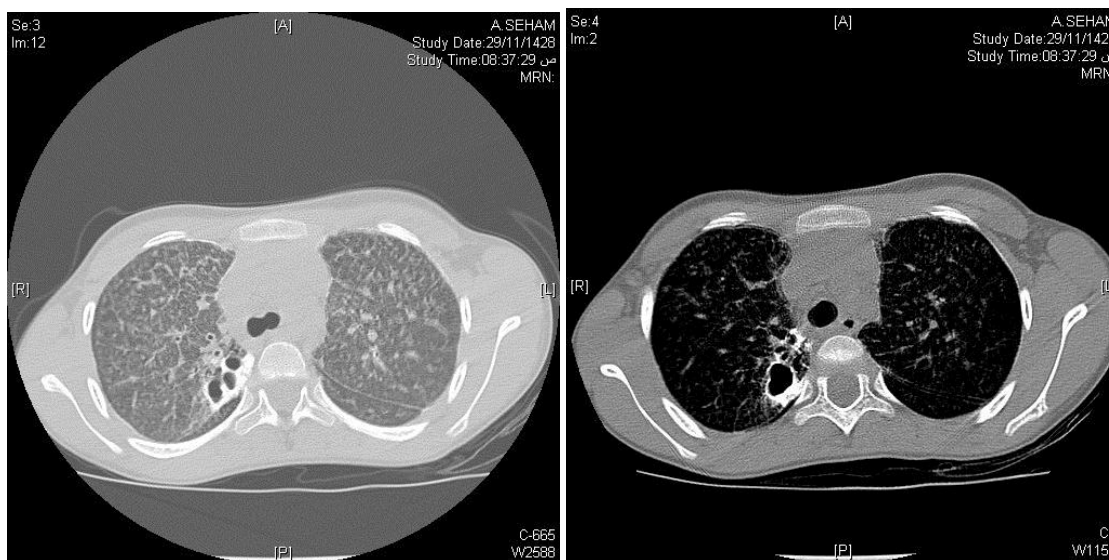
**On examination**, the patient was well pleasant with positive finger clubbing grade 1, no lymph adenopathy, positive BCG scar. Vital signs were within normal, with a clear chest on auscultation. The **chest X-ray** (Fig. 1) showed-diffuse micro nodular opacity in both lungs predominantly in the mid zone, bilateral pleural and fissure calcification, RUL paratracheal cystic changes with calcified walls, normal cardiac silhouette, no pleural effusion or pneumothorax. **CT scan chest** (Fig. 2 L &R) showed multi centerilobular nodules predominantly in the mid and lower zone bilaterally, areas of bullous emphysema in RUL lobe with calcified walls, Pleural and fissure calcification.

Her **PFT has** showed FEV1 80% predicted, FVC 76% predicted, ratio of FEV1/FVC was normal, overnight pulse oximeter was normal with nocturnal hypoxemia.

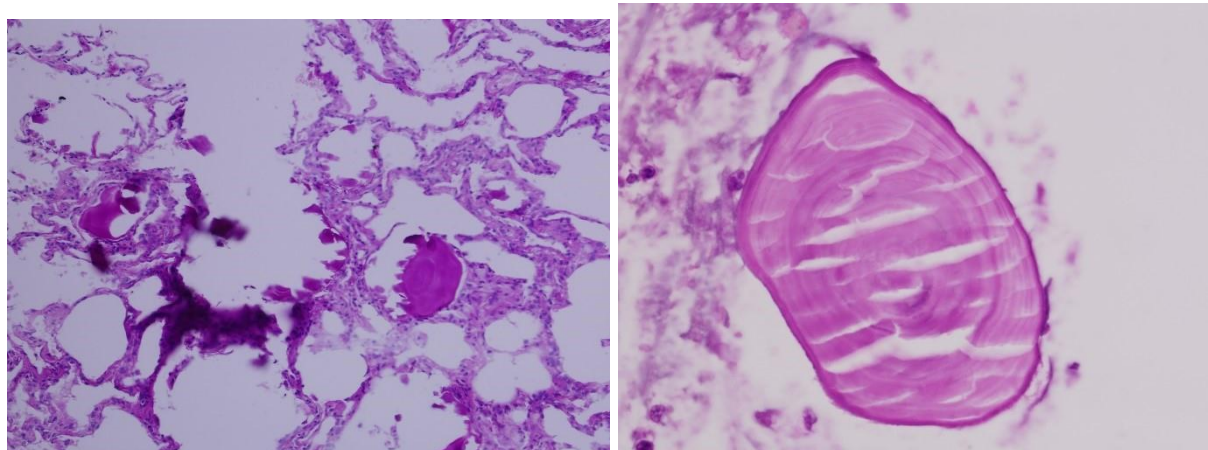
Diagnosis confirmed by opened right lung biopsy and **Broncho alveolar lavage, biopsy** showed numerous lamellar (Calculi) ( Fig. 3 ), no significant fibrosis, no eosinophilia or evidence of vasculities, no fungi, no acid fast bacilli (AFB), no hemosiderin laden macrophage, and no amyloidosis.



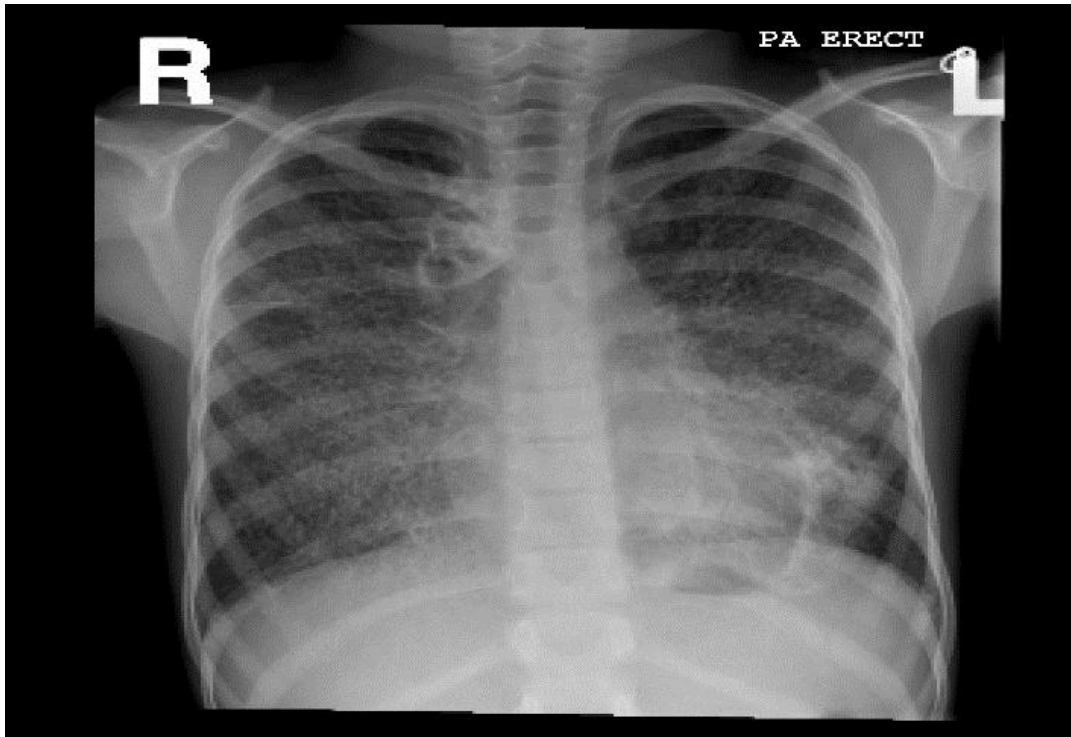
**Fig 1:** Chest X-ray: shows bilateral diffuse micro nodular opacity predominantly in the mid zone, central part, and bilateral pleural and fissure calcifications. RUL paratracheal cystic changes with calcified wall



**Fig 2:** CAT scan – Lung window a (left) & Mediastinal window B (right): displays multi centerilobular nodules predominantly in the mid and lower zone bilaterally. Areas of bullous emphysema in RUL lobe with calcified walls. Pleural and fissure calcification.



**Fig 3:** Lung biopsy shows numerous intra alveolar lamellar (Calculi).



**Fig 4:** CXR two year follow up, illustrates an evidence of increase nodularity changes in the right upper zone and an increase calcification in the left lower zone.

#### TIMELINE

Time	Complaint	Action
2012	Cough for a year	Reassured by local primary health care
2013	Cough	King Abdullah hospital in Bisha for 3/12 as? TB (Secondary hospital)
2013, November	Asymptomatic	Referred to KFMC ( Tertiary center in Riyadh) for diagnostic work up and confirmed to be PAM
2015, November	Asymptomatic	Decline in her PFT and minimal nocturnal hypoxemia
2018	On progress	Awaiting follow up

#### DISCUSSION

PAM is very rare condition first reported in the literature was on 1966 by Malpighi. <sup>(7)</sup>.

It is rare but similar in all continents, similar in both sexes and it is higher in second and third decade with a progressive decline course of the disease in most of the patient. Two cases reported at 2 years of age <sup>(4)</sup>. A neonatal case reported in premature twin who died in the first 24 hour of life (Caffrey et al) <sup>(8)</sup>. 1022 cases were reported by 2015, Turkey and China were the highest reported nations (by Giuseppe Castellana et al) <sup>(9, 10)</sup>. Although cases with microlithiasis described in all age but a nonspecific clinical, presentation made early detection and diagnosis of PAM a little bit difficult and misdiagnosed easily. The later lead the patient to be exposed to various prolonged therapy. Our patient misdiagnosed as military TB and started on anti tuberculous medications luckily,

no side effect reported but due to insignificant response measured by change in chest x-ray, they refer the case to us as a tertiary center in King Fahad Medical City (KFMC). Such medications could lead to serious side effects like liver injury, deafness, visual change or nephrotoxicity, keeping in mind how much stress could face both physicians and parents, as the diagnosis still obscured.

Following the patient for two years without treatment showed that the disease was slowly progressed. Follow up in 2 year time showed significant deterioration in **pulmonary function test** (moderate restrictive airflow limitation with FVC 63.9%, FEV1 64.2%, ration of FEV1 /FVC 93%, TLC was 67% predicted, with no reversibility to bronchodilator with no evidence of hyperinflation ratio of FRC/TLC was 2.6%). Further, a significant reduction in the 6-minute

walk test 63% predicted, the overnight pulse oximetry tests revealed minimal nocturnal hypoxemia with a mean of saturation 93% in room air. In follow up CXR (Fig 4), there was an evidence of increase nodularity changes in the periphery and upper zone. Unfortunately, the patient received no treatment due to unavailability of sodium diphosphonate. There was no extra pulmonary microliths.

The disease usually does not show good prognosis; no definitive treatment yet discovered with medical or gene therapy. Controversial results had been reported with sodium diphosphonate treatment as a calcium-chelating agent<sup>(11)</sup>, while steroids were proved ineffective as well as therapeutic BAL. The trial of therapeutic lavage in this case was ineffective with clear and absent of any microlith. Lung transplantation is required once end-stage lung disease is established. Many patients have received lung transplantation for this condition successfully<sup>(12)</sup>.

## CONCLUSION

Here we reported the first sporadic case of PAM in Saudi Arabia, which presented with nonspecific clinical picture, which resulted in misdiagnosis and consequently improper management. The case proves the slowly progression of the disease and lung transplant is the potential cure for such case. We hope to discover a new therapy that could cure or prevent the progression of the disease.

## ABBREVIATIONS

PAM – Pulmonary Alveolar Microlithiasis

BAL Broncho-alveolar lavage

TB: Tuberculosis

RUL: Right upper lobe

PFT: Pulmonary function test

FEV1: Forced expiratory volume in the first second

FVC: Forced vital capacity

TLC: Total lung capacity

AFB: Acid-fast bacilli

KFMC: King Fahad Medical City

L: LEFT

R: Right

## CONSENT

Written informed consent obtained from the patient's legal guardian(s) for publication of this case report and any accompanying images. A copy of the Written consent is available for review by the Editor-in-Chief of this journal."

In addition, our local ethics committee (IRB) of the King Fahad Medical City (KFMC) approved the manuscript.

## Competing interest

The authors declare that they have no competing interest.

**Availability of data and materials:** Data sharing not applicable to this article as no datasets were generated or analyzed during the current study.

## ACKNOWLEDGEMENTS

We would like to thanks American Journal Experts for editing the manuscript.

## REFERENCES

- Mariotta S, Ricci A, Papale M et al. (2004):** Pulmonary alveolar microlithiasis: report on 576 cases published in the literature. *Sarcoidosis Vasc Diffuse Lung Dis.*, 21(3):173-81.
- Giuseppe C, Giorgio C, Mattia G, Roberto C, Ontorio R (2015):** pulmonary alveolar microlithiasis: review of the 1022 cases reported worldwide, *European respiratory review*, 24:607-620.
- Lauta V (2003):** Pulmonary alveolar microlithiasis: an overview of clinical and pathological features together with possible therapies. *Resp Med.*, 97:1081–5.
- Mariani B, Montanini N, Torelli G (1947):** Microlithiasi polmonare endoalveolare diffusa. *Ann ist C Forlanini*, 10-179-83.
- Dogan OT, Ozsahin SL, Gul E, Arslan S et al. (2010):** A frame-shift mutation in the SLC34A2 gene in three patients with pulmonary alveolar microlithiasis in an inbred family. *Intern Med.*, 49(1):45-9.
- Castellana G, Lamorgese V (1998):** La microlitiasi alveolare polmonare: rivisitazione della casistica Italiana. *Rass Pat App Respir.*, 13 :405–407
- Malpighi M (1966):** Manoscritti vol XII foglio81; in Anzalone M (ed): Marcello Malpighi e i suoi scritti sugli organi del respiro. Bologna, Tamari, p259..
- Caffrey PR, Altman RS (1965):** Pulmonary alveolar microlithiasis occurring in premature twins. *J Pediatr.*, 66:758–763.
- Castellana G, Lamorgese V (2003):** Pulmonary Alveolar Microlithiasis: World Cases and Review of Literature. *Respiration*, 70:549-55.
- Giuseppe C, Giorgio C, Mattia G, Roberto C and Onofrio R (2015):** Pulmonary alveolar microlithiasis: review of 1022 cases reported worldwide, *Eur Respir Rev.*, 24:607-620
- Ozçelik U, Gülsün M, Göçmen A et al. (2002):** Treatment and follow-up of pulmonary alveolar microlithiasis with disodium editronate: radiological demonstration. *Pediatr Radiol.*, 32 (5):380-3.
- Marcos N, I Daniel R, II Mauro C et al. (2010) :** Lung Transplantation For Pulmonary Alveolar Microlithiasis. A case Report, *Clinic*, 65 (2): 233-6.