

Growing Skull Fractures after a Closed Head Injury, Early Detecting Signs, and Surgical Considerations

Ahmed M. Deabes*, Shawky El Meleigy, Mohamed E. Elhawary

Department of Neurosurgery, Benha University, Faculty of Medicine, Qalyubia, Egypt

Corresponding author: Ahmed M. Deabes, MD, Mobile: +20 1025001475,

email: ahmed.elsayed@fmed.bu.edu.eg

ABSTRACT

Background: When children younger than three years suffer a closed-head injury such as a fall or a blow to the head, a linear calvarial fracture may occur, leading to a growing skull fracture.

Methods: In this prospective study, we provide 10 instances to better illuminate the symptoms of GSF, facilitate earlier surgical correction, and prevent negative outcomes by the use of specific technical details.

Results: Early surgical correction was performed for all patients showing evidence of dural tear and GSF, such as a pulsating, non-resolving subgaleal collection despite medical treatment, a fracture diastasis, a leptomeningeal cyst on magnetic resonance imaging, or a herniated brain via a fissure. After a skin incision was made including the fissure, a bone flap was created using electric craniotomy from the fracture's edge to minimize bony defects without the use of a burr hole. Next, the dura was dissected away from the fracture's edges, and finally, the underlying arachnoid adhesions and devitalized brain tissues were addressed before the dural closure was made. Results were better and complications such as increased intracranial pressure, prolonged CSF leak after surgery, meningitis, and skull abnormalities were avoided with early surgery.

Conclusions: Patients with linear skull fractures following closed head injuries require close monitoring and follow-up. Knowing the warning signals of GSF is important for parents. In the presence of symptoms and radiographic evidence of a dural rupture, early surgical repair is required to avoid neurological impairment, seizures, and elevated intracranial pressure.

Keywords: Growing skull fracture, Leptomeningeal cyst, dural tear encephalomalacia

INTRODUCTION

The skull fracture was first reported by John Howship in the 18th century (GSF). Following severe skull fractures, children younger than 3 years are more prone to acquire GSF (1, 2, 3). Between 0.05% and 1.6% of the population may develop GSF. Parietal quadrants are the typical sites of occurrence. Pulsatile swelling is the most prevalent presenting sign, followed by seizures and neurological abnormalities. Avoiding irreversible brain damage from GSF requires an early diagnosis and rapid surgical intervention. It may take anything from a few days to a few years to determine whether or not a head injury has caused permanent damage (4, 5, 6). It is recommended that GSF be diagnosed by plain radiography or CT. Magnetic resonance imaging (MRI) is used to identify CSF leaking, brain tissue injury, and herniation (7,8). The pathogenesis of GSF has not been fully elucidated in the literature (9, 10, 11). Because baby skulls are more malleable than adult skulls, inward displacement is a common

complication of skull fractures in children. The brain may be readily lacerated by a depressed or temporarily depressed fracture (12, 13). Oedematous cortical tissue and the pia-arachnoid membrane might impede recovery. An expanding leptomeningeal cyst pushes through a dural gap into the subgaleal space as cerebrospinal fluid pulses enlarge the subarachnoid pouch that extends through the fracture edge. It's worth noting that CSF pulsations have a greater tendency to degrade the inner table than the outer table (14, 15, 16).

PATIENTS AND METHODS

Between March 2018 and August 2021, all patients at Benha University Hospitals who had surgery for a developing skull fracture were included in a prospective study. Our IRB has given their approval to this work. All patient's parents provided written informed permission. A fissure that developed following a head injury that was kept from the outside was considered. Open wounds to the skull,

depressed fractures, and pathology necessitating surgical intervention were all things to look out for.

From the time of admission, all patients underwent a routine radiological and clinical assessment to ensure an early diagnosis and inform the decision to operate. All surgical procedures were detailed in technical detail for optimal repair and to prevent complications.

Ethical approval:

Detailed informed consent about the study was obtained from every parent. Approval was obtained from Benha University Institutional Review Board. The Declaration of Helsinki, the code of ethics of the World Medical Association, was followed when conducting this research on humans.

Illustrative case:

Our emergency room took in a baby girl, aged only 4 months. She suffered a closed head injury with a subgaleal hematoma in the right parietal area. A CT scan revealed a fracture line in the parietal bone, with underlying brain contusions (**Fig 1**).

The results of the neurologic examination were unremarkable. CT scans of the brain performed 2 and 7 days later (**Figs. 2, 3, 4**) revealed the following: (1) an enlarged subgaleal collection, (2) a subdural hygroma with disruption of CSF circulation, (3) a contused brain pointing toward the fracture line, and (4) an enlarged fracture diameter with an erosion of the fracture line. Subgaleal collection of the same density as CSF, dural tear, and membranes created in subarachnoid space were additional observations from the

MRI of the brain (**Fig 5**). Exams taken afterward revealed a pulsating mass in the area of the parietal bones. Her family's signed informed permission was obtained before the operation was done.

Some technical details were observed during the operation, such as 1- A wide scalp incision that included a leptomenigeal cyst and a linear fissure in the middle, a subgaleal dissection, and the preservation of the cyst. 2- Leptomenigeal cyst and fissure, the cyst is carefully excised at a slow pace to protect any nearby cortical arteries.

3-In order to minimize bone loss during electric craniotomy, it is best to start at the perimeter of the fissure after dissecting the dura from bony edges and to create a linear fissure in the middle of the flap. 4-Careful excision of adhesion and gliotic tissues was used to treat the injured brain, arachnoid adhesions, and gliotic brain, and then the resulting raw surfaces were covered with surgical or fibrillar to reduce arachnoidal adhesions and aid normal CSF pathway. If the gliotic brain extended beyond the dural defect, the dura should have been incised at the edge of the dural defect to explore all gliotic brain tissues.

5-Covering the dural defect with pericranium is ideal (autologous material). Since no bone regeneration will take place over the dural graft, it is essential that the grafted region be fully covered, either with autologous pericranium or a foreign substance. Patients with bony deformities may have their normal dura used to create new bone. All steps were explained in detail in (**Fig 6**).

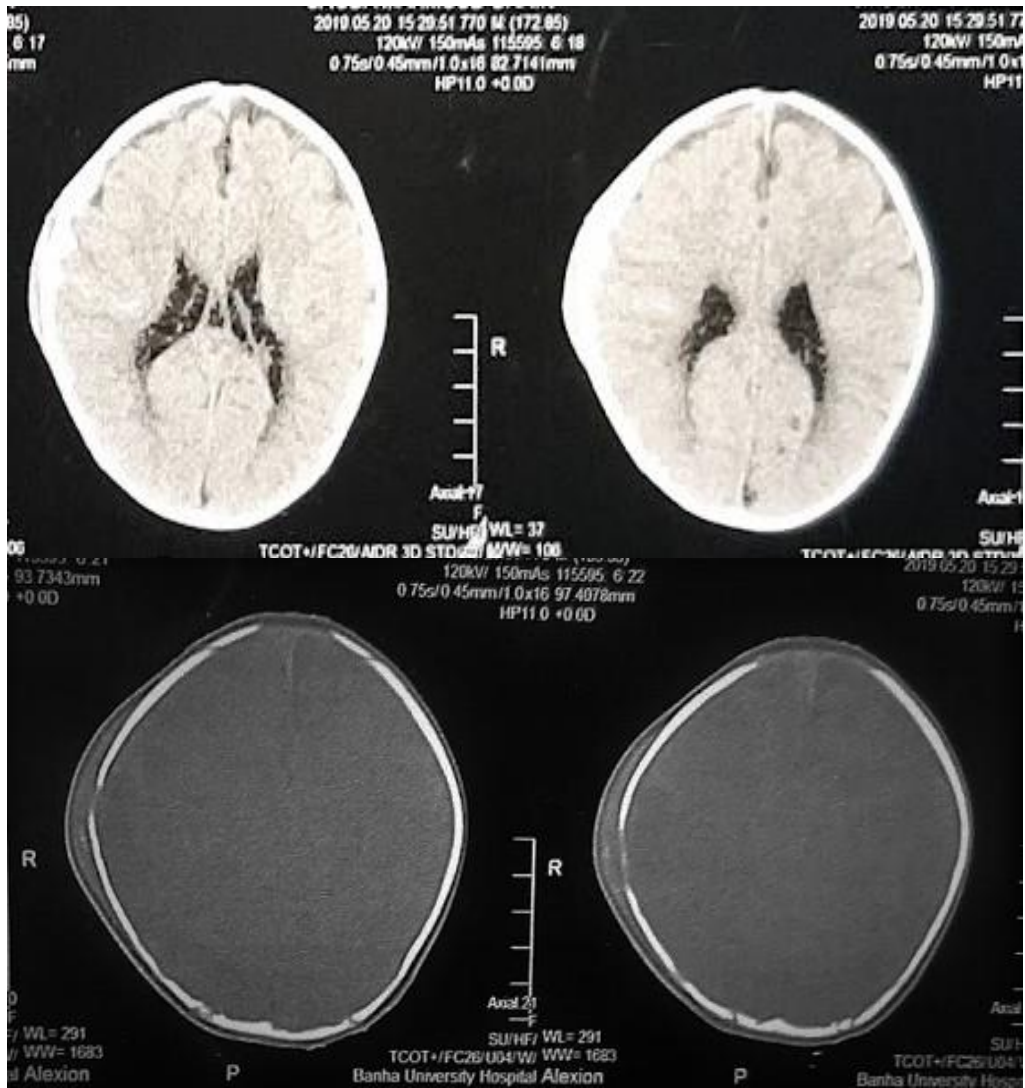


Fig (1): Initial CT brain had shown RT parietal fracture, subgaleal hematoma, and starting brain contusion.

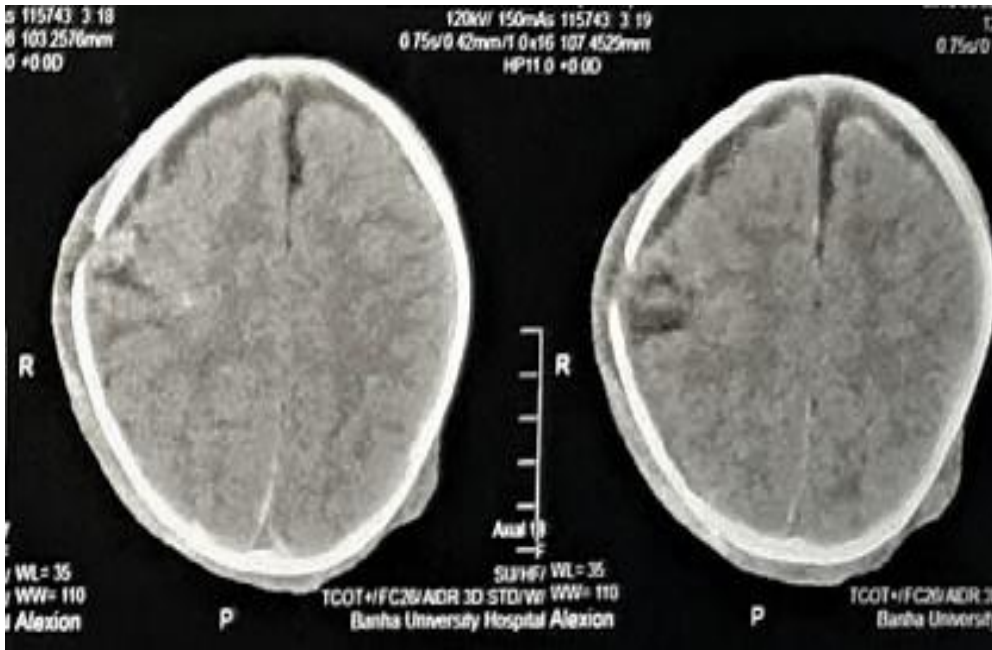

Fig (2): Follow-up CT brain after 2 days had shown brain contusion with CSF collection in front of fracture in the ipsilateral side.

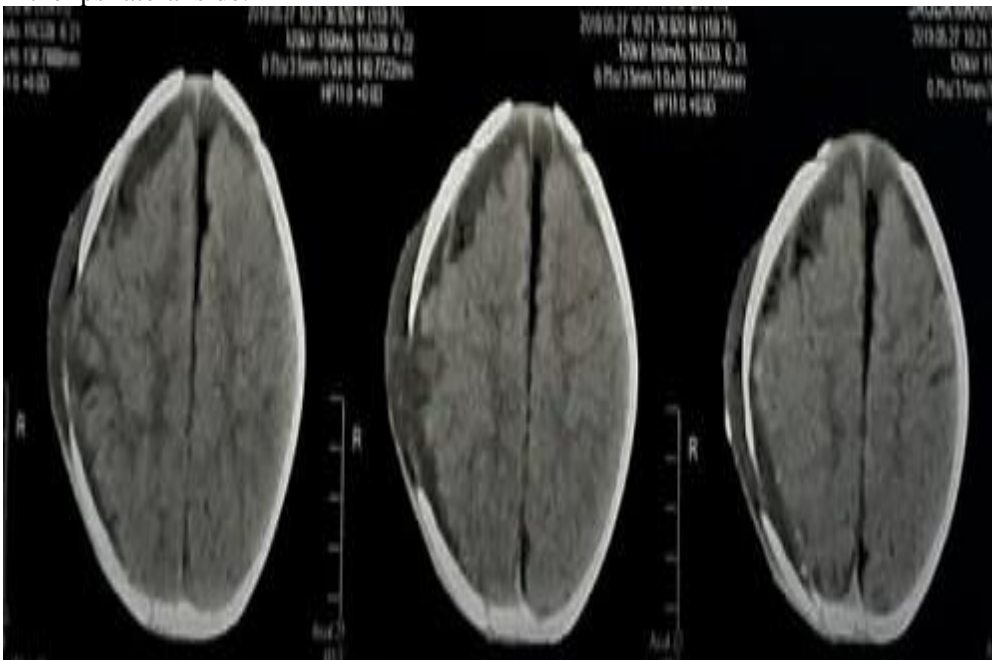


Fig (3): Follow-up CT brain after 4 days, had shown increased CSF accumulation in front of and behind the fracture in the ipsilateral side, with the contused brain heading to the fracture line.

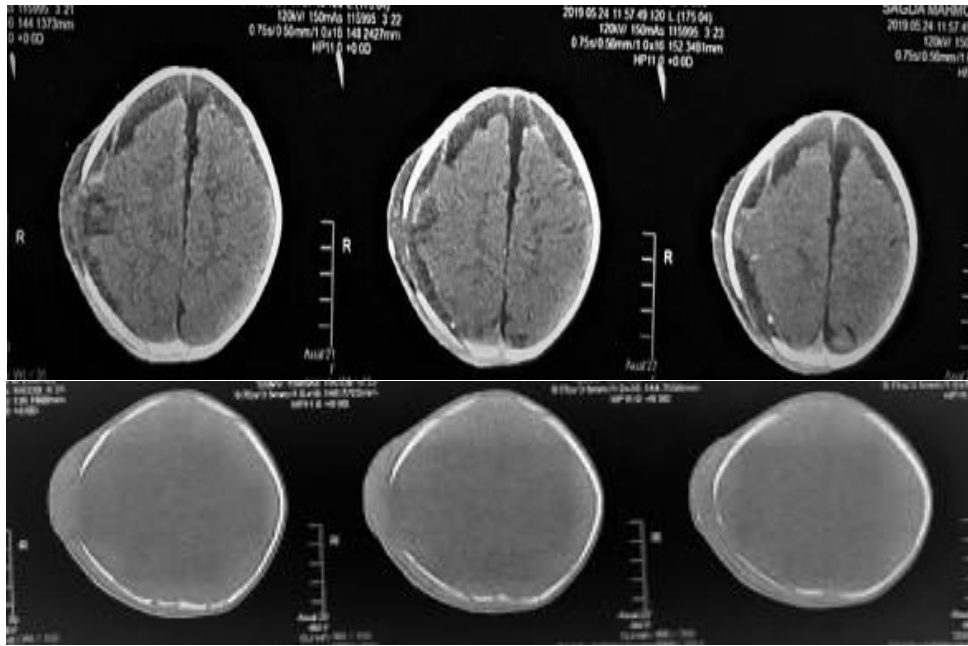


Fig (4): Follow-up CT brain after 7 days, had shown increased CSF accumulation in front of and behind the fracture in the ipsilateral side and contralateral side, with the increased diameter of the fracture line.

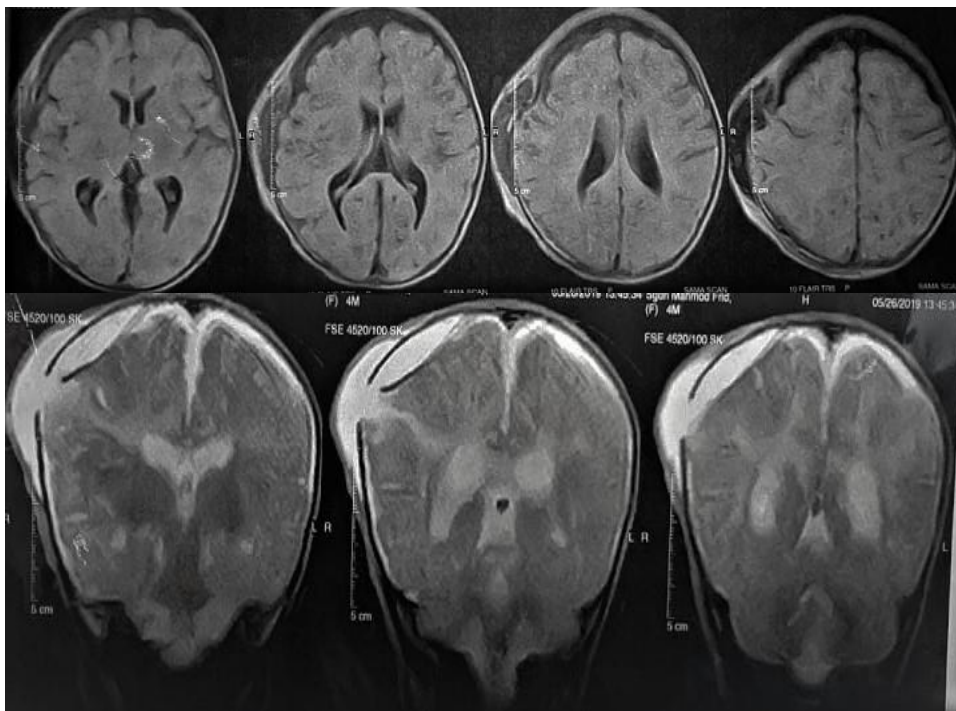
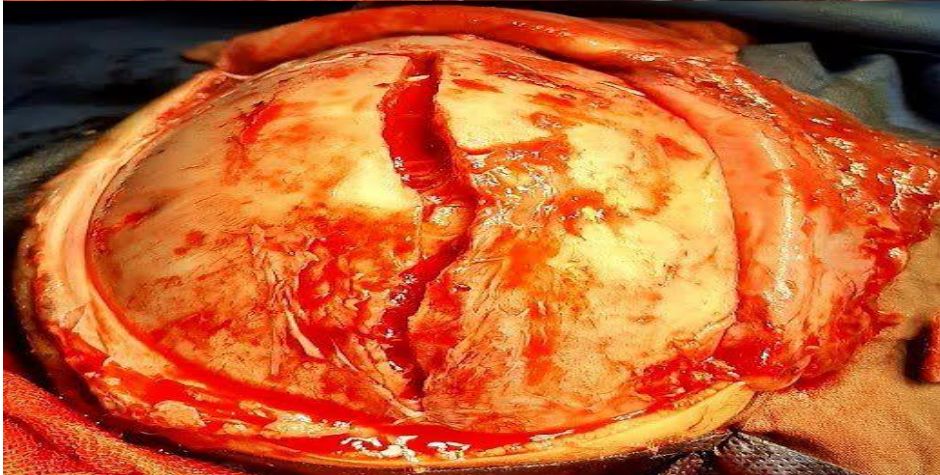
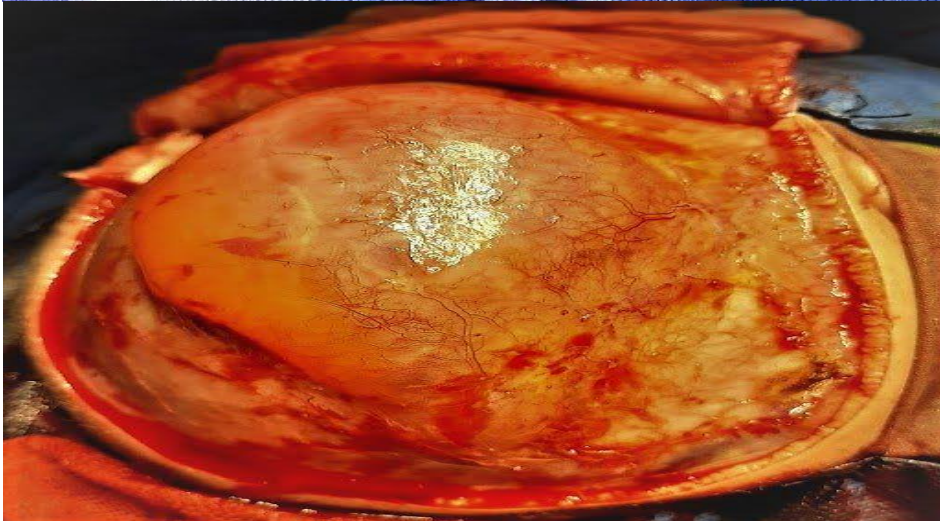
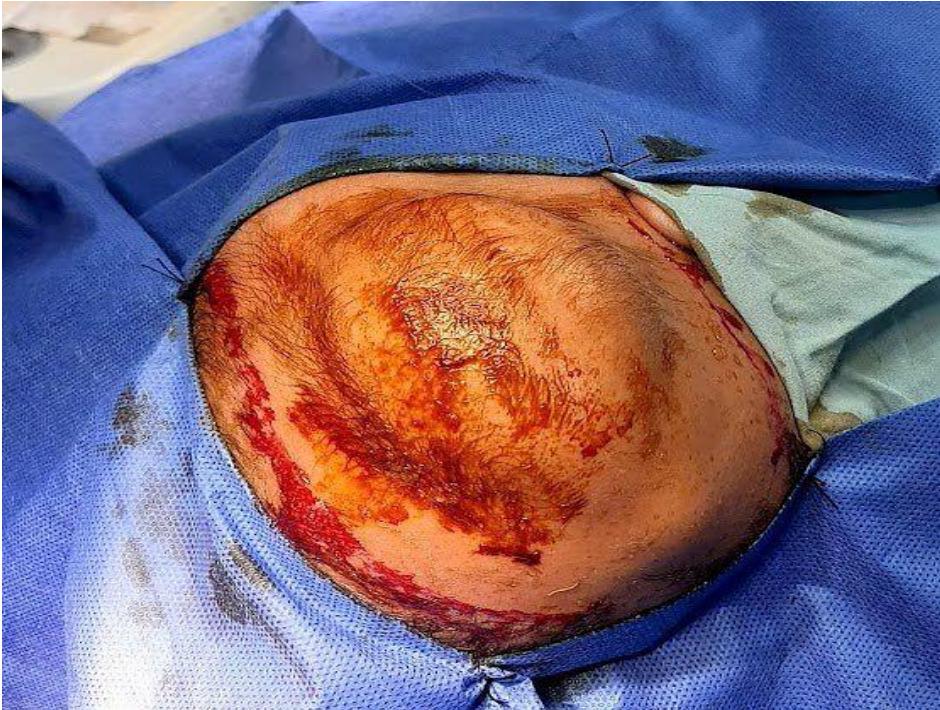Fig (5): Follow-up MRI brain after 6 days, had shown subgaleal hematoma with the same density of CSF, with formed membranes in the subdural space of the contused brain.



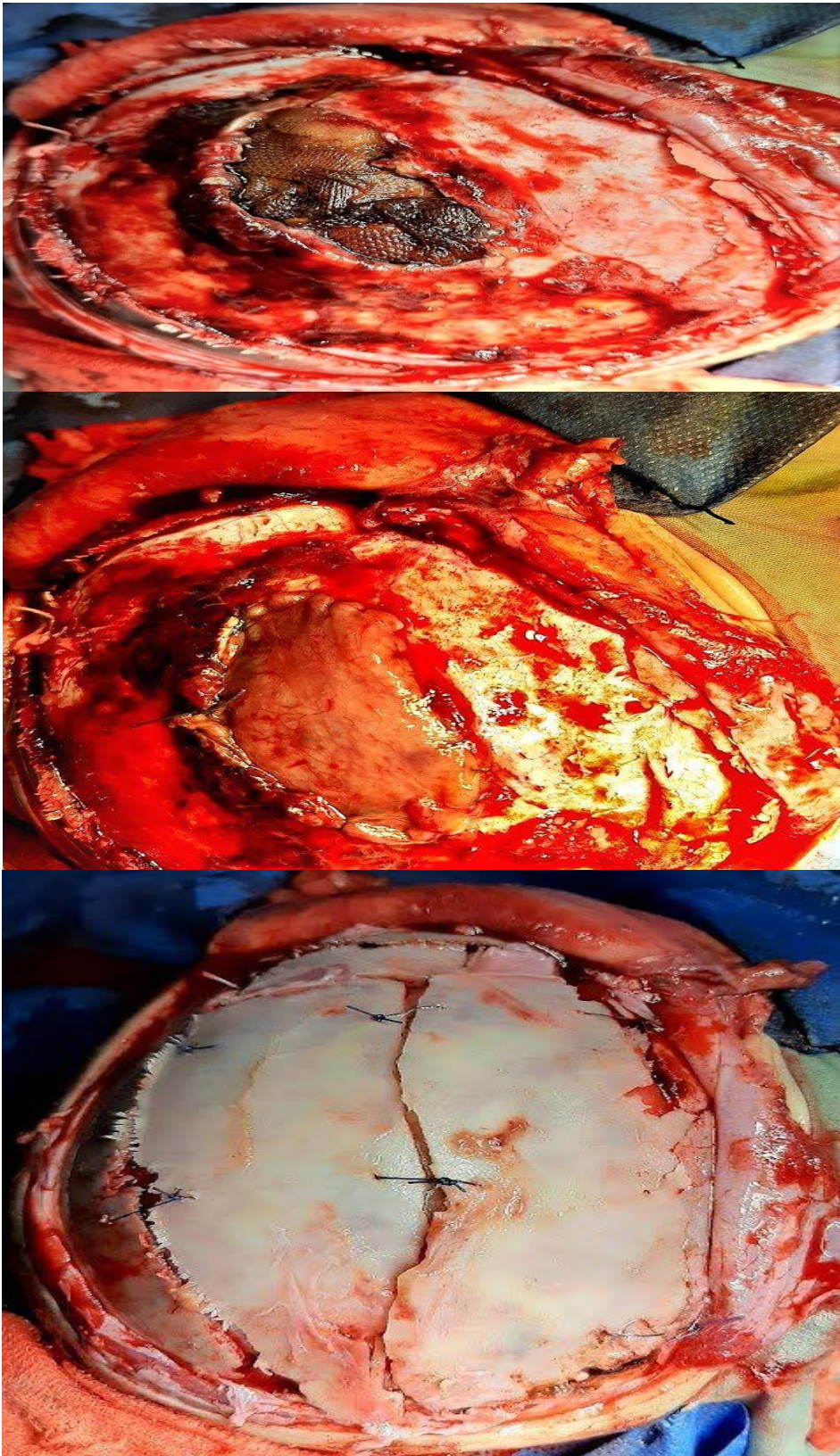


Fig (6) Surgical steps starting from skin incision, exploration of the leptomenigeal cyst, fissure identification and bone flab, dural defect, repair of defect with pericranium, bone flaps is repositioned with completely cover the graft and dura and if there is bony defect should be on the periphery.

DISCUSSION

Leptomeningeal cyst, cephalohydrocele, traumatic ventricular cyst, expanding fracture of the skull, traumatic meningocele, traumatic malacia, fibrosing osteitis, posttraumatic bone absorption, chronic posttraumatic erosion, craniocerebral erosion, leptomeningeal cyst, and traumatic ventricular cyst are all examples of conditions that can result from trauma. Some of the names for this ailment include Schadel fracture and developing fracture of the skull (17, 18).

Traumatic skull fractures in children under the age of three years are unusual but potentially life-threatening consequences of juvenile head trauma. Falls are the leading cause of injury, followed by automobile accidents and injuries sustained during delivery (18, 19).

The first step in detecting and treating GSF is to have an understanding of its etiology. According to Taveras and Ransohoff, a dural rip is the critical underlying element in the pathophysiology of craniocerebral erosion. With arachnoidal adhesions and regular brain pulsations, a ball-valve mechanism might widen the defect (20, 21). In 1987, Roy et al. found active degeneration and necrosis in the brain's deep regions and around the defect's periphery. Since the brain at the fracture site would not be protected by the dura and leptomeninges, they anticipated that the brain would come into direct touch with the bone fragments. This results in repetitive brain damage and gradual necrosis when the pulsing brain strikes the bone surface. Damage to the brain over time might also be the result of a disruption in blood flow to the organ (22, 23).

Complications might be lessened and the prognosis improved if the disease is diagnosed and treated quickly. Although the first brain parenchyma damage is permanent, it is nevertheless important to minimize further complications (15, 19, 20, 22).

In this research, we highlight the value of a prompt diagnosis. There are other symptoms and indicators to look out for besides suture diastasis, which is why it is not the most concerning. These symptoms and signs are indicative of a dural tear, which in turn increases the risk of more issues down the line. If you want to get the best cosmetic results or

prevent many of the issues that might arise from postponing surgery, getting it done sooner rather than later is your best chance. If you want to get the most out of your operation, it's best to follow these guidelines.

It is essential to examine the scalp for signs of GSF because a persistent subgaleal collection that does not resolve with time and may be enhanced, CSF pulsations, indicating a dural tear with transmitted pulsations, which may be exacerbated by the Valsalva maneuver or a change in body posture. In most cases, the bony edges are scalloped and sclerotic, but in others, you may see an increase in vascularity in zones. Because of the outward pressure exerted by the cyst, the bone erodes mostly in the center, affecting the inner table to a greater extent than the outer one (24, 25).

Leptomeningeal cysts, subgaleal collections with the same CSF density, and gliotic brain tissues that pass through dural defects and fissures are radiological findings of essential importance for the early identification of dural rips. When the bony borders of the fissure become scalloped and eroded, it is an indication of a dural defect characterized by recurrent CSF pulsations.

The value of educating parents cannot be understated. Educating parents about GSF and getting them to keep a lookout for neurologic symptoms including new or worsening tingling, numbness, or weakness is crucial.

CONCLUSIONS

Successful outcomes and the avoidance of subsequent sequelae connected to fissures may result from early identification and care of GSF. Early identification of dural rips requires careful and routine examination of the scalp in addition to radiographic findings. Even in the absence of fissure diastasis, the authors of this research advise early surgery for all infants diagnosed with linear fissure and an obvious dural rupture (clinically and radiologically) to improve clinical and aesthetic outcomes and prevent late problems. The technical aspects of the operation are broken down to provide the best possible result.

Conflict of interest: The authors declare no conflict of interest.

Sources of funding: This research did not receive any specific grant from funding agencies in the public, commercial, or not-for-profit sectors.

Author contribution: Authors contributed equally to the study.

REFERENCES

1. **Granata T, Freri E, Caccia T et al. (2005):** Schizencephaly: clinical spectrum, epilepsy, and pathogenesis. *J Child Neurol.*, 20(4): 313-318.
2. **Baldawa S (2016):** Remote intracranial hemorrhage following surgery for giant orbitofrontal growing skull fracture: A lesson learned. *J Pediatr Neurosci.*, 11:118-20.
3. **Singh I, Rohilla S, Siddiqui S et al. (2016):** Growing skull fractures: guidelines for early diagnosis and surgical management. *Childs Nerv Syst.*, 32:1117-22.
4. **Taveras J, Ransohoff J (1953):** Leptomeningeal cysts of the brain following trauma with erosion of the skull. A study of the seven cases treated by surgery. *J Neurosurg.*, 10:233-41.
5. **De Djientcheu V, Njamnshi A, Ongolo-Zogo P et al. (2006):** Growing skull fractures. *Childs Nerv Syst.*, 22:721-5.
6. **Abuzayed B, Tuzgen S, Canbaz B et al. (2009):** Reconstruction of growing skull fracture with in situ galeal graft duraplasty and porous polyethylene sheet. *J Craniofac Surg.*, 20:1245-49.
7. **Diyora B, Nayak N, Kamble H et al. (2011):** Surgical treatment and results in growing skull fracture. *Neurol India*, 59:424-28.
8. **Drapkin A (2006):** Growing skull fracture: a posttraumatic neo suture. *Childs Nerv Syst.*, 22(4): 394-97.
9. **Ersahin Y, Gülmen V, Palali I et al. (2000):** Growing skull fractures (craniocerebral erosion). *Neurosurg Rev.*, 23:139-44.
10. **Gruber F (1969):** Post-traumatic leptomeningeal cysts. *Am J Radiol.*, 105:305-7.
11. **Howship J (1816):** Practical observations in surgery and morbid anatomy. London, England: Longman.
12. **Husson B, Pariente D, Tammam S et al. (1996):** The value of MRI in the early diagnosis of growing skull fracture. *Pediatr Radiol.*, 26(10): 744- 47.
13. **Kingsley D, Till K, Hoare R (1978):** Growing fractures of the skull. *J Neurol Neurosurg Psychiatry*, 41:312-18.
14. **Reddy D (2013):** Growing skull fractures, guidelines for early diagnosis and effective operative management. *Neurol India*, 61:455-56.
15. **Liu X, You C, Lu M et al. (2012):** Growing skull fracture stages and treatment strategy. *J Neurosurg Pediatr.*, 9:670-75.
16. **Mierez R, Guillen A, Brell M et al. (2003):** Growing skull fracture in childhood. Presentation of 12 cases (in Spanish). *Neurocirugia (Astur)*, 14(3): 228- 233
17. **Ellis T, Vezina L, Donahue D (2000):** Acute identification of cranial burst fracture: comparison between CT and MR imaging findings. *AJNR Am J Neuroradiol.*, 21:795-801.
18. **Muhonen M, Piper J, Menezes A (1995):** Pathogenesis and treatment of growing skull fractures. *Surg Neurol.*, 43(4): 367-72.
19. **Wang X, Li G, Li Q et al. (2013):** You C. Early diagnosis and treatment of growing skull fracture. *Neurol India*, 61:497-500.
20. **Pia H, Tonnis W (1953):** Die Washsende Schadel fractur des Kinden salters. *Zentralbl Neurochir.*, 13:1-23.
21. **Prasad G, Gupta D, Mahapatra A et al. (2015):** Surgical results of growing skull fractures in children: a single-center study of 43 cases. *Childs Nerv Syst.*, 31:269-77.
22. **Robert O, Pitmann T (2011):** Youman's Neurological Surgery. 6th ed. Philadelphia: Elsevier.
23. **Zegers B, Jira P, Willemsen M et al. (2003):** The growing skull fracture is a rare complication of pediatric head injury. *Eur J Pediatr.*, 162:556-57.
24. **Roy S, Sarkar C, Tandon P et al. (1978):** Craniocerebral erosion (growing fracture of the skull in children) Part I. Pathology. *Acta Neurochir.*, 87:112-18.
25. **Simon B, Letourneau P, Vitorino E et al. (2001):** Pediatric minor head trauma: indications for computed tomographic scanning revisited. *J Trauma*, 51:231-7.