

# Evaluation of Connecting a Fourth Ventricular Catheter with Y Connector to a Previous Ventriculoperitoneal Shunt, as a Treatment Option for Patients with Symptomatic Trapped Fourth Ventricle

Mohammed Hammad Eltantawy\*, Shawky A. Elmeleigy, Ahmad Arab  
Department of Neurosurgery, Faculty of Medicine, Benha University, Egypt

\*Corresponding author: Mohammed H. Eltantawy, Mobile: (+20)01000221379, Email: hammad\_neurosurg@yahoo.com

## ABSTRACT

**Background:** Trapped fourth ventricle (TFV) is a rare clinico-pathological syndrome, usually resulting from inflammatory conditions (post-infective and post-hemorrhagic) that may present with serious brain stem compression manifestations. Many treatment modalities have been described with varying degrees of success.

**Objectives:** To evaluate our results in managing the trapped 4<sup>th</sup> ventricle by inserting 4<sup>th</sup> ventricular catheter and connecting it to the previously implanted ventriculoperitoneal (VP) shunt via Y connector.

**Patients and Methods:** A total number of 12 cases with TFV were diagnosed and treated surgically between 2014 and 2021 by a fourth ventricular catheter and connection to the pre-existing shunt via a Y-connector. Preoperative clinical and radiological findings were reported. Postoperative improvement was evaluated during a mean follow-up of 4.3 years. Postoperative complications were reported

**Results:** 12 patients (6 males and 6 females), with a mean age of 3.3 years diagnosed with trapped fourth ventricles were included. All patients had previous VP shunts. Headache, vomiting, abnormal movement, gait disturbance, and nystagmus were the common symptoms. Trapped fourth ventricle was post-infectious in 6 (50%) patients, post-hemorrhagic in 4 (33.3%) patients, and congenital in 2 (16.7%) patients. 6 (50%) patients had preoperative slit lateral ventricles and 4 (33.3%) had multiloculated hydrocephalus. Postoperatively 10 (83.3%) patients had clinical improvement while 2 (16.7%) remained as preoperative. All patients had a decrease in the 4<sup>th</sup> ventricular size. Complications of surgery were minor.

**Conclusion:** Fourth ventricular shunting with a Y connector is a valuable and effective modality of treatment in TFV, especially when other methods fail or in specific complex pathological situations, with fewer complications.

**Keywords:** Trapped fourth ventricle, Y-connector, Fourth ventricular shunt.

## INTRODUCTION

Trapped fourth ventricle (TFV) is an uncommon clinico-pathological syndrome that occurs when the fourth ventricle loses its proximal communication to the third ventricle through the cerebral aqueduct of sylvius and loses its distal outlet drainage to foramina of Magendie and Luschka, with the continuation of CSF production by the choroid plexus from the wall of the fourth ventricle; leading to progressive dilation of such closed space<sup>(1)</sup>.

Trapped 4<sup>th</sup> ventricle usually occurs as a sequela of intraventricular hemorrhage or infection and less commonly with congenital conditions like Dandy-Walker malformation or neoplastic like carcinomatous meningitis. In most cases, it occurs after a variable period from supratentorial shunting<sup>(2)</sup>.

The clinical presentations of trapped fourth ventricle may range from mild nonspecific symptoms such as headache, nausea, and vomiting up to cerebellar or brainstem symptoms; ataxia, diplopia, lethargy, nystagmus or cranial nerve neuropathies and deficits. The cerebellar and brain stem compression due to the mass effect of the progressively dilated fourth ventricle is responsible for these clinical conditions. Although some patients may be detected incidentally<sup>(3)</sup>.

Multiple treatment options were suggested for the management of the trapped fourth ventricle, with variable success rates and with superiority to endoscopic procedures. Treatment modalities include CSF diversionary procedures, direct microsurgical

approach to the fourth ventricle by ventriculocisternostomy with excision of the arachnoid villi and endoscopic approaches for aqueductoplasty, aqueductal stenting (anterograde or retrograde), and cysto-ventricular fenestration. Literature till now is still lacking a standard consensus for the treatment of such condition favoring one treatment modality over the other, probably due to the wide diversity of etiologies and pathological pictures this condition may have. The only agreement between authors is to follow conservatively the asymptomatic cases with no progression of the fourth ventricular size. The selection of the treatment plan must be guided by a case-specific understanding of anatomic, radiographic, and pathophysiologic factors<sup>(4)</sup>. However, shunting of the fourth ventricle has been considered by many authors as the less invasive and the mainstay method of treatment<sup>(5)</sup>.

In this study, we tried to evaluate our results in managing trapped 4<sup>th</sup> ventricle, due to different etiologies, by adding a fourth ventricular catheter and connecting it to the previously placed supratentorial ventricular shunt with a Y connector.

## PATIENTS AND METHODS

A total number of 12 patients [six females, six males] were diagnosed as symptomatic trapped fourth ventricles due to variable etiologies with an average age at the time of surgery ranging from six months to five years (mean 3.3 years).

All patients had been treated by a 4<sup>th</sup> ventricular catheter connected to a previous supra tentorial V-P shunt via Y connector between 2014 - 2021 at the Neurosurgery Department of Banha University Hospital and Banha Children's Hospital.

Presenting clinical picture, MRI images, cause of the primary shunt insertion, and type of valve used have been evaluated and recorded. Postoperative radiological and clinical improvement were evaluated during an average follow-up period of 1.5 years to seven years (mean 4.3 years) and postoperative complications were reported.

Clinically asymptomatic trapped 4<sup>th</sup> ventricle patients with a radiologically stable size of the 4<sup>th</sup> ventricle were excluded from this study.

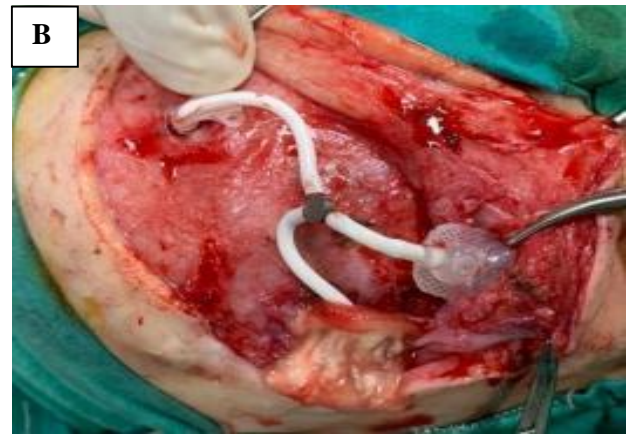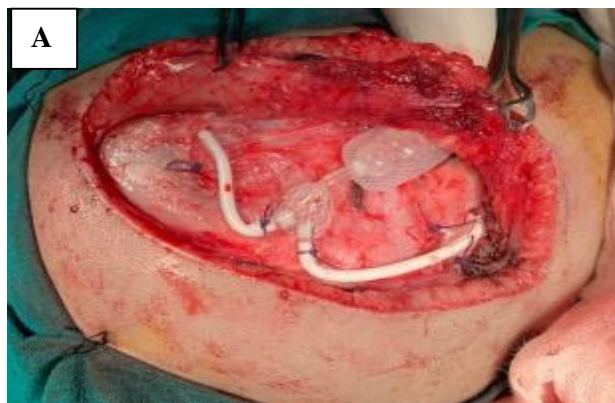Surgery was done only for patients with clinically symptomatic 4<sup>th</sup> ventricular entrapment or progressively increase in the size of the fourth ventricle with marked compression on the brain stem, even if no strong evidence of symptomatic trapped 4<sup>th</sup> ventricle could be elicited.

The success of the surgery was determined by the improvement of preoperative brainstem compression symptoms together with a reduction in the size of the 4<sup>th</sup> ventricle.

**Surgical technique:**

We used this technique with only the contoured type of V-P shunts, because of the proximal and distal ends that it has. Surgery was done by extending the previously made vertical limb of the incision then dissection proceeded till we expose part of the lateral suboccipital bone. A small burr hole was then made over the posterior fossa through which the new ventricular catheter was introduced inside the 4<sup>th</sup> ventricle and then connected to one of the upper limbs of the Y connector Fig. [1].

The supratentorial ventricular catheter was then disconnected from the contoured reservoir and reconnected to the other upper limb of the Y connector. The last step was to connect the lower limb of the Y connector to the upper end of the countered valve, which is then connected to the abdominal tube Fig. [1]. Non-absorbable silk suture was used to secure all the connections in place.



**Fig. (1):** Different types of Y connector connecting the lateral and 4<sup>th</sup> ventricular catheters to contoured valve. **A)** Silicone Y connector type of Medtronic. **B)** Titanium Y connector of Integra.

**Ethical consent:**

This study was ethically approved by the Institutional Review Board of the Faculty of Medicine, Benha University. Written informed consent was taken from the caregivers of all participants. The study was conducted according to the Declaration of Helsinki.

**Statistical analysis:**

The collected data were coded, processed and analyzed using the SPSS (Statistical Package for Social Sciences) version 24 for Windows® (IBM SPSS Inc, Chicago, IL, USA). Quantitative data were presented as means and qualitative data were presented as frequency and percentage.

**RESULTS**

All patients had previous supratentorial V-P shunts, with contoured valves placed at keen's point, due to various etiologies as in table [1].

Five patients had multiple shunt revisions together with endoscopic fenestrations [four post-infective and one post-hemorrhagic] due to shunt failure. Three patients were preterm [post hemorrhagic in all three], while the other nine patients were full-term. The time between the initial surgery and the appearance of symptoms of 4<sup>th</sup> ventricular entrapment ranged from two months to three years [mean 2.1 years]. Average follow-up ranged from six months to five years [mean 3.3 years].

**Table (1):** Initial cause of hydrocephalus

The initial cause of hydrocephalus	Number of patients (%)
Posthemorrhagic	4/ 12 (33.3%)
Post-infectious	6/ 12 (50%)
Congenital Dandy-Walker malformation	2/12 (16.7%)

11 patients were clinically symptomatic with MRI brain evidence of trapped 4<sup>th</sup> ventricle, while only one patient had a progressive increase in fourth ventricular size with brainstem distortion without obvious clinical symptoms.

Symptoms of trapped 4<sup>th</sup> ventricle are shown in table (2) The most common symptoms were headache and repeated vomiting, and cerebellar ataxia with gait disturbance.

**Table (2):** Preoperative symptoms of trapped 4<sup>th</sup> ventricle

Symptoms	Number of patients (%)
Headache and repeated vomiting	4/12 (33.3%)
Cerebellar ataxia with gait disturbance	5/12 (41.7%)
Seizures and abnormal movements	2/12 (16.7%)
Nystagmus	3/12 (25%)
6 nerve palsy	1/12 (8.3%)
Increased spasticity	1/12 (8.3%)
Refusal of feeding	2/12 (16.7%)
Clinically asymptomatic	1/12 (8.3%)

Preoperative radiological picture in all 12 patients was dilated 4<sup>th</sup> ventricle with compression and distortion of the brain stem. Summary of preoperative radiological picture is written in table (3).

In 10/ 12 patients we used the Medtronic silicon Y connector Fig. [1A], while in the other two patients we used Integra titanium metal connector Fig. [1B].

**Table (3):** Preoperative radiological picture

MRI findings	Number of patients (%)
Dilated fourth ventricle with compression of the brain stem (TFV)	12/ 12 (100%)
Slit lateral ventricle Fig[2]	6/ 12 (50%)
Multiloculated supratentorial ventriculomegaly Fig[3]	4/ 12 (33.3%)
Normal size ventricle with adequate shunting	2/ 12 (16.7%)

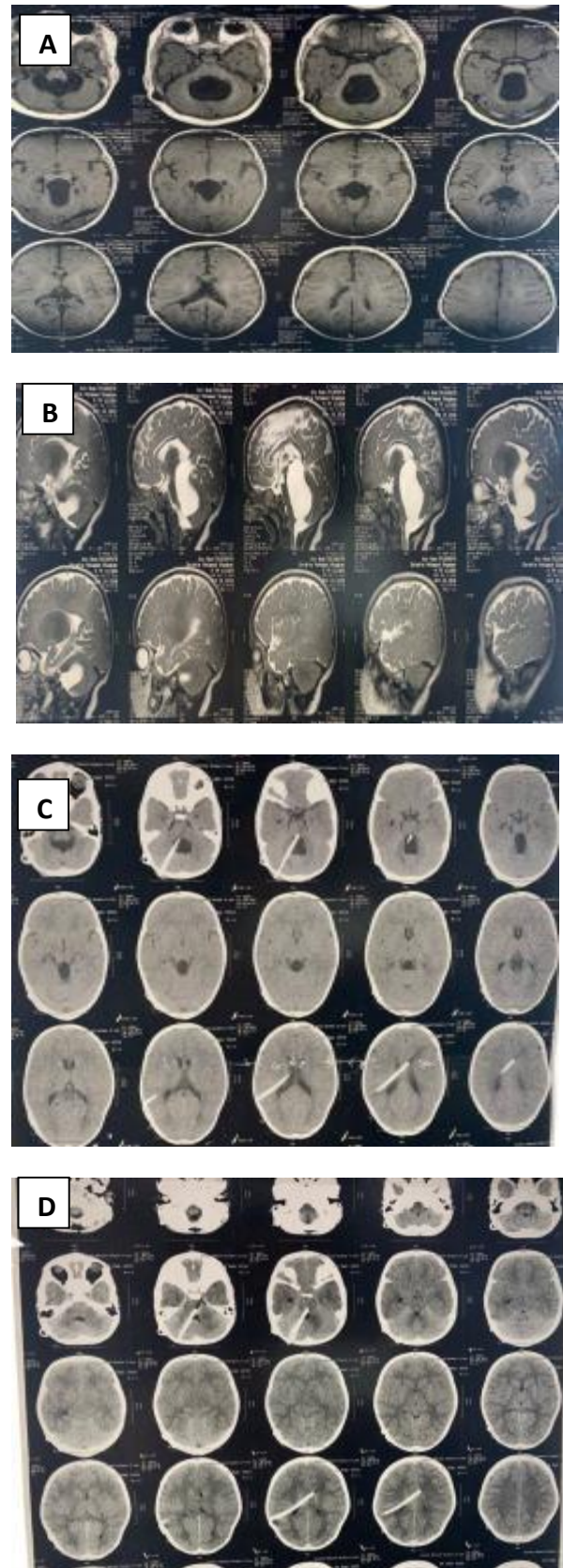
**Clinical outcome:**

10/12 (83.3%) patients showed improvement in their preoperative symptoms after surgery within a range of [2 days to 60 days]; mean of 24.6 days. 2/12 (16.7%) patients had the same gait as preoperative during the follow-up, although their headache improved. These two patients had preoperative cerebral palsy with multiloculated hydrocephalus and repeated shunt revisions.

**Radiological outcome:**

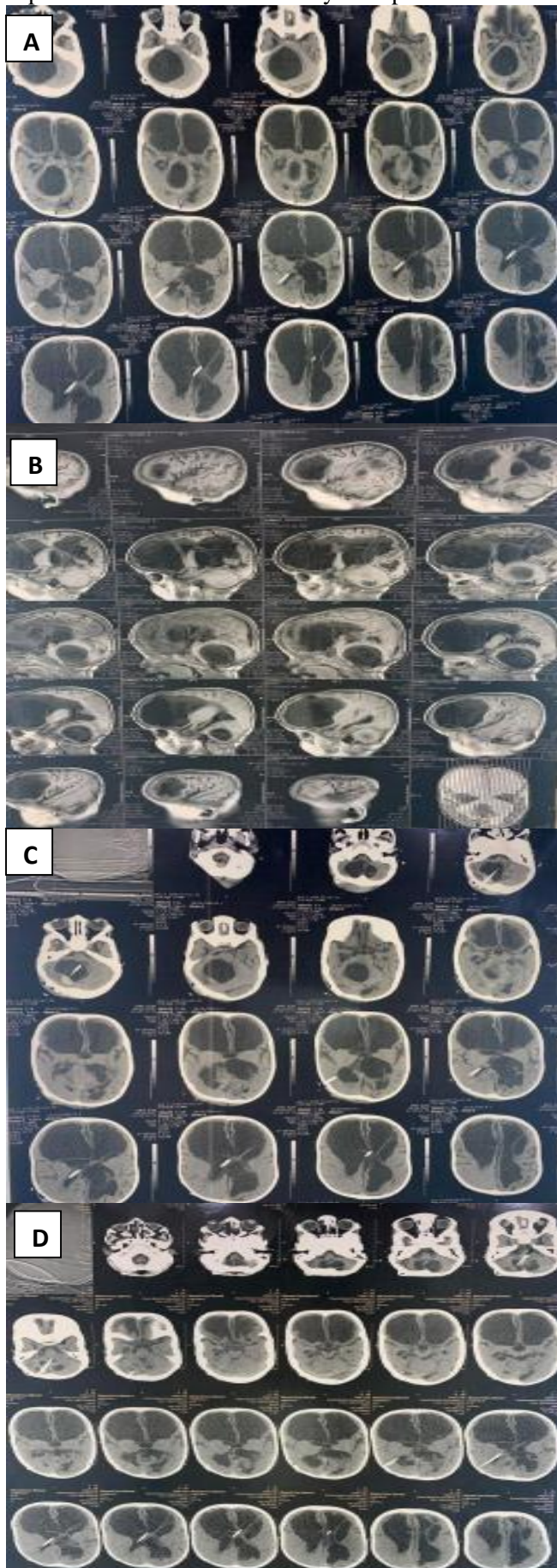
In all patients, postoperative MRI showed variable degrees of reduction in the size of the 4<sup>th</sup> ventricle with subsidence of brain stem compression. In two cases after the 4<sup>th</sup> ventricle decreased in size, we observed the tip of the catheter touches the brain stem Fig[2D]. Since the patient did not suffer from any new symptoms, we managed this conservatively.

Fig. (2) shows early and late follow-up MRI for TFV with slit ventricle syndrome.



**Fig. (2):** Trapped 4<sup>th</sup> ventricle in a 6-month-old infant following V-P shunt insertion due to post meningitic hydrocephalus. **A)** preoperative MRI axial cuts showing supratentorial slit ventricle with trapped 4<sup>th</sup> ventricle. **B)** sagittal preoperative cuts showing compression of the brain stem. **C)** early postoperative CT brain. **D)** late postoperative CT brain with normalization of the size of the 4<sup>th</sup> ventricle.

Fig (3) shows early and late MRI follow-up of TFV with supratentorial multi-loculated hydrocephalus.



**Fig. (3):** Post meningitic multiloculated hydrocephalus managed by lateral ventricular shunt and repeated

endoscopic fenestrations. **A)** preoperative CT brain showing lateral ventricular encephalomalacia with deformed anatomy together with trapped 4<sup>th</sup> ventricle. **B)** preoperative MRI sagittal cuts. **C)** early postoperative showing a mild reduction in 4<sup>th</sup> ventricular size. **D)** late postoperative with regression of the size of the 4<sup>th</sup> ventricle to normal.

#### Complications related to surgery:

- 1) Wrong direction of the fourth ventricular catheter that necessitated another operation for redirection in one case.
- 2) CSF collection and swelling at the surgery site two weeks after surgery that necessitated the exploration of the wound and the closure of the leak around the ventricular catheter entry with fascia in one case.
- 3) Shunt infection in one case. Removal of the shunt and application of external ventricular drain was done, till infection subsided and reapplication of a new shunt was done again.
- 4) Obstruction of the supratentorial ventricular catheter in one case, a revision was done.
- 5) Disconnection of the valve from the abdominal tube after four years. A revision was made.

No morbidity related to catheter insertion was noticed in our study. No new cranial nerve deficits, motor weakness, or mortality related to surgery were found.

#### DISCUSSION

The term trapped fourth ventricle (TFV), also called (isolated fourth ventricle syndrome), has been used to describe the situation in which the fourth ventricle no longer communicates with the third ventricle, as well as the basal cisterns. It is thought that secondary aqueduct stenosis from adhesions, obstruction of the exit foramina, or infective debris pooling in the basal cisterns may be responsible for this condition <sup>(6)</sup>.

Patients may have typical symptoms and signs of hydrocephalus or more atypical symptoms such as lower cranial nerve dysfunctions. Occasionally, an entrapped fourth ventricle is an incidental finding on imaging for another entity. Symptomatic trapped 4<sup>th</sup> ventricle usually presents after a variable period from the initial VP shunts, ranging from four weeks up to 12 years in some studies <sup>(7,8)</sup>.

In our study trapped 4<sup>th</sup> ventricle presented after a range from 7 months to three years. This delay in the presentation may be responsible for advanced brain stem manifestation in some cases.

In our study 11 patients out of 12 were symptomatic, and only one patient was operated on for a progressive increase in fourth ventricular size without evident clinical manifestation. We did not operate on the asymptomatic trapped 4<sup>th</sup> ventricle. **Pomeraniec et al.** <sup>(9)</sup> also described a stable clinical course of five asymptomatic trapped 4<sup>th</sup> ventricle patients. Unfortunately, evidence-based facts about whether to operate or not on asymptomatic large TVF are lacking in the literature.

### **Pathology and pathogenesis:**

While 4<sup>th</sup> ventricular dilatation may occur due to congenital, neoplastic, and other causes (4), entrapped 4<sup>th</sup> ventricle causes are mostly linked to inflammatory conditions (post-infective and post-hemorrhagic). Ependymal inflammation results in obstruction of the outlet with debris, adhesion, stenosis, obstruction of the aqueduct, and foramina of Luschka and Magendie. At the same time, the 4<sup>th</sup> ventricle choroid plexus and ependyma continue to produce CSF leading to 4<sup>th</sup> ventricle dilatation (10).

The pathogenesis of trapped fourth ventricle may be theoretically explained by multiple suggestions in literature; probably due to the collapse of lateral and third ventricles resulting in slit ventricles, with subsequent adhesion and fusion of opposed ependymal lining of the walls of the cerebral aqueduct (11).

In contrast, some studies suggested trans-tentorial downward herniation of dilated ventricle, combined with upward displacement of the dilated cerebral aqueduct by enlarging the fourth ventricle producing sufficient distortion of the aqueduct leading to an isolated fourth ventricle. Trapped fourth ventricle is frequently also reported with the Dandy-Walker cyst malformation (12).

In our study three patients were preterm, all of them had post-hemorrhagic hydrocephalus and then developed trapped fourth ventricle after a period of time from shunt application. Prematurity seems to be a risk factor due to the high incidence of cerebral hemorrhage. The same observation has been reported by **El Damaty et al.** (13). Prematurity was found to be a significant risk of the development of trapped 4<sup>th</sup> ventricle in their study. The incidence of trapped 4<sup>th</sup> ventricle in prematurity due to post-hemorrhagic hydrocephalus was 29.7%. **Pomeraniec et al.** (9) found the incidence was 15.4%.

### **Etiology:**

The most common etiology in our series for the development of trapped 4<sup>th</sup> ventricle was infection. six out of 12 patients (50%) had V-P shunts for the treatment of post-infectious hydrocephalus, and four of them had multiple shunt revisions and endoscopic fenestration for the treatment of loculated hydrocephalus. This finding supports the theory of inflammatory response with the subsequent closure of the aqueduct together with the 4<sup>th</sup> ventricular outlets. Another study found posthemorrhagic hydrocephalus is the main etiology that predisposes to trapped 4<sup>th</sup> ventricle in up to 76% of their cases (13).

### **Dandy-Walker malformation:**

Dandy-Walker malformation represents a separate dilemma, options for treatment include either shunting the lateral ventricle only or 4<sup>th</sup> ventricular shunting only, or shunting both ventricles. In one study 10% of Dandy-Walker patients with a fourth ventricular catheter needed eventually another lateral ventricular catheter, while 43% of patients with an initial lateral ventricular catheter eventually needed a 4<sup>th</sup> ventricular one (14). In our study, the two Dandy-Walker patients were initially

treated with a lateral ventricular shunt, and both eventually needed 4<sup>th</sup> ventricular catheter connected to the previous one with a Y connector.

### **History:**

Early reports of TFV were done by **Zimmerman et al.** (15). They followed six patients with TFV, out of 48 patients with dilated 4<sup>th</sup> ventricle, and concluded that lateral ventricular shunting may lead to aqueductal adhesions and subsequent 4<sup>th</sup> ventricular isolation and enlargement that would need separate shunting.

However, the first clinical report of TFV was done by **Hawkin et al.** (16) they reported on three patients with symptomatic TFV with a previous history of the V-P shunts with multiple revisions. They reported radiological and clinical improvement after inserting a 4<sup>th</sup> ventricular catheter and connecting it to the pre-existing valve with a Y connector.

Popularization of this technique then follows, until the era of neuro-endoscopy evolved in cranial surgery, aiming at restoring the patency of the 4<sup>th</sup> ventricular outlets in a simple physiological way instead of adding more hardware with possible hardware complications. Although this seems to be more physiological, still literature is lacking sufficient data to ensure the superiority of 1 technique over the other, and all attempts at treating TFV were small series of reports tailored to individual cases (17, 18).

### **Modalities of treatment:**

Rather than fourth ventricular shunting as the most widely used technique, many treatment modalities for isolated fourth ventricles were developed including direct microsurgical ventriculocisternostomy (19, 20). Endoscopic approaches include endoscopic fenestration, aqueductoplasty, aqueductal stenting, and cysto-ventricular fenestration with or without shunting (21, 22).

Some authors favored a direct microsurgical opening of the outlet of the fourth ventricle, avoiding the insertion of a fixed foreign body, as the preferred primary surgical option for entrapment of the fourth ventricle (23). Other authors claimed shunting the fourth ventricle was the less invasive and more effective approach. It is common to use a combination of these techniques to have good results (18). Multiple treatment modalities have been described in the literature, with superiority for endoscopic procedures (24-26).

However, strategies for treatment are still unclear with every report supporting certain procedures according to surgeon preference, availability of endoscopic techniques, and the anatomy of the ventricular system at the time of presentation (9).

No agreement has been found due to the wide diversity of etiologies that may cause a trapped 4<sup>th</sup> ventricle. Thus, treatment modalities should be tailored according to an individual case. The only agreement between the reports was for conservative treatment for asymptomatic trapped 4<sup>th</sup> ventricle with no progressive enlargement of the size of the 4<sup>th</sup> ventricle (4, 9).

#### **4<sup>th</sup> ventricular catheter and Y connector:**

Our treatment option in this study for TFV in preexisting supratentorial hydrocephalus drained by a ventriculoperitoneal shunt is a fourth ventricular catheter, which was done by lateral suboccipital approach through inserting another ventricular catheter and connecting it to the supratentorial ventriculoperitoneal shunt by a (Y connector), two ends connected to the 2 proximal tubes and the third to the medium pressure valve to the distal tube.

Due to the wide use of the contoured type of valve of V-P shunt in our practice, which has proximal and distal ends needed for the use of Y connector, we succeeded to use Y connectors with every 4<sup>th</sup> ventricular catheter connecting it to the previously implanted V-P shunt through the same incision without the need for adding a new valve or new abdominal tube, thus decreasing the possibility of shunt malfunction or infection.

We used the commercially available Medtronic silicon Y connector in 10 cases and the titanium connector of Integra in the other two cases. Choosing the type of connector depended only on the availability in our hospital. Y connectors have been advocated by many authors when a fourth ventricular catheter is a plan (13).

They claimed that this may also prevent any pressure difference between supra and infratentorial ventricular systems, being connected to the same valve, thus decreasing the possibility of headache that may occur by changes in the position of the body (18).

4<sup>th</sup> ventricular catheter as a treatment option for trapped 4<sup>th</sup> ventricle, although seems to be old fashion and carries a lot of hardware complications, sometimes it represents the only treatment option for trapped 4<sup>th</sup> ventricle and maybe the endpoint after the failure of other modalities such as aqueductal stenting and 4<sup>th</sup> ventriculocisternostomy.

This seems to be more evident in cases where the lateral ventricle is totally collapsed in slit ventricle syndrome, which is not uncommon following supratentorial shunting Fig[2], rendering endoscopic procedures difficult and needs to be done via the 4<sup>th</sup> ventricle itself through endoscopic trans 4<sup>th</sup> ventricular aqueductoplasty which has been described by some reports with a small number of cases and relatively short term follow up (27).

#### **Endoscopic techniques:**

when endoscopic techniques are not feasible to be performed through the lateral ventricle due to collapsed lateral ventricle or slit ventricle syndrome in cases of lateral ventricular over shunting, some reports advocated aqueductoplasty to be performed retrograde through sub occipital transforamen of magendie approach (28).

**Gallo et al.** (21) described a similar technique. This technique seems to be difficult, especially in infants and children with a small 4<sup>th</sup> ventricle, who are the most affected group of TFV due to infection or hemorrhage. Endoscopic techniques were developed to avoid shunting the fourth ventricle in TFV. The fourth

ventricle can be approached via the supratentorial route or infratentorial route then aqueductoplasty follow to ensure one CSF communication ventricular drainage. The infratentorial approach is favored in cases with complex post-infective and post-hemorrhagic cases that had many supratentorial adhesions and loculations (21).

**Fritsch et al.** (25) found a 73% closure rate after aqueductoplasty, and a review by **Gallo et al.** (21) found this to be 53%, but they also concluded that they had no restenosis or closure when the stent was added. Aqueductoplasty with or without stenting may have some complications such as transient ophthalmoparesis due to tectal midbrain pressure or injury (10% of cases) (29). **Sagan et al.** (30) had some complication as parinaud syndrome, rotatory nystagmus, and abducent nerve palsy in their study using endoscopic aqueductoplasty with stenting.

Restenosis and stent migration were reported even after successful initial stenting. Stent migration may produce cranial nerve palsy, also transtentorial herniation has been reported after the endoscopic aqueductoplasty and stent insertion in a case report. The patient developed quadriplegia and cranial nerve deficits, and 4<sup>th</sup> ventricular shunting was needed to solve this problem (31).

In 1999 **Teo et al.** (29) reported on eight patients with TFV treated endoscopically, one patient eventually needed 4<sup>th</sup> ventricular shunt. The complication rate was up to 25%.

In our study, a slit lateral ventricle has been observed preoperatively in 50% of our cases Fig[2], which renders endoscopic aqueductoplasty difficult. Another factor that has been encountered in our study is the multiloculations of the supratentorial ventricular system in 33% of our cases as a sequelae of the previous infection Fig[3]. This led to high disturbance in the anatomy of the ventricle, which made attempting to enter the deformed aqueduct dangerous.

Long aqueduct is another cause of favoring 4<sup>th</sup> ventricular shunting over aqueductoplasty. Aqueductoplasty and stenting have been favored by **Mohanty et al.** (26) in patients with short-segment aqueductal stenosis, while fourth ventricular shunting was advocated by them when long-segment stenosis is encountered. Although, they found that both techniques were equally effective in managing the trapped 4<sup>th</sup> ventricle. A high rate of recurrence has been reported by several authors after aqueductoplasty only without stenting (7, 21).

**Pomeraniec et al.** (9) reported on three patients managed endoscopically for TFV and eventually received 4<sup>th</sup> ventricular catheter at the end of the follow-up.

Some authors reported the use of the cranial endoscope in the management of trapped 4<sup>th</sup> ventricle by inserting the ventricular catheter antegrade from the lateral ventricle through the aqueduct to the 4<sup>th</sup> ventricle under endoscopic visualization so that draining both supra and infratentorial ventricular system via single Kocher valve. They concluded that this is a valid option only

with clear anatomic landmarks in the supratentorial ventricular system together with short aqueductal stenosis (22).

#### **Ventriculocisternostomy:**

Although posterior 4<sup>th</sup> ventricular fenestration to the subarachnoid space seems to be a valid alternative option when endoscopy is not feasible, still it is major surgery with posterior fossa craniotomy that may carry cranial surgery complications. **Tyagi et al.** (18) adopted this technique with trapped 4<sup>th</sup> ventricle patients with previous shunt malfunction especially patients with craniospinal syringes to establish the CSF pathway.

#### **4<sup>th</sup> ventricular catheter insertion:**

Placement of the 4<sup>th</sup> ventricular catheter could be done through a midline or lateral suboccipital burr holes however we found the lateral burrholes more convenient because we used Keen's burrholes for previous supratentorial shunt placement thus, the Y connector can be used easily through widening the previously made flap only (32).

Inserting the 4<sup>th</sup> ventricular catheter although easy but still carries the risk of reaching the brain stem and causing injury either during the insertion of it or later on when the ventricle collapses bringing the brainstem close to the tip of the catheter (33).

**Eder et al.** (20) found two cases of cranial nerve palsy after one week and six weeks from inserting the 4<sup>th</sup> ventricular catheter. To avoid this, some authors advocate the use of stereotaxy or ultrasound during the insertion of the tube. Other authors advocate introducing the catheter parallel to the floor of the 4<sup>th</sup> ventricle to avoid this complication (8,19).

In our study, this complication hasn't been encountered even though we had one patient with postoperative MRI follow-up with a long catheter touching the brainstem Fig[2].

In their long-term study, **El Damaty et al.** (13) reported 21 patients with trapped 4<sup>th</sup> ventricles managed surgically. 18 out of 21 patients had a 4<sup>th</sup> ventricular catheter connected to the previously implanted lateral ventricular catheter. Another patient had failed ventriculocisternostomy and ended up having 4<sup>th</sup> ventricular catheter. No surgery-related complications have been encountered in their study apart from catheter migration, slippage, and obstruction in only four cases during the follow-up.

In our study, all complications were minor mostly related to shunt system failure by disconnection, leak, obstruction, and infection. The wrong direction of the 4<sup>th</sup> ventricular catheter has been noticed in one patient, which necessitated redirection in another surgery.

#### **CONCLUSION**

Trapped 4<sup>th</sup> ventricle, although rare, may affect the clinical condition of the previously shunted patients insidiously. Different modalities of treatment have been described for the treatment of this pathology; however, the literature is still lacking uniform guidelines, and

management should be tailored according to the individual case.

Although endoscopic procedures have gained popularity in the treatment of such pathology, CSF diversion remains widely accepted as a safe and less invasive procedure especially when endoscopy is not feasible or after the failure of other techniques.

Our results support that adding a 4<sup>th</sup> ventricular catheter with a Y connector in previously shunted patients for treatment of trapped fourth ventricle is a valid, effective and safe modality of treatment, especially with multiloculated supratentorial hydrocephalus and slit ventricle patients.

**Financial support and sponsorship:** Nil.

**Conflict of interest:** Nil.

#### **REFERENCES**

1. **Panagopoulos D, Karydakis P, Themistocleous M (2021):** The entity of the trapped fourth ventricle: A review of its history, pathophysiology, and treatment options. *Brain Circ.*, 7(3): 147-58.
2. **Fritsch M, Kienke S, Manwaring K et al. (2004):** Endoscopic aqueductoplasty and interventriculostomy for the treatment of isolated fourth ventricle in children. *Neurosurgery*, 55:372–377.
3. **Spennato P, Cinalli G, Carannante G et al. (2005):** Multiloculated hydrocephalus. Springer, Pp. 219-44. [https://link.springer.com/chapter/10.1007/978-88-470-2121-1\\_16](https://link.springer.com/chapter/10.1007/978-88-470-2121-1_16)
4. **Harter D (2004):** Management strategies for treatment of the trapped fourth ventricle. *Childs Nerv Syst.*, 20(10):710-6.
5. **Ang B, Steinbok P, Cochrane D (2006):** Etiological differences between the isolated lateral ventricle and the isolated fourth ventricle. *Childs Nerv Syst.*, 22(9):1080-5.
6. **Dauda H, Sale D (2021):** Trapped fourth ventricle: A case report and review of literature. *Int J Surg Case Rep.*, 80:105-18.
7. **Cinalli G, Spennato P, Savarese L et al. (2006):** Endoscopic aqueductoplasty and placement of a stent in the cerebral aqueduct in the management of isolated fourth ventricle in children. *J Neurosurg.*, 104(1 ):21-7.
8. **Garber S, Riva-Cambri J, Bishop F et al. (2013):** Comparing fourth ventricle shunt survival after placement via stereotactic transtentorial and suboccipital approaches. *J Neurosurg Pediatr.*, 11(6):623-9.
9. **Pomeranic I, Ksendzovsky A, Ellis S et al. (2016):** Frequency and long-term follow-up of trapped fourth ventricle following neonatal posthemorrhagic hydrocephalus. *J Neurosurg Pediatr.*, 17(5):552-7.
10. **Rekate H (2011):** A consensus on the classification of hydrocephalus: its utility in the assessment of abnormalities of cerebrospinal fluid dynamics. *Childs Nerv Syst.*, 27(10):1535-41.
11. **Spennato P, O'Brien D, Fraher J et al. (2005):** Bilateral abducent and facial nerve palsies following fourth ventricle shunting: two case reports. *Childs Nerv Syst.*, 21(4):309-16.
12. **Hdeib A, Cohen A (2012):** Hydrocephalus in children and adults. *Principles of neurological surgery: Elsevier Inc.*, Pp. 105-27.

<https://jhu.pure.elsevier.com/en/publications/hydrocephalus-in-children-and-adults>

13. **El Damaty A, Eltanahy A, Unterberg A *et al.* (2020):** Trapped fourth ventricle: a rare complication in children after supratentorial CSF shunting. *Childs Nerv Syst.*, 36(12):2961-9.
14. **Warf B, Dewan M, Mugamba J (2011):** Management of Dandy-Walker complex-associated infant hydrocephalus by combined endoscopic third ventriculostomy and choroid plexus cauterization. *J Neurosurg Pediatr.*, 8(4):377-83.
15. **Zimmerman R, Bilaniuk L, Gallo E (1978):** Computed tomography of the trapped fourth ventricle. *AJR Am J Roentgenol.*, 130(3):503-6.
16. **Hawkins J, Hoffman H, Humphreys R (1978):** Isolated fourth ventricle as a complication of ventricular shunting: report of three cases. *J Neurosurg.*, 49(6):910-3.
17. **Upchurch K, Raifu M, Bergsneider M (2007):** Endoscope-assisted placement of a multiperforated shunt catheter into the fourth ventricle via a frontal transventricular approach. *Neurosurg Focus*, 22(4):1-8.
18. **Tyagi G, Singh P, Bhat D *et al.* (2020):** Trapped fourth ventricle—treatment options and the role of open posterior fenestration in the surgical management. *Acta Neurochirurgica*, 162(10):2441-9.
19. **Montes J, Clarke D, Farmer J (1994):** Stereotactic transtentorial hiatal ventriculoperitoneal shunting for the sequestered fourth ventricle. Technical note. *J Neurosurg.*, 80(4):759-61.
20. **Eder H, Leber K, Gruber W (1997):** Complications after shunting isolated IV ventricles. *Childs Nerv Syst.*, 13(1):13-6.
21. **Gallo P, Szathmari A, Simon E *et al.* (2012):** The endoscopic trans-fourth ventricle aqueductoplasty and stent placement for the treatment of trapped fourth ventricle: long-term results in a series of 18 consecutive patients. *Neurol India*, 60(3):271-8.
22. **Elsharkawy A, Elatrozy H (2020):** Endoscopic antegrade aqueductoplasty and stenting with panventricular catheter in management of trapped fourth ventricle in patients with inadequately functioning supratentorial shunt. *Surg Neurol Int.*, 11:393-8.
23. **Udayakumaran S, Bo X, Ben Sira L *et al.* (2009):** Unusual subacute diencephalic edema associated with a trapped fourth ventricle: resolution following foramen magnum decompression. *Childs Nerv Syst.*, 25(11):1517-20.
24. **Schulz M, Goelz L, Spors B *et al.* (2012):** Endoscopic treatment of isolated fourth ventricle: clinical and radiological outcome. *Neurosurgery*, 70(4):847-59.
25. **Fritsch M, Schroeder H (2013):** Endoscopic aqueductoplasty and stenting. *World Neurosurg.*, 79(2):20-8.
26. **Mohanty A, Manwaring K (2018):** Isolated fourth ventricle: to shunt or stent. *Oper Neurosurg.*, 14(5):483-93.
27. **Khayat H, Al-Saadi T, Panet-Raymond V *et al.* (2019):** Surgical management of isolated fourth ventricular hydrocephalus associated with injury to the Guillain-Mollaret triangle. *World Neurosurg.*, 122:71-6.
28. **Say I, Dodson V, Tomycz L *et al.* (2019):** Endoscopic fourth ventriculostomy: Suboccipital transaqueductal approach for fenestration of isolated fourth ventricle: Case report and technical note. *World Neurosurg.*, 129:440-4.
29. **Teo C, Burson T, Misra S (1999):** Endoscopic treatment of the trapped fourth ventricle. *Neurosurgery*, 44(6):1257-62.
30. **Sagan L, Kojder I, Poncyłjusz W (2006):** Endoscopic aqueductal stent placement for the treatment of a trapped fourth ventricle. *J Neurosurg Pediatr.*, 105(4):275-80.
31. **Frassanito P, Markogiannakis G, Di Bonaventura R *et al.* (2015):** Descending transtentorial herniation, a rare complication of the treatment of trapped fourth ventricle: case report. *J Neurosurg Pediatr.*, 16(5):540-4.
32. **Carter L, Gross N (2021):** Endoscopic placement of fourth ventricular catheter using Seldinger technique: Description of technique and case series. *Oper Neurosurg (Hagerstown)*, 21(4):304-8.
33. **Simonin A, Levivier M, Bloch J *et al.* (2015):** Cranial nerve palsies after shunting of an isolated fourth ventricle. *BMJ Case Rep.*, 2015:75-9.