

**Histological and Histochemical study of testicular tissue  
used in cases of (ICSI)  
(Intra Cytoplasmic Sperm Injection)**

**Asharf M. Moustafa. Mohamed O. M. Khater Moustafa I. Hassan  
Ezz Eldin Elsharkawy and Taymour M.K El-Tounissy**

From Departments of Histology and Dermatology and Venereology.  
Faculty of Medicine AL- Azhar University

**Abstract**

**Background:** The advances in the technology of in vitro fertilization (IVF) increases the incidence of success in treatment cases of infertile patients with non-obstructive azoospermia. Evaluation of the microscopic changes in the obtained testicular samples was one of the main aims in this study for better prognosis of the results.

**Material and methods:** In this study one hundred human testicular biopsies were obtained from Islamic reproductive centre and Department of Urology Al- Hussein University Hospital .

**Cases in this study were classified into 4 groups:**

**Group I:** Includes 5 cases of normal fertile persons free of any medical problems and with normal seminal parameters. Patients.

Consent was performed before sampling.

**Group II:** Includes 35 cases of infertile obstructive azoospermic patients.

All of the rest of cases (60) were considered infertile non obstructive azoospermic cases and were included in both the third and the fourth groups

**Group III:** Includes 20 cases of infertile non obstructive positive patients.

**Group IV:** Includes 40 cases of infertile non obstructive negative patients. Cases were either of normal sized testis or of hypoplastic testis and were subdivided into the following subgroups:

**I- Cases with normal sized testes (30) infertile patients:**

**Group IV A:** Normal sized testis with arrested spermatogenesis

**Group IV B:** Normal sized testis with SCOS.

**Group IV C:** Normal sized testis with mixed atrophy.

**II- Cases with hypoplastic testes (10) infertile patients:**

**Group IV D:** Hypoplastic testis.

The testicular samples were prepared for Histological and Histochemical examination.

Different staining techniques were used:

1-Haematoxylin and Eosin stain

2-Mallory's trichrome stain

3-Histochemical techniques

a-Periodic acid Schiff (PAS) technique.

b-Methyl green pyronin

**Results:** The obtained results showed no Morphological changes in group II except mild vascular dilatation and congested peritubular capillaries. Cases of non obstructive positive azoospermia showed reduced number of spermatogenic layers while cases of group IVa showed reduced size of the tubules and lined only by Sertoli cells and there was marked reduction in the number of leydig cells.

**Conclusions:** In this study there were definite histochemical changes observed in both the PAS positive material and the nucleic acid content in the different elements of the obtained testicular samples, Clinical and microscopic evaluations in this study could be of complementary importance and may increases the incidence of success.

**Key words:** ICSI – Testis – Histochemical techniques – Azoospermia.

## Introduction

Diagnostic testicular biopsy (DTB) is one of the most important recent diagnostic procedures in the study of male infertility. Testicular aspiration was first stated as a diagnostic method for azoospermia by (Huhner, 1913 & 1928), and since then it has been used only for the diagnosis and prognosis in cases of male infertility such as azoospermia and unexplained severe oligozoospermia (Charny, 1940 ; Ragab *et al.*, 1961; Dubin and Hotchkiss, 1969; Amelar and Dubin, 1973).

Clermont (Clermont, 1963), in describing the cycle of human tubular epithelium, reported a quantitative method for most precise evaluation of tubules population.

During the 1990s, the introduction of intracytoplasmic sperm injection (ICSI) procedures in patients with severe oligozoospermia (Palermo *et al.*, 1992; Van Steirteghem *et al.*, 1993) dramatically increases the interest in DTB again and were first reported after using testicular spermatozoa, with ICSI, from men with obstructive azoospermia (Craft *et al.*, 1993; Schoysman *et al.*, 1993).

Testicular biopsy became for the first time a therapeutic procedure and, together with the ICSI technique, was considered an effective fertility treatment for patients with non-obstructive azoospermia, who were offered the possibility of fathering their own genetic children (Devroey *et al.*, 1994, 1995).

The most common histological patterns of these patients are in the form of hypospermatogenesis, maturation arrest and Sertoli cell-only syndrome (SCOS), with or without focal spermatogenesis.

Spermatozoa can be retrieved after TESE in almost all patients with a microscopical diagnosis of hypospermatogenesis. Two distinct patterns of SCOS, with different pathogenesis and prognosis, have been already described (Charny and Meranze, 1942; Chemes *et al.*, 1977; Nistal and Paniagua, 1984).

Also it is needed to understand the bases of testicular structure and evaluating its microscopic changes in different cases which are used in cases of (ICSI)

In this study it was planned to add a new parameter in evaluating and managing cases of infertility especially those of azoospermia which is the microscopic examination of testicular tissue morphologically as well as histochemically for evaluation of the obtained results.

## Material And Methods

In this study one hundred human testicular biopsies were obtained From Islamic assistant reproductive centre and Department of Urology Al- Hussein University Hospital.

Morphological and histochemical assessments of the obtained biopsies were performed in the Central Research Unit of Histology Department of Al-Azhar Faculty of Medicine. Evaluation of all Azoospermic cases in this study was performed through variable main parameters:

Clinical examination of the cases for diagnosing the nature of each case, if it is of the obstructive or non obstructive type.

Microscopic examination of the testicular biopsies for visualization of the sperms. Case was considered positive in the presence of the sperms and negative in its absence.

Cases in this study were classified into 4 groups:

**Group I:** Includes five cases of normal fertile persons free of any medical problems and with normal seminal parameters. Patients consent was performed before sampling .

**Group II:** Includes 35 cases of infertile obstructive azoospermic patients.

All of the rest of cases (60) were considered infertile non obstructive azoospermic cases and were included in both the third and the fourth groups

**Group III:** Includes 20 cases of infertile non obstructive positive patients.

**Group IV:** Includes 40 cases of infertile non obstructive negative patients. Cases were either of normal sized testis or of hypoplastic testis and were subdivided into the following subgroups:

# I- Cases with normal sized testes (30) infertile patients:

**Group IV A:** Normal sized testis with Arrested spermatogenesis

**Group IV B:** Normal sized testis with SCOS.

**Group IV C:** Normal sized testis with Mixed atrophy.

# II- Cases with hypoplastic testes (10) infertile patients:

**Group IV D:** Hypoplastic testis.

Paraffin sections ( 6 um) of testicular samples were prepared for Histological and Histochemical examination. Different staining techniques were used:

1-Haematoxylin and Eosin stain Kiernan (1999)

2-Mallory's trichrome stain Elftman (1963)

3-Histochemical techniques

a-Periodic acid Schiff (PAS) technique Elftman H (1963)

b-Methyl green pyronin Elftman (1963)

## Results

### A- MORPHOLOGICAL CHANGES (Figs 1-20)

**CONTROL GROUP:** It was noticed that sections of control human testicular biopsies were formed of two main components:

1-Tubular component, which is mainly formed of seminiferous tubules.

2- Interstitial compartment, which is located between the seminiferous tubules. The results showed that the tubular compartment is formed of the following cellular elements: A- Spermatogenic cells B- Sertoli cells C- Peritubular cells.

Spermatogenic cells were differentiated to basal spermatogonia which rest on the basal lamina and distinguished to both type A and B. The Primary spermatocyte was the largest of all the spermatogenic series. The spermatid was seen close to the tubular lumen and characterized by its spherical nucleus. Sertoli cells were located within the spermatogenic epithelium and characterized by its deep infolding of its nuclei. Leydig cells were arranged in groups of polygonal eosinophilic cells and surrounded by

interstitial connective tissue.

**GROUP II of OBSTRUCTIVE AZOSPERMIA** showed no changes in the growth and development of the spermatogenic cells. All the members of that series were observed in normal structural state. Changes in the vascular state of the tubule in the form of vascular dilatation and congested peritubular capillaries. There was decrease in the number of Sertoli cells.

**GROUP III of ( Non obstructive positive azospermia)** showed variable microscopic structure of the seminiferous tubules in the different cases of this group. Some cases the tubule was more or less of normal structure, other cases showed reduced number of the spermatogenic cell layers. The basal layers were separated from the basal lamina of the tubules. The distribution of collagenous fibers was noticed to be definitely increased especially in concentric manner in the basal lamina. There was increase number of both myofibroblast and myoid cells in the basal lamina. Some cases showed multiple cellular vacuolization especially the Sertoli cells.

Cases of non obstructive negative azospermia (**Group IV A**) normal size of the tubules as well as arrested spermatogenesis. The size of the testicular tubule was more or less within the normal but some of the tubules were reduced sizes. It was noticed that there was a distinct decrease in the spermatogenic cell layers. Spermatogenic layers were arrested at the level of primary spermatocyte and no other layers were detected. No mitotic changes were observed in these cells. No sperms were detected. The tubular basal lamina was thickened by increase collagen bundles deposition. Leydig cells were few in number and showed mild degenerative changes.

Cases of group IV B ( **Normal sized testis SCOS** ) showed tubules of moderate size and surrounded with multilayered basal lamina. No spermatogenic cell series were identified and the tubules are only lined with Sertoli cells. Sertoli cells were observed to be tall with its intended basal nuclei. No sperms were seen in the central

tubular lumens. The surrounding basal lamina was thickened and splitted to many layers and in some tubules was forming a knobs like structure invading the tubular cavity.

Cases of (Normal sized testes with mixed atrophy) showed variable findings because it includes both results of arrested spermatogenesis and those of SCOS. Some tubules were of the arrested spermatogenic activity in the form of reduced number of spermatogenic cell layers and absence of luminal sperms. Reduced size of the tubules and irregularities in its border. Increased thickness of the basal lamina. Dilated vessels in the intertubular spaces. Marked reduction in the number of leydig cells.

Sections of the arrested spermatogenic activity of SCOS showed tubules were only lined by sertoli cells and no spermatogenic cells were observed. Leydig cells were markedly decreased in number.

## **B- HISTOCHEMICAL CHANGES (Figs 21-32)**

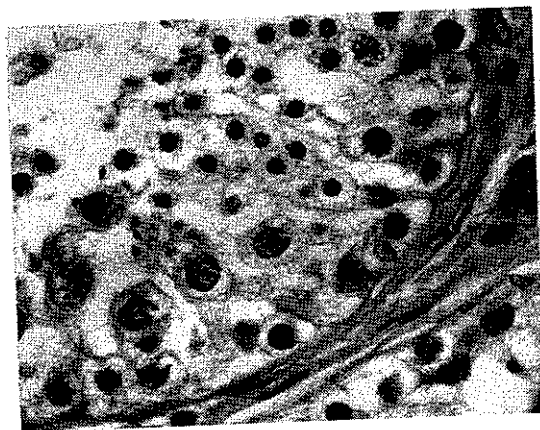
### **1-Changes in mucopolysaccharides content (MPS)(Figs 21-26)**

The estimated values of the PAS content showed no significant difference between the control group and group II, group III but there are Significant decrease in the PAS positive material in all subgroup of group IV especially Subgroup IVa (arrested spermatogenic activity) due to increase primary spermatocyte activity compensate the cellular degenerations.

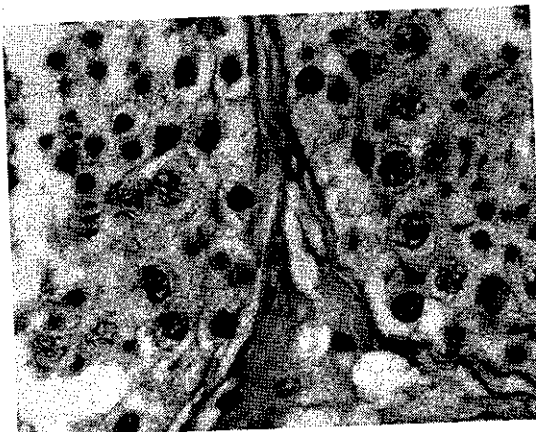
### **2-Changes in the nucleic acid content ( Figs 27-32)**

In this study cases of control group showed abundance of DNA in the nuclei of both the spermatogonia and the dividing primary spermatocytes and head of sperm.

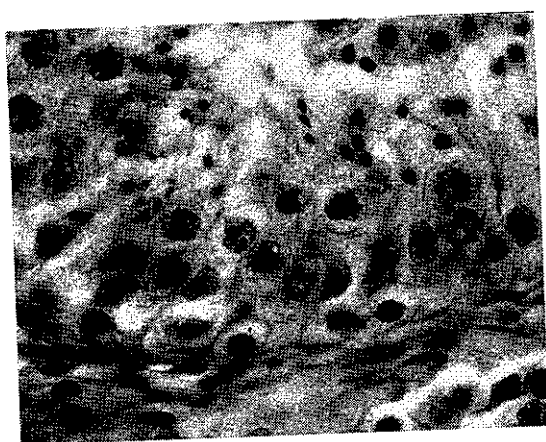
The estimated values showed significant decrease in nucleic acid contents in both all group II and group III. Also there are a mild significant decrease in nucleic acid contents in subgroup IVa but a marked significant decrease nucleic acid contents in subgroup IVb, IVc and IVd.



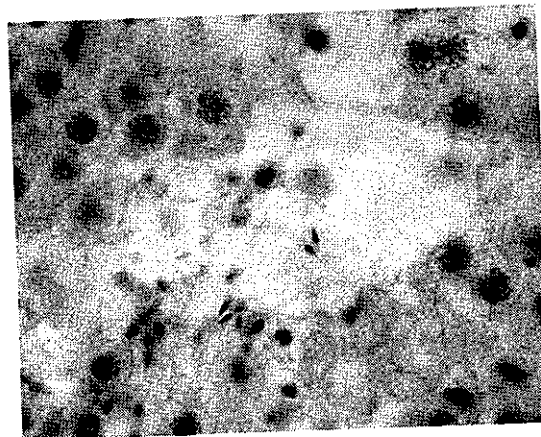
(Fig .1) Section in control testicular tissue, shows normal spermatogenic cells and luminal sperms and normal leydig cells .  
(H.X stain , X450)



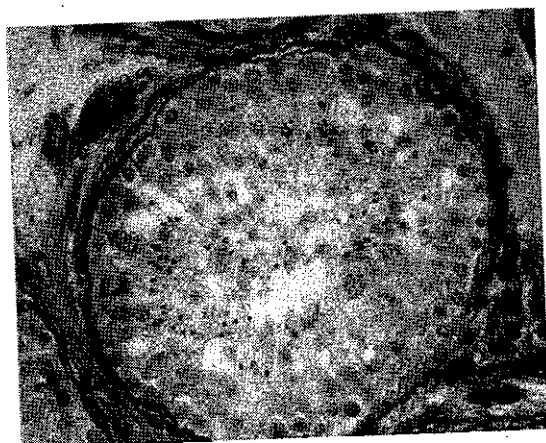
(Fig .2) Section in control testicular tissue, shows normal spermatogenic cells with many mitotic stages of division .  
(H.X stain , X 450)



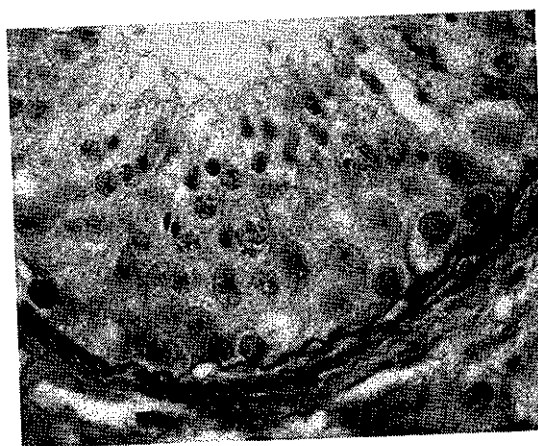
(Fig.3) Section in human testicular tissue (Group II) Thick basal lamina and normal cells and sperms.  
(H.X stain , X 450)



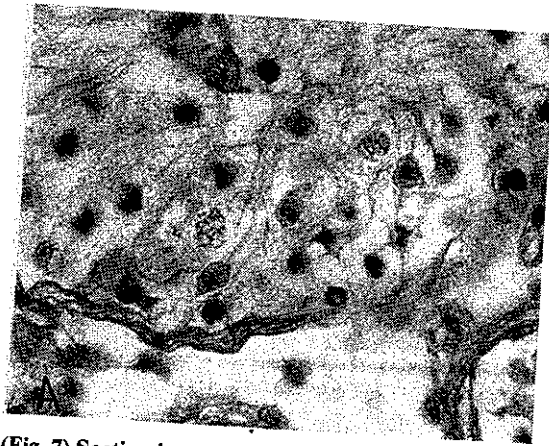(Fig.4) Section in human testicular tissue (Group II) shows spermatogenic cells with many mitotic stages of division.  
(H.X stain , X 450)



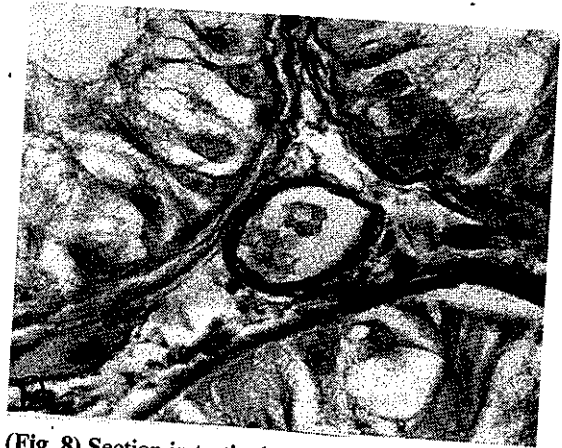(Fig .5) Section in testicular tissue, (Group III) shows fibrosis in the intertubular tissue and thick basal lamina.  
(H.X stain , X 250)



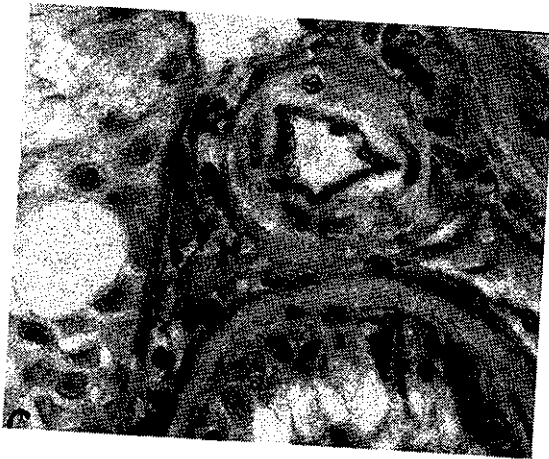
(Fig .6) Section in testicular tissue, (Group III) shows thickened basal lamina.  
(H.X stain , X 450)



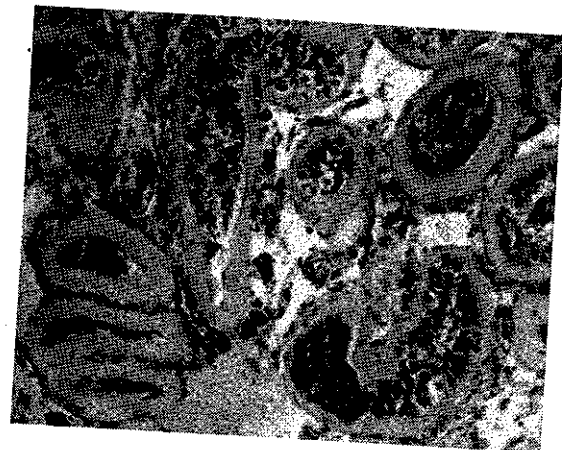
(Fig.7) Section in testicular tissue (Group IVa)  
Shows reduced number of spermatogenic  
layers.  
(H.X stain , X 450)



(Fig.8) Section in testicular tissue (Group IVb)  
Shows no sperms and the tubules lined by  
sertoli cells.  
(H.X stain , X 450)

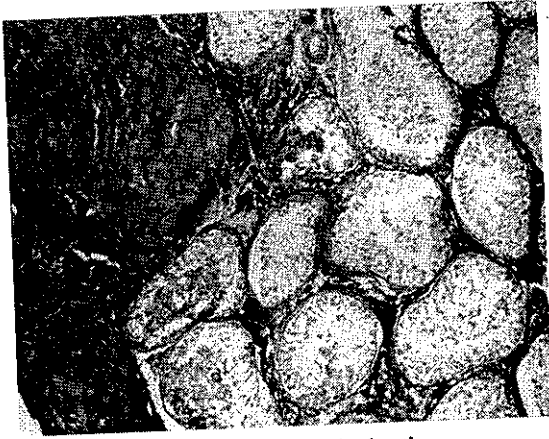

(Fig.9) Section in testicular tissue (Group IVc)  
Shows marked tubular arrest.  
(H.X stain , X 450)

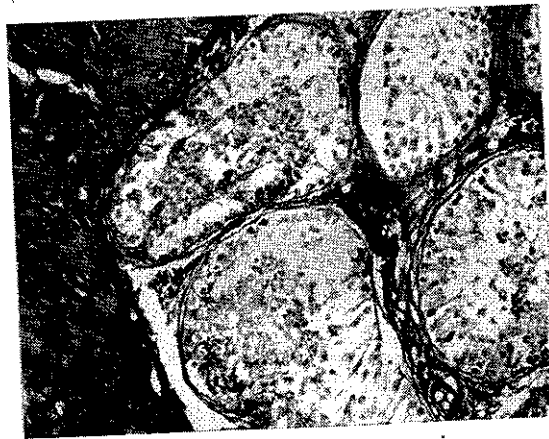

(Fig.10) Section in testicular tissue (Group IVd)  
Shows marked thickened basal lamina.  
(SCOS)  
(H.X stain , X 450)

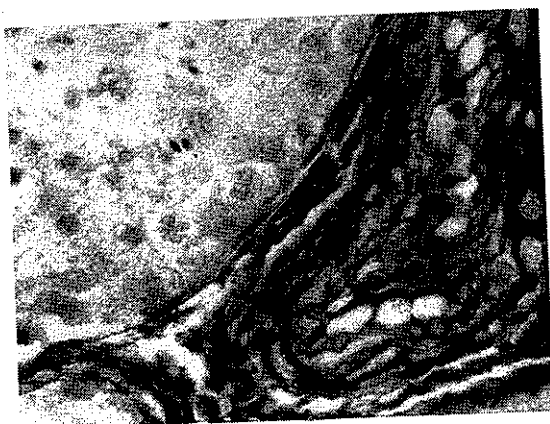



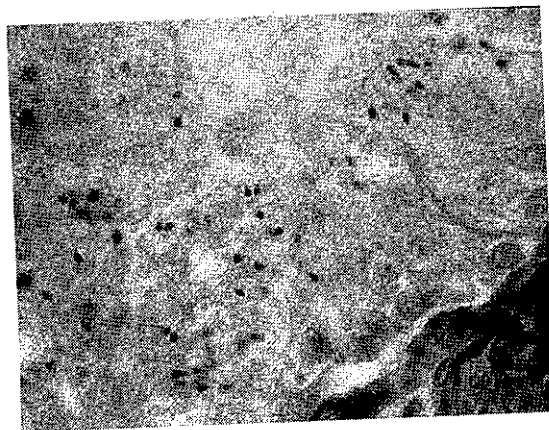
(Fig .11) Section in control testicular tissue shows normal distribution of collagenous fibers in the mediastinum testis (Mallory stain X 450)



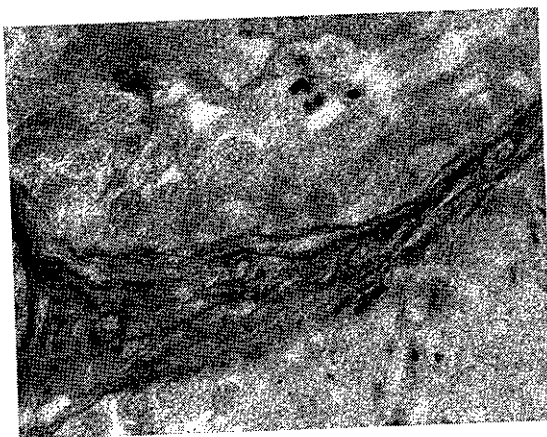
(Fig .12) Section in control testicular tissue shows normal distribution of collagenous fibers around the testicular tubules (Mallory stain X 450)



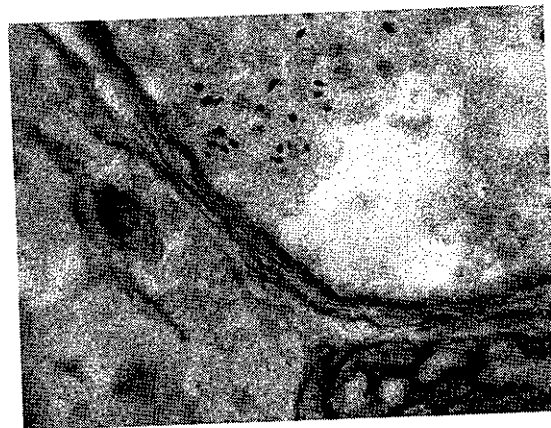
(Fig .13) Section in testicular tissue group II shows thick distribution of collagenous fibers at the basal lamina (Mallory stain X 450)



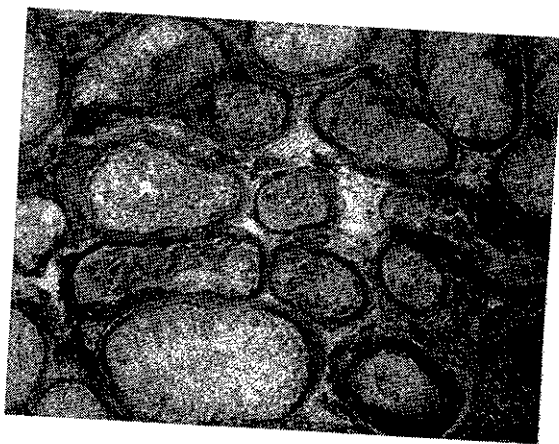
( Fig .14) Section in testicular tissue group II shows thick distribution of collagenous fibers at the basal lamina (Mallory stain X 450)



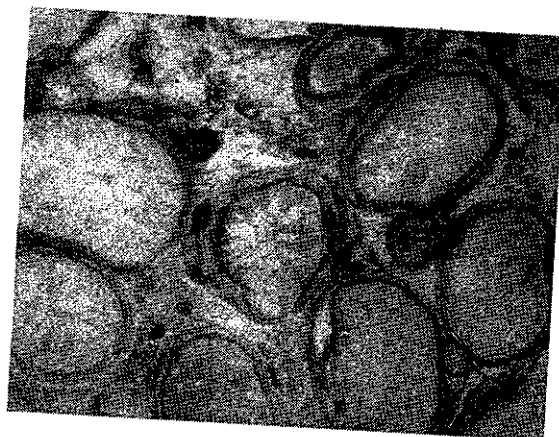
(Fig .15) Section in testicular tissue group III shows thick basal lamina and fibrosed intertubular tissue (Mallory stain X 450)



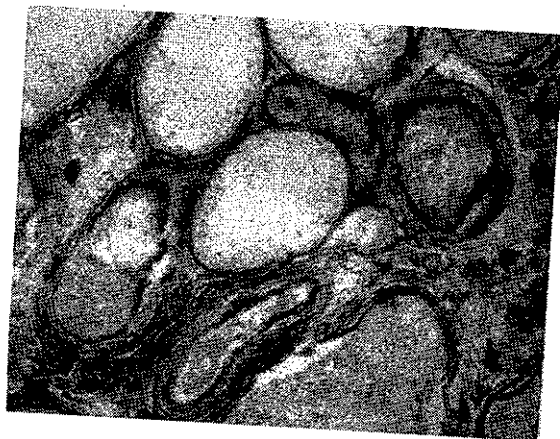
(Fig .16) Section in testicular tissue group III shows thick collagen and fibrosed intertubular tissue (Mallory stain X 450)



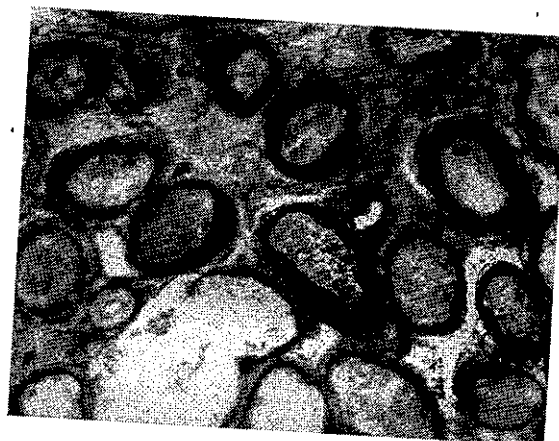
(Fig .17) Section in testicular tissue group IVa shows thick collagen and fibrosed intertubular tissue (Mallory stain X 450)



(Fig .18) Section in testicular tissue group IVb shows fibrosed intertubular tissue (Mallory stain X 450)

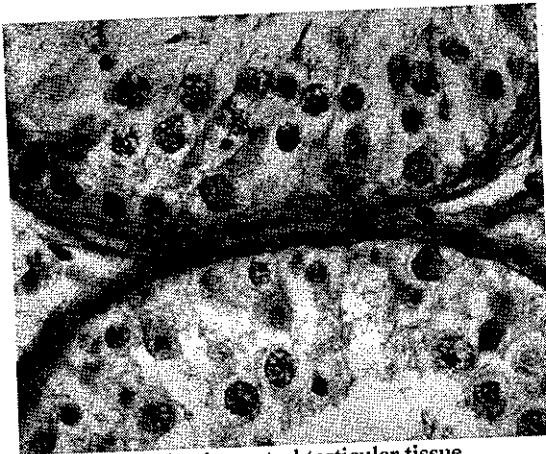

(Fig .19) Section in testicular tissue group IVc shows thick collagen and knobs at the basal lamina (Mallory stain X 450)

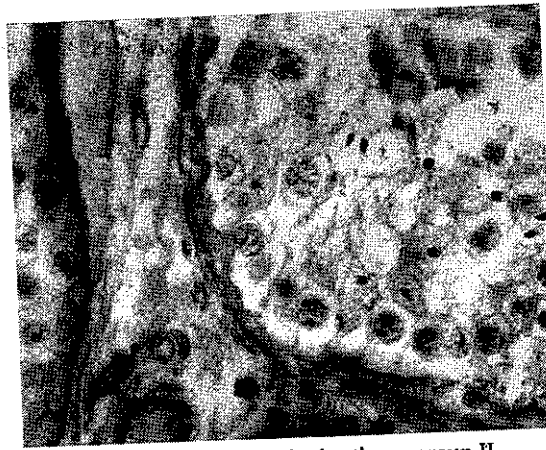


(Fig .20) Section in testicular tissue group IVd shows marked thickened basal lamina (Mallory stain X 450)

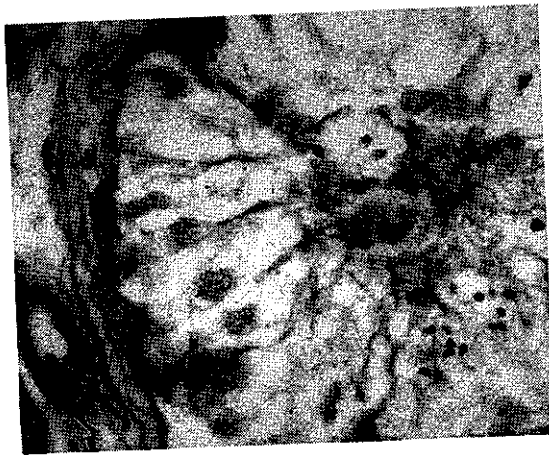



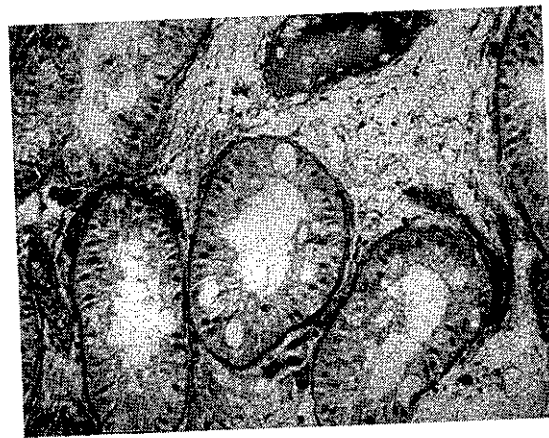(Fig .21) Section in control testicular tissue  
Shows Normal distribution of PAS +  
material. ( PAS stain X 450)



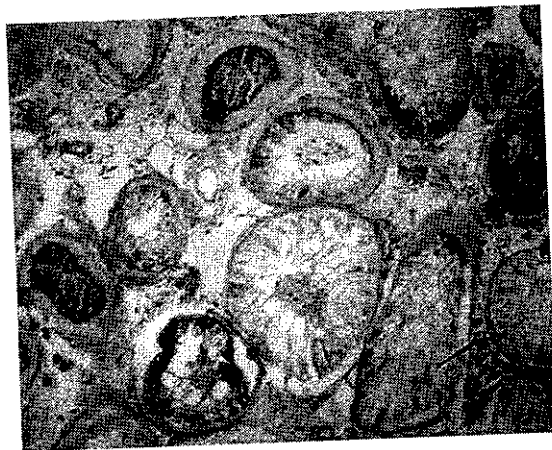(Fig .22) Section in testicular tissue group II  
shows Normal distribution of PAS +  
material. ( PAS stain X 450)



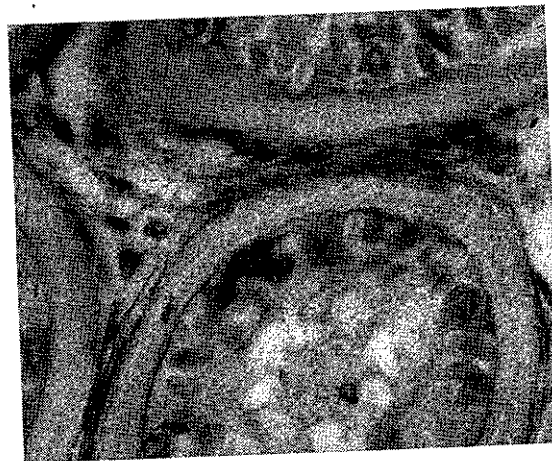
(Fig .23) Section in testicular tissue group III  
shows Normal distribution of PAS +  
material. ( PAS stain X 450)



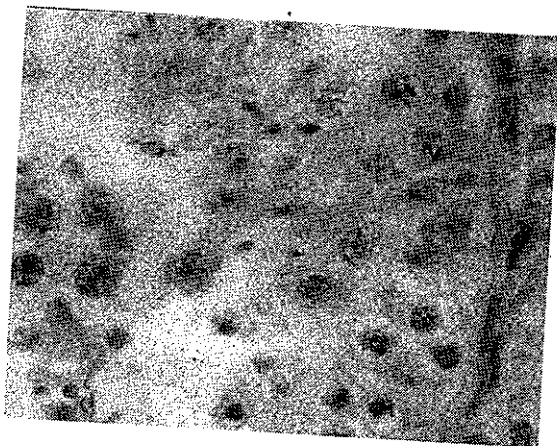
(Fig .24) Section in testicular tissue group IVb  
shows the distribution of PAS +  
material. ( PAS stain X 450)



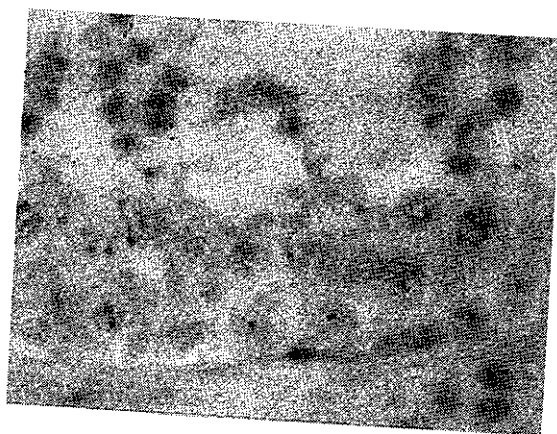
(Fig .25) Section in testicular tissue group IVc  
shows the distribution of PAS + material.  
( PAS stain X 450)



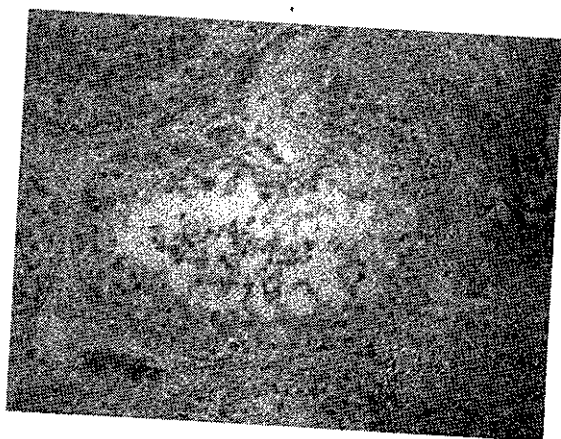
(Fig .26) Section in testicular tissue group IVd  
Shows the distribution of PAS + material:  
( PAS stain X 450)



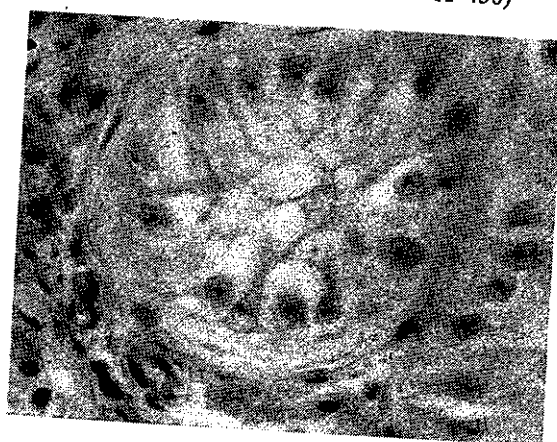
(Fig .27) Section in control testicular tissue  
Shows nucleic acid contents distribution  
( Methyl green pyronin stain X 450)



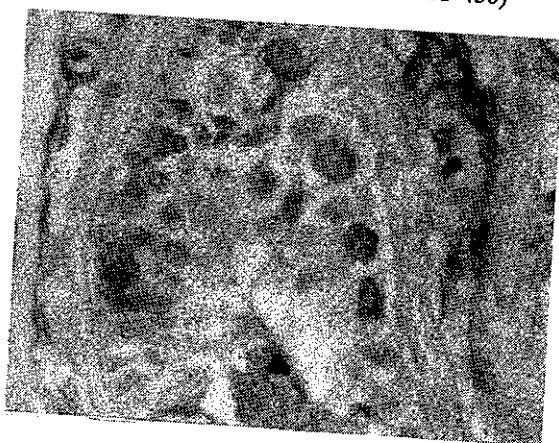
(Fig .28) Section in testicular tissue group II  
Shows nucleic acid contents distribution  
( Methyl green pyronin stain X 450)



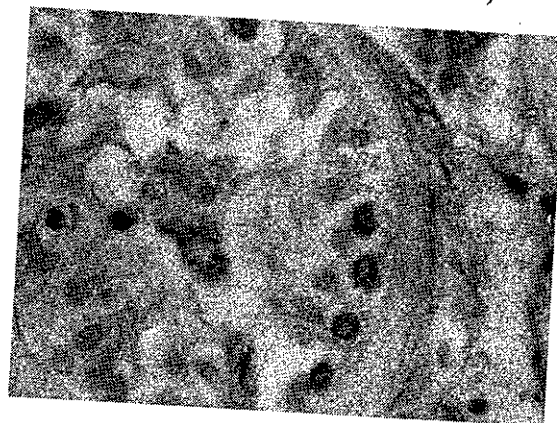
(Fig .29) Section in testicular tissue group III  
Shows nucleic acid contents distribution  
( Methyl green pyronin stain X 450)



(Fig .30) Section in testicular tissue group IVb  
Shows nucleic acid contents distribution  
( Methyl green pyronin stain X 450)



(Fig .31) Section in testicular tissue group IVc  
Shows nucleic acid contents distribution  
( Methyl green pyronin stain X 450)



(Fig .32) Section in testicular tissue group IVd  
Shows nucleic acid contents distribution  
( Methyl green pyronin stain X 450)

## Discussion

The outcome of ICSI using non-ejaculated sperm may be influenced by various factors, including the aetiology of azoospermia and the surgically retrieved sperm source, sperm status being fresh or after cryopreservation, thawing and factors related to the female partner such as age and ovarian reserve. Craft *et al*, (2001)

The aim of this study was to evaluate the morphological, histochemical changes of the testicular tissues in cases of azoospermic patients with primary infertility. The samples of this study were obtained by open biopsy. The amount of tissue was sufficient to allow reliable diagnosis and to give enough spermatozoa for ICSI.

Morphological changes were studied in cases of infertile in comparison to fertile men Holstein (1999).

The peritubular wall was formed of concentric layers of collagenous fibers without thickening. The seminiferous epithelium is composed of Sertoli cells and developing germ cells in average layers with normal activity, these findings were supported by good active primary spermatocyte and good number of sperms.

The sertoli cells showed intended triplet nucleus, the cytoplasm shows fine filaments, few lipid droplets no degenerative changes were observed.

Pierre (1991) stated that the normal sertoli cells are essential to participate with myoid cells in the formation of normal peritubular wall through paracrine interaction.

The peritubular wall of obstructive azoospermic cases in the present study showed mild thickening and a degree of infolding in seminiferous tubules. Similar results were obtained by Kiernan (1999). In contrary to this, Chan *et al*, (2003) and Roux *et al*, (2003) did not reported pathological changes in the tubular wall in such cases.

In this study, Sertoli cells showed cytoplasmic numerous lipid droplets, phagolysosomes and mild vacuoles. The spermatids also show some malorientation. Similar results were recorded by Kiernan (1999) and Elftman (1963)

On the other hand Chan *et al*, (2003) Mallidis. (2003) Roux *et al*, (2003) found no pathological changes in cases of obstructive azoospermia

In cases of non obstructive azoospermia positive for sperms the tubules appeared irregular with marked infolding and thickness in its basal lamina due to collagen deposition. A marked thickness of the intertubular tissue with developed Leydig cells. The same results were obtained by and Schlegel and Su. (1997) who observed decreased spermatogenic cell layers with tubular infolding especially in testicular biopsy of non obstructive azoospermic cases.

Also Slatopolsky, (1924) stated that whatever the cause of damage was necrobiotic changes begin first in the spermatids, spermatocytes, spermatogonia and finally Sertoli cells. These results are matched with Olesen, (1948) work on human material where he found Sertoli cells are the most resistant then resting spermatogonia.

Sperm counts vary from a case to another but lumen of the was empty of sperm. A possible explanation for the reduced sperm recovery in this study in different cases may be related to the testicular region selected for biopsy. Foresta *et al*. (1998)

In cases of non obstructive azoospermia with primary spermatocyte arrest, the peritubular wall was thickened with marked infolding and the intertubular tissue shows marked fibrosis and congested blood vessels with atrophic Leydig cells. Germ cells appear normal with reduction of its number of cell layers Paniagua *et al*, (1985)

In cases of Sertoli cell only syndrome (SCOS) it was noticed that peritubular wall was thick with increased amount of collagen and occluded lumen and multinucleated giant cells, treatment of such cases using testosterone may be the cause of these changes. These results are in contrary to the findings of Chan *et al*, (2003) who reported normal thickness of the peritubular wall.

The present study showed premature sloughing of germ cells (spermatocyte and

spermatid) which may be due to disturbed Sertoli-germ cell junction complexes. The same findings were reported by Roux *et al.* (2003).

In cases of hypoplasia of testicular tissues; the tubules were small in size, irregular shape, marked infolding with obliterated lumen. The same results were reported by Hadziiselimovic *et al.* (1984).

In positive non obstructive azoospermic cases there was marked decrease of number of spermatogenic cell layers, Active primary spermatocytes with little number of sperms. The interstitial tissue was thick, congested blood vessels.

In negative non obstructive azoospermic cases the primary spermatocytes was in prophase stage but with marked reduction of spermatogenic cells. In the some cases only sertoli cells were seen with no evidence of germ cells. All cases have very thick wall and interstitial fibrosis with no Leydig cells. The same data was also observed by Nogueira *et al.* (1999)

The mentioned changes shows that the thickness of the peritubular wall and degenerative changes in different azoospermic cases may be attributed to be the basic pathological changes or strongly may be due to unplanned or ignore use of hormonal treatment mainly testosterone Sasaki *et al.* (2003).

The presence of both spermatogonia cells and primary spermatocytes in all groups of non obstructive azoospermia negative cases even if in few number or degenerative state give us a hope to treat these cases by understanding its molecular biological bases and know more about the nature of these cells.

#### Histochemical changes:-

Changes in the nucleic acid content, in the control group showed increased content of DNA in the nuclei of both the spermatogonia and the dividing primary spermatocytes and sperm heads.

The estimated values of nucleic acid content showed significant decrease in nucleic acid contents in both group II and group III. Also there are a mild significant decrease in nucleic acid contents in subgroup IVa but a marked significant decrease nucleic acid contents in subgroup IVb, IVc and IVd. Same results observed by Jagor (1990).

Changes in the mucopolysaccharides (MPS) The study showed no significant

difference between the control group and group II, group III but there was Significant decrease in the PAS positive material in all subgroup of group IV especially Subgroup IVa (arrested spermatogenic activity) due to increase primary spermatocyte activity compensate the cellular degenerations.

These results were supported by Zaneveld. (1996) who demonstrated that the impaired membranous function is associated with the immotile sperm and also by Fabbrini, (1969) who found that in the adult rat testis, there was a moderate PAS reaction at the basement membrane of seminiferous tubules.

Also Fabbrini, (1969) showed that the PAS positive material which was found in the human testis is mainly glycogen. This material is distributed mainly in Sertoli cells and some spermatogonia, while spermatocytes are completely PAS negative. This contrast in distribution may be due to species difference. This evaluation needs study of metabolic pathway and its relation with this membrane.

#### References

- 1- Amelar, R.D. and Dubin, L. (1973): Male infertility: current diagnosis and treatment. Urology, 1, 1.
- 2- Bedford, J.M.(1976): Adaptations of the male reproductive tract and the fate of spermatozoa following vasectomy in the Rabbit, Rhesus monkey, Hamster a Reprod.,14:118-142.
- 3- Charny, C.W. (1940) :Testicular biopsy: its value in male sterility. J. Am. Med. Assoc., 115:1429-1433.
- 4- Charny, C.W. and Meranze, R.D. (1942): Testicular biopsy. Further studies in male infertility. Surg. Gynecol. Obstet., 74: 836-842.
- 5- Chan PT, Palermo GD, Veeck LL, Rosenwaks Z, Schlegel PN (2003): Testicular sperm extraction combined with intracytoplasmic sperm injection in the treatment of men with persistent azoospermia postchemotherapy Cancer., 92: 1632-1637.
- 6- Craft I, Tsirigotis M, Bennett V, et al (2001): Percutaneous epididymal sperm aspiration and intracytoplasmic sperm injection in the management of infertility due to obstructive azoospermia. Fertil Steril., 63:1038-1042.
- 7- Chemes, H.E., Dym, M., Fawcett, D.W. et al. (1977): Pathophysiological observa-

- tions of Sertoli cells in patients with germinal aplasia or severe germ cell depletion. Ultrastructural findings and hormone levels. *Biol. Reprod.*, 17:108-123.
- 8- Clermont, Y. (1963) : The cycle of the seminiferous epithelium in man. *Am. J. Anat.*, 112: 35- 43.
- 9- Craft, I., Bennett, V. and Nicholson, N. (1993): Fertilising ability of testicular spermatozoa. *Lancet*, 342: 864.
- 10- Devroey, P., Liu, J., Nagy, Z. et al. (1994): Normal fertilization of Human oocytes after testicular sperm extraction and intracytoplasmic sperm injection. *Fertil. Steril.*, 62:639-641.
- 11-Devroey, P., Liu, J., Nagy, Z. et al. (1995): Pregnancies after testicular sperm extraction and intracytoplasmic sperm injection in non-obstructive azoospermia. *Hum. Reprod.*, 10: 1457-1460.
- 12- Drury RA and Wallington EA (1980): Carleton's Histological Technique (5th ed) Oxford University, Press London, New York.
- 13- Dubin, L. and Hotchkiss, R.S. (1969): Testis biopsy in subfertile men with varicocele. *Fertil. Steril.*, 20: 50-67.
- 14- Elftman H (1963): Sertoli cells and testis structure. *Am J. Anta.* 113:25-33
- 15- Fabbrini, A. and Conti, C (1969): Glycogen in the normal human testis: A histochemical and histoenzymatic study. *J. Endocrinol.*, 43: 499-506.
- 16- Foresta, C., Garolla, A., Ferlin, A. et al. (1998): Doppler ultrasound of the testis in azoospermic subjects as a parameter of testicular function. *Hum. Reprod.*, 13: 3090-3093.
- 17- Hadziiselimovic F. Da Funga D. Leibungut B (1984): "Varicocele and infertility". *Diag Fed Urol.*, 7:85-92.
- 18- Harrington, T.G., Schauer, D. and Gilbert, B.R. (1996): Percutaneous testis psy: an alternative to open testicular biopsy in the evaluation of the sub fertile man. *J. Urol.*, 156:1647-1651
- 19- Holstein AF: Spermatogenesis: *Ann Anat* (1999), 181:427-436.
- 20- Huhner, M. (1913): Sterility in the Male and Female and its Treatment. Rebman Comp., New York.
- 21- Huhner, M. (1928): Aspiration of the testicle in the diagnosis and prognosis of sterility. *J. Urol.*, 19: 31-41.
- 22- Jagor S (1990): Sperm nuclear stability and male infertility. *Arch.of Andrology*, 25 :235.
- 23-Johannisson R, Schulze W, Holstein AF (2003): Megalospermatoocytes in the human testis exhibit asynapsis of chromosomes. *Andrologia*, 35:146-151.
- 24- Kahraman S, and Samli M (2001): Multiple pregnancies obtained by testicular spermatid injection in combination with intracytoplasmic sperm injection. *Hum Reprod.*, 13:104-110.
- 25- Kiernan J A (1999): Histological and Histochemical Methods Theory and practice (3rd ed).Arnold, London New York and New Delhi.
- 26- Mallidis, C (2003): Necrospemia and chronic spinal cord injury. *Fertil Steril.*, 74:221-7.
- 27- Nistal, M. and Paniagua, R. (eds) (1984): Testicular and Epididymal Pathology. Thieme-Stratton Inc., New York.
- 28- Nogueira, D. C. Bourgain, G. Verheyen and A.C. Van Steirteghem (1999): Light and electron microscopic analysis of human testicular spermatozoa and spermatids from frozen and thawed testicular biopsies *Human Reproduction*, 14 :2041-2049.
- 29- Olesen, H. (1948): The histological changes produced in the rat testis by temporary and Permanent occlusion of the testicular artery. *J.Path & Bact*, 64: 273-297.
- 30- Palermo, G., Joris, H., Devroey, P. et al. (1992): Pregnancies after intracytoplasmic sperm injection of single spermatozoon into an oocyte. *Lancet*, 340:17-18.
- 31- Paniagua R. Amat R, Nistale M, Martin A (1985): "Ultrastructural changes in Sertoli cells in aging humans". *Internal Androl.*, 8:295-312.
- 32- Ragab, A.F., Tarkhan, A.A., Etribi, A. et al. (1961): Testicular biopsy In azoospermia. *Int. J. Fertil.*, 6: 303.
- 33- Roux N, Young J, Misrahi M, Schaison G, Milgrom E (2003): Loss of function mutations of the Gn-RH receptor: a new cause of hypogonadotropic hypogonadism. *J Pediatr Endocrinol Metab.*, 12:267-75.
- 34- Sasaki, G., Nakagawa, K., Hashiguchi, A., and Murai, M.(2003): Giant seminoma in a patient with 5a-reductase type 2 deficiency. *J Urol* 169:1080-1081.
- 35- Schlegel, P.N. and Su, L. (1997): Physiological consequences of testicular sperm extraction. *Hum. Reprod.*, 12: 1688-1692.
- 36- Schoysman, R., Vanderzwalm, P., Nijs, B. et al. (1993)Pregnancy after fertilization with human testicular spermatozoa. *Lancet*, 342: 1237-1249.
- 37-Seo JT, KO WJ (2001): Predictive factors of successful testicular sperm recovery in non-obstructive azoospermia patients. *Int J Andr.*, 24(5):306-10.
- 38- Van Steirteghem, A., Nagy, Z., Joris, H. et al. (1993): High fertilization and implantation rate after intracytoplasmic sperm injection. *Hum. Reprod.*, 8:1061-1066.
- 39-Zaneveld LJD (1996): Sperm Functions and its evaluation. In male infertility. Cornhaire Fh. (ed.) Chapman and Hall, London P.185.

# دراسة هستوكيميائية لأنسجة الخصية المستخدمة في حالات الإخصاب المجهرى.

أشرف محمود مصطفى - محمد إسامة خاطر - مصطفى إسماعيل حسن

عز الدين الشرقاوى - تيمور خليفة التونسى

أقسام الهستولوجى و الجلدية والتناسلية- كلية الطب - جامعة الأزهر

إن التقدم الملحوظ فى تقنيات الأخصاب المساعد زاد من احتمالات النجاح فى علاج حالات العقم فى الإنسان لذلك شمل هذا البحث عينات صالحة للأخصاب المجهرى تم تدعيمها بالفحص الميكروسكوبى الهستوكيميائى. تم استخدام مائة حالة من عينات الخصية البشرية من المركز الإسلامى للتكاثر وقسم المسالك البولية بمستشفى الحسين الجامعى وذلك بعد أخذ موافقة المرضى قبل الحصول على العينات وقد قسمت الحالات على النحو التالى:-

## 1-المجموعة الأولى ( المجموعة الضابطة).

تحتوى هذه المجموعة على خمس حالات لأشخاص طبيعيين قادرين على الأنجاب طبقا لتحليل السائل المنوى. أما بالنسبة لباقي العينات من الرجال الذين يعانون من عقم أولى ناتج من عدم وجود حيوانات منوية فى السائل المنوى تم تقسيمهم إلى :

## 2-المجموعة الثانية (حالات بها إنسداد بالأنبوب المنوى) واشتملت على خمس وثلاثون حالة.

## 3-المجموعة الثالثة (حالات ليس بها إنسداد بالأنبوب المنوى وموجبة للحيوانات المنوية) واشتملت على عشرون حالة.

## 4-المجموعة الرابعة (حالات ليس بها إنسداد بالأنبوب المنوى وسالبة للحيوانات المنوية) وتكونت من اربعون حالة وقسمت إلى:-

### أ- حالات تميزت بحجم طبيعى للخصية (ثلاثون حالة) تم تقسيمها على النحو التالى:-

المجموعة الرابعة (أ)- حالات بها توقف إنقسامى للمكونات المنوية فى مرحلة الجاميت الأولى.

المجموعة الرابعة (ب)- حالات ملتزمة خلايا سرتولى فقط ولا أثر لوجود خلايا جرثومية .

المجموعة الرابعة (ج)-حالات من النوعين أ & ب من المجموعة الرابعة

ب - حالات بها ضمور فى حجم الخصية وتكونت من عشر حالات وتمثل المجموعة الرابعة (د)

وقد تم تحضير عينات شمعية تمهيدا لفحصها هستولوجيا، هستوكيميائيا .

وقد تم استخدام جهاز (Image analyzer) للتحليل الكمي للنتائج وتحليلها إحصائيا .

وقد دلت النتائج على ما يلى:-

### التغيرات التركيبية :-

فى مجموعة الإنسداد الأنبوبى دلت النتائج على أنه لا يوجد إختلافات كثيرة عن المجموعة الضابطة من حيث عدد الخلايا الجرثومية وترتيبها ونشاطها فى حين ظهر بعض الاحتقان فى الأوعية الدموية. كما أوضحت الدراسة زيادة فى سمك الصفيحة القاعدية وفقد بعض الأنابيب المنوية لأستدارتها الطبيعية .



وفى المجموعة الثالثة أظهرت الدراسة أن تركيب الأنابيب المنوية وجد أنها قد تكون مماثلة لما سبق. كما لوحظ إزداد فى سمك الصفيحة القاعدية وكذلك زيادة فى سمك جدار الأوعية الدموية واحتقانها بجانب تليفات مع قلة فى عدد خلايا ليدج. ودلت النتائج فى المجموعة الرابعة والتي شملت عينات ليس بها إنسداد أنبوى وسالبة للحيوانات المنوية دلت النتائج على ما يلى:-

أولا المجموعة الرابعة (أ) الحالات التى بها توقف إنقسامى للمكونات المنوية فى مرحلة الجاميت الأولى وحجم الخصية طبيعى وقد تبين من الفحص:-

حجم الأنابيب المنوية قد يكون قريب من الطبيعى ولكن يوجد ضمور واضح فى بعضها الآخر مع نقص كبير فى عدد طبقات الخلايا الجرثومية مع إختلال ترتيبها الطبيعى أما الخلايا الإبتدائية فهى خلايا نشطة فى حالة إنقسام ولكنها قليلة العدد. بجانب أنه لا أثر لأرومة النطفة (spermatid) أو الحيوانات المنوية. وقد لوحظ إزداد سمك الصفيحة القاعدية وإختفاء تجويف الأنابيب مع إزداد تليف النسيج البينى وقلة واضحة فى خلايا ليدج مع وجود زيادة فى سمك واضح فى الأوعية الدموية واحتقان

ثانيا المجموعة الرابعة (ب) وشملت الحالات الخاصة بملتزمة خلايا سرتولى فقط حيث لاوجود لخلايا جرثومية فى حين أن حجم الخصية طبيعى تبين من الفحص أن حجم الأنابيب المنوية متوسط أو صغير مع عدم وجود لطبقات الخلايا الجرثومية و كل الأنابيب فيها عبارة عن خلايا سرتولى فقط كما تبين إزداد سمك الصفيحة القاعدية والمكونة من عدة طبقات وإختفاء تجويف الأنابيب

ثالثا المجموعة الرابعة (ج) وهى الحالات المشتركة بين المجموعتين (أ & ب).

رابعا المجموعة الرابعة (د) لوحظ ضمور واضح فى حجم الخصية وأنعكس ذلك على ترتيبها الخلوى بحيث ظهرت كلها عبارة عن أنابيب صغيرة جدا متليفة ليس بها تجويف والصفيحة القاعدية أكثر سمكا عن كل المجموعات السابقة ولا أثر لأى خلايا .

### 1-التغيرات الهستوكيميائية الكمية:-

أ-التغيرات فى محتوى السكريات المتعددة المخاطية (Mucopolysaccharides)

لوحظ عدم وجود تغير فى تركيز مادة البيرايوديك أسيد شيف بين المجموعتين الثانية والثالثة بعد مقارنتها بالمجموعة الأولى . كما وجد تغير ملحوظ فى تركيز هذه الماده بين المجموعة الرابعة مقارنة بالمجموعة الأولى وخاصة فى الحالات التى بها توقف إنقسامى للمكونات المنوية فى مرحلة الجاميت الأولى.

ب-التغيرات فى محتوى الحامض النووى: لوحظ وجود تغير فى محتوى الحامض النووى فى المجموعتين الثانية والثالثة مقارنة بالمجموعة الأولى. وكذلك

وجود تغير ملحوظ فى تركيز محتوى الحامض النووى فى المجموعة الرابعة (أ) وزاد مقدار التغير بنسبة كبيرة فى المجموعات الفرعية (ب & ج & د) مقارنة بالمجموعة الأولى.

وفى النهاية يتضح من هذه النتائج مدى أهمية الدراسة التركيبية وكذلك الهستوكيميائية كجزء مكمل لتقييم حالات العقم عند الرجال. ولتابعة الدراسات المستقبلية يجب الأخذ فى الاعتبار استكمال الدراسة الهستوكيميائية بعد تقييم بعض الإنزيمات الأخرى بجانب الدراسة المناعية الهستوكيميائية لخلايا أنابيب الخصية. وتوصى هذه الدراسة بأن تكون الدراسة النسيجية جنبا إلى جنب مع التقييم العلاجى لمرضى حالات العقم.