

Therapeutic Efficacy of Conventional Treatment Combined with Manuka Honey in the Treatment of Patients with Diabetic Foot Ulcers: A Randomized Controlled Study

Mohamed Al Saeed

Department of Surgery, Taif University and Head of Surgical Department of King Abdul Aziz Specialist Hospital, Taif, Saudi Arabia, Email:ms_alsaeed@yahoo.com

Abstract

Background and aim of the work: Foot ulcers are a major problem of diabetes for which conventional treatment modalities alone have had limited success in promoting complete wound closure; however, there are large amounts of evidences that exist for the effectiveness of manuka honey as a wound dressing especially in diabetic foot. The aim of this study was to compare the efficacy of Manuka honey combined with conventional modalities to that of conventional treatment alone in the treatment of diabetic foot ulcers.

Patients and Methods: This was a prospective double-blind, randomized clinical trial conducted at the King Abdul Aziz Specialist Hospital in Taif, Saudi Arabia. Fifty-nine patients, enrolled from January 2011 to January 2013, were randomized to receive conventional treatment plus manuka honey impregnated dressings (honey treatment group) or conventional treatment alone (control group). Outcomes were; time to eradicate infection, length of hospital stay, percentage of completely healed ulcers after six weeks and six months.

Results: The mean time to eradicate infection and the hospital stay were significantly reduced in the honey treatment group compared to control group (51.1% and 53.8% respectively, $P < 0.05$). Percentages of ulcers that were completely healed were significantly greater in the honey group than the control group, at six weeks (61.3% vs. 11.5%; $P < 0.05$) and at six months (87.1% vs. 42.3%; $P < 0.05$). There were less toe amputations in the honey-treated group (9.7% vs. 34.6%; $P < 0.05$).

Conclusion: Combination of conventional treatment with manuka honey impregnated dressings is superior to conventional treatment alone in controlling wound infection, promoting the complete healing of diabetic foot ulcers, and decreasing the rate of minor amputations.

Keywords: Manuka, honey, Diabetic foot, Taif, Saudi Arabia.

Introduction

Diabetes affects about 30% of the population of the Kingdom of Saudi Arabia and its complications, if uncontrolled, can be very serious (1, 2). The global lifetime risk of foot ulcers for patients with diabetes (type 1 or 2) may be as high as 25% and due to cultural, social, educational, and climate factors, the incidence of diabetic foot ulcers is estimated to be higher in the KSA, however, the actual burden is not exactly known (3). In high altitude regions like Taif, the challenge is compounded by hypobaric hypoxia and polycythemia with possible increased risk of vascular occlusion (4, 5). Moreover, in rural areas, patients usually present in advanced stages, and prefer to treat foot ulcers with natural products which actually useful if used properly by medical professional (6).

Medicated honey preparations, especially, manuka honey are increasingly being used as a wound dressing in light of evidence suggesting that it provides a moist wound environment with potent anti-

inflammatory, immunomodulatory, and antibacterial properties (7-9). Manuka honey also contains phenolic derivatives of benzoic acids, cinnamic acids and flavonoids, which are the same as those found in propolis with its known antimicrobial activity (7). Honey enhances wound healing by accelerating slough separation, promoting the growth of granulation tissues, and stimulating epithelialization (10). Therefore, the aim of this study was to compare the efficacy of manuka honey combined with conventional modalities to that of conventional treatment alone in the treatment of diabetic foot ulcers.

Patients and methods: This prospective double-blind, randomized clinical trial was performed at the King Abdul Aziz Specialist Hospital, Taif, Saudi Arabia. The study was approved by the ethical committee of the hospital. Adult patients of both sexes with a diagnosis of diabetic foot ulcers with a Wagner classification of stage two, three, or four were enrolled from January 2011 to January 2013.

Written informed consent was obtained from all participants.

Patients with critical limb ischemia were excluded from the study. Patients were also excluded if they were suffering from liver or kidney failure; receiving chemotherapy, radiotherapy, or immunosuppressant drugs; or participating in another clinical trial.

Eligible patients were randomized to one of two groups with similar distributions of sex, age, and Wagner stage: honey treatment group (manuka honey combined with conventional treatment) or control group (conventional treatment alone). All patients were treated in the hospital until their wounds became aseptic with good granulation tissue, after which they completed their treatment as outpatients.

During conventional treatment (10, 11), glucose control was considered optimal if hemoglobin A1C was 7-8% (so as to avoid the hazards of hypoglycemia). Patients were advised to stop smoking, received anti-platelet agents in addition to control of diet, hypertension, and hyperlipidemia. The protocol involved regular clinical and complete laboratory assessment including the vascular laboratory tools in addition to plain x-rays to detect any bone affection with management of any detected abnormality. Culture swabs were done weekly till infection was eradicated and systemic antibiotics were given according to the microbe present with drainage of any collection and surgical debridement of hyperkeratotic and necrotic tissues. Off-loading was applied to reduce pressure. Ulcers were monitored for the formation of healthy uninfected granulation tissues and the decrease in size using planimetry (acetate plate) and digital photography.

Ulcers were washed with povidone iodine or, if the patient developed an allergy to iodine, with EUSOL, and irrigated with normal saline.

In the control group, the ulcers were covered with a tulle grass and adsorbent dressing.

In the honey treatment group, manuka honey impregnated dressing containing 35g of UMF 13 (Unique Manuka Factor) was applied.

In both groups, an occlusive secondary dressing was applied, and changed daily or more frequently if the dressing was markedly soaked.

Statistical analysis: Results are expressed as mean \pm standard deviation. Analyses were performed using SPSS version 15. Non-parametric tests were used if the distribution did not satisfy the parametric assumptions. $P < 0.05$ was considered significant.

Results: A total of 59 patients participated in the study. The protocol was strictly followed throughout the study. Thirty-two patients were randomized to manuka honey plus conventional treatment (honey treatment group), and 27 patients to conventional treatment alone (control group). Two patients withdrew during the course of the study; one in the control group required urgent coronary bypass surgery and one in the treatment group withdrew for personal reasons. Demographic and other patient characteristics of the 57 patients who completed the study are shown in Table 1, which shows no significant differences between both groups. The distribution of patients according to the Wagner grade of the foot ulcer is shown in figure 1. The time required to eradicate the infection and the length of the hospital stay were significantly reduced in the honey treatment group versus the control group (figure 2; $P < 0.05$). At the six-week and six-month follow-ups, the percentages of wounds that were completely healed were significantly higher in the honey treatment group compared with the control group (figure 3; $P < 0.05$). Progress and healing of ulcers are shown in figures; 4-6. No major amputations were performed in either group; however, three toe amputations were performed in the honey treatment group versus nine in the control group (9.7% vs. 34.6%; $P < 0.05$). There were no deaths in either group during the follow up period.

Discussion

Foot ulcers are one of the most common complications of diabetes; the prevalence of foot ulcers among hospitalized patients with diabetes in Saudi Arabia is not exactly known; however, it ranges between 2.7% in the United States to 20% in Iran (2, 3). Conventional treatment modalities promote complete wound closure with limited success. Consequently, many protocols have been designed to improve the outcome of these treatment modalities, including hyperbaric oxygen, ozone therapy, extracorporeal shock wave therapy (ESWT), and sustained silver-releasing foam dressings, in addition of the rapidly increasing

interest in the use of honey as a wound dressing (12-16). Although honey is an ancient treatment, evidence to support its use in wound care is relatively recent (7).

In adherence to published wound care protocols (8, 10, 11, 16), the primary dressing in the present study was soaked in manuka honey and covered with an occlusive secondary one to minimize the progressive diluting effect by the exudate. The hygroscopic effect of honey facilitates slough separation, which accelerates wound debridement. We also observed that impregnated honey dressings required less frequent changing in contrast to the control group which is consistent with previous studies (8, 10), which verified that the anti-inflammatory activity of the honey would reduce the amount of exudate decreasing the need for frequent dressing changes but not to the degree to prevent the formation of the beneficial moist environment with non adherent interface.

The antibacterial potency of honey is partially dependent on the osmolarity created by its sugar content and on the slow release of hydrogen peroxide produced when honey is diluted (7). This antimicrobial action of manuka honey is enhanced by its ability to inhibit tissue catalases that metabolize hydrogen peroxide (7, 18). However, honey contains another factor (the phytochemical factor) which gives a more potent antibacterial action that diffuses into the depth of infected tissues (7, 9, 18). The highest activities of these phytochemical factors with broad spectrum antimicrobial effect are found in the manuka honey and these activities are rated as the Unique Manuka Factor (UMF) number on the medicated honey preparations (8). In addition to the direct antibacterial effect of honey, it has an enhancing effect on the body immunity (19).

In the present study, manuka honey impregnated dressings combined with conventional treatment significantly reduced the time to eradicate infection and the length of hospital stay compared to conventional treatment alone. Gethin and Cowman (19), in their case series of use of manuka honey in leg ulceration reported results which were in agreement of our findings. Similarly, Hammouri (10), noted that gauze saturated with Jordanian natural honey lowered time to eradicate infection and length of hospital stay by 34% and 43% respectively. Supporting

findings were also obtained by Lusby et al. (18), in their study about bactericidal activity of different honeys against pathogenic bacteria and by Bakhotmah and Alzahrani (16), in their report about the use of natural preparations in treating diabetic foot disorders in Western province of Saudi Arabia.

Many authors reported the role of honey in the stimulation of cytokine production by monocytes and other cells initiating the tissue repair and helps the growth of granulation tissue and epithelial tissue so that healing is hastened (7, 8, 19). In the present study complete healing after six weeks was achieved in 61.3% of the honey group which is significantly much higher than the control group where the complete healing was detected only in 11.5%. After six months complete healing was detected in 87.1% of the honey group vs. 42.3% of the control group and this significant difference reflects the superiority of addition of manuka honey to the conventional treatment. Similar results were reported by Kamaratos *et al.* (20), with slightly higher rate of complete healing and this difference can be explained if we take in consideration that his study was conducted only on patients with neuropathic diabetic foot ulcers and our study involved also ulcers in patients with mild ischemia. Similar results are reported by many authors in the literature (7, 8, 16, 18, 19). In this study it was recorded that no major amputations were done in both groups; however, amputations of toes were significantly reduced in the honey treatment group than the control group, a finding which was in agreement with that reported in other studies (10, 20, 21).

Conclusion

Combination of conventional treatment with manuka honey-impregnated dressings is superior to conventional treatment alone in controlling wound infection, promoting the complete healing of diabetic foot ulcers, and decreasing the rate of minor amputations.

Competing Interests: The author declares no competing interests.

Author contributions

Dr Mohamed Al Saeed: Treating physician supervised the cases and wrote the paper.

References:

1. Alqurashi KA, AljabriKS, Bokhari SA (2011). Prevalence of diabetes mellitus in a

1. Saudi community. *Ann Saudi Med.*,31:19–23.
2. **Jeffcoate WJ, Harding KG (2003).** Diabetic foot ulcers. *Lancet*;361:1545–51.
3. **Elhadad TA, Al-Amoudi AA, Alzahrani AS (2007).** Epidemiology, Clinical and Complications Profile of Diabetes in Saudi Arabia: A Review. *Ann Saudi Med.*,4:241-50.
4. **Van Veen JJ, Makris M(2008).** Altitude and coagulation activation: does going high provoke thrombosis? *ActaHaematol.*,119:156-7.
5. **Gupta N, Ashraf MZ (2012).** Exposure to high altitude: a risk factor for venous thromboembolism?. *SeminThrombHemost.*,38:156-63.
6. **Alzahrani HA, Bakhotmah BA, Boukraâ L (2011).** *In Vitro* Susceptibility of Diabetic Wound Bacteria to Mixtures of Honey, *Commiphora molmol* and *Nigella sativa*. *Open Nutraceuticals J.*,4: 172-5.
7. **Molan PC (1999).** The role of honey in the management of wounds. *J Wound Care*, 8: 415-8.
8. **Molan PC (2006).** The evidence supporting the use of honey as a wound dressing. *Int J Low Extrem Wounds*,5:40–54.
9. **Kingsley A (2005).** Practical use of modern honey dressings in chronic wounds. In: White R, Cooper R, Molan P, editors. *Honey: A modern wound management product*. Aberdeen, UK: Wounds UK Publishing, 54-78.
10. **Hammouri S K (2004).** The Role of Honey in the Management of Diabetic Foot Ulcer. *JRMS.*,11:20-2.
11. **Eddy JJ, Gideonsen MD (2005).** Topical honey for diabetic foot ulcers. *J Fam Pract.*, 54: 533–5.
12. **Al-Waili NS, Butler GJ (2006).** Effects of hyperbaric oxygen on inflammatory response to wound and trauma: possible mechanism of action. *Sci World J.*, 6: 425–41.
13. **Martínez-Sánchez G, Al-Dalain SM, Menéndez S, Re L, Giuliani A, Candelario-Jalil E, et al (2005).** Therapeutic efficacy of ozone in patients with diabetic foot. *Eur J Pharmacol.*,523:151-61.
14. **Wang CJ, Kuo YR, Wu RW, Liu RT, Hsu CS, Wang FS (2009).** Extracorporeal shockwave treatment for chronic diabetic foot ulcers. *J Surg Res.*,152:96–103.
15. **Gottrup F, Cullen BM, Karlsmark T, Bischoff-Mikkelsen M, Nisbet L, Gibson MC (2013).** Randomized controlled trial on collagen/oxidized regenerated cellulose/silver treatment. *Wound Repair Regen.*,21: 216-25.
16. **Bakhotmah A, Alzahrani HA (2010).** Self-reported use of natural preparations in treating diabetic foot disorders by a cohort of Saudi diabetics in Jeddah, Western Saudi Arabia. *J ApiProduct and ApiMedical Sci.*,2:31–60.
17. **Ahmad A, Khan RA, Mesaik MA (2009).** Anti inflammatory effect of natural honey on bovine thrombin-induced oxidative burst in phagocytes. *Phytother Res.*,23:801-8.
18. **Lusby P E, Coombes A L, Wilkinson J M (2005).** Bactericidal activity of different honeys against pathogenic bacteria. *Archives of Medical Research.*, 36: 464–7.
19. **Gethin G, Cowman S (2005).** Case series of use of Manuka honey in leg ulceration. *Int Wound J.*,2:10-5.
20. **Kamaratos AV, Tzirogiannis KN, Iraklianos SA, Panoutsopoulos GI, Kanellos IE, Melidonis AI (2012).** Manuka honey-impregnated dressings in the treatment of neuropathic diabetic foot ulcers. *Int Wound J.* doi: 10.1111/j.1742-481X.2012.01082.
21. **Simon A, Traynor K, Santos K, Blaser G, Bode U, Molan P (2009).** Medical honey for wound care still the latest resort. *Evid Based Complement Alternat Med.*,6: 165–73.

Table 1:patient characteristics before starting therapy

	Group I (honey treatment)	Group II (control)	P value
Total number	31	26	
Sex: Number (%):			
Male	17 (54.8%)	14 (53.8%)	NS
Female	14 (45.2%)	12 (46.2%)	NS
Age: Mean \pm SD (years):			
Male	54.6 \pm 12.7	52.3 \pm 11.8	0.87 (NS)
Female	58.7 \pm 13.4	56.6 \pm 14.1	0.66 (NS)
Mean duration of diabetes (years)	16.5 \pm 3.4	17.2 \pm 4.1	0.89 (NS)
Control of diabetes:			
Oral hypoglycemic	17 (54.8%)	14 (53.8%)	0.73 (NS)
Insulin	10 (32.3%)	9 (34.7%)	0.69 (NS)
Dietary control	4 (12.9%)	3 (11.5%)	0.92 (NS)
Smokers	19 (61.3%)	16 (61.5)	0.77 (NS)
Neuropathy	25 (80.6%)	22 (84.6%)	0.82 (NS)
Mean ABPI	0.87 \pm 0.17	0.81 \pm 0.19	0.67 (NS)
Mean Hb A1 C percentage before treatment	10.7 \pm 2.4	11.1 \pm 2.6	0.64 (NS)

NS: not significant

Figure 1: Ulcer grades (Wagner's) in both groups

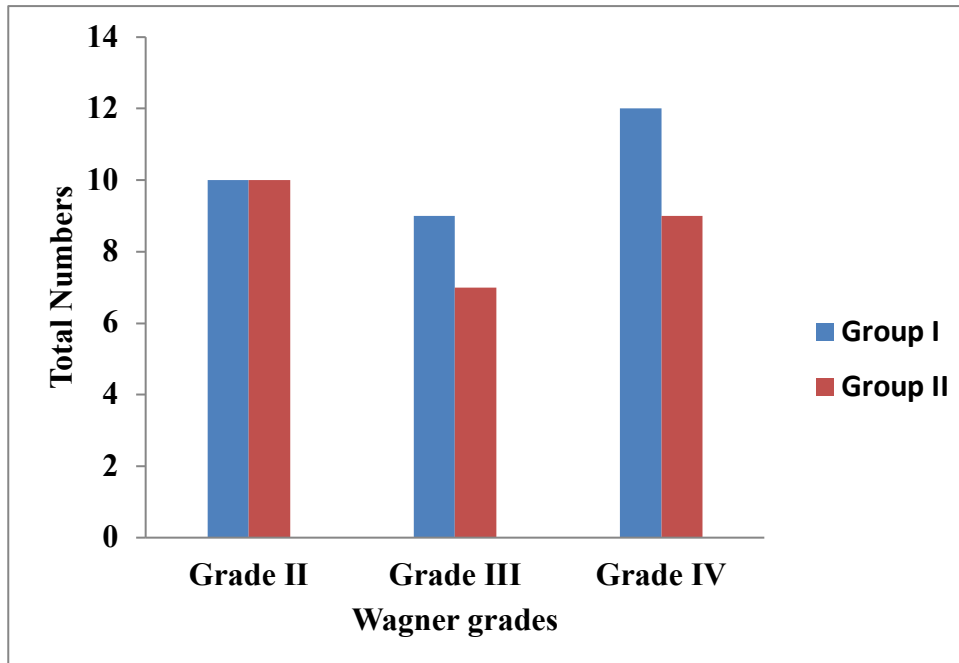


Figure 2: Time to eradicate infection and length of hospital stay in both groups

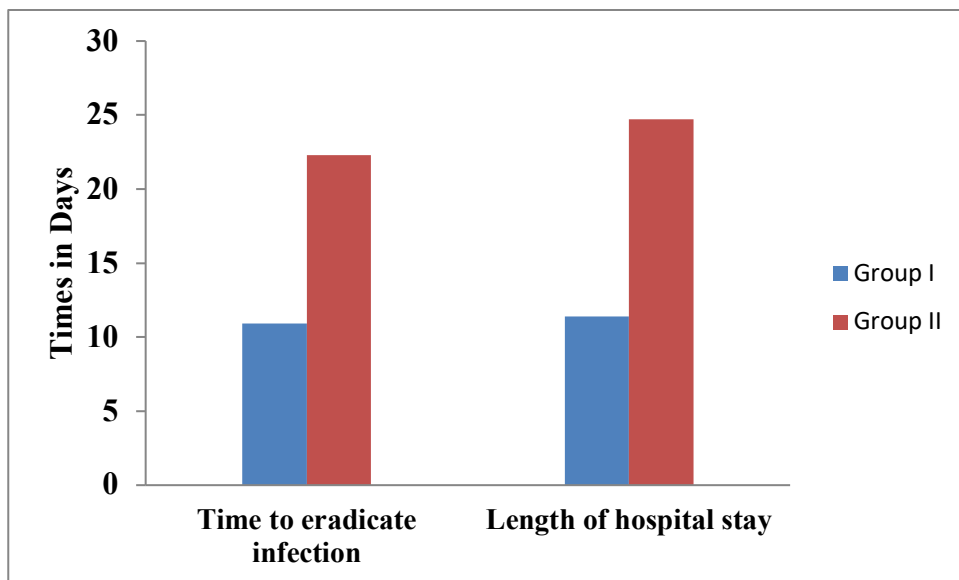


Figure 3:Percentage of complete healing after 6 weeks and 6 months in both groups

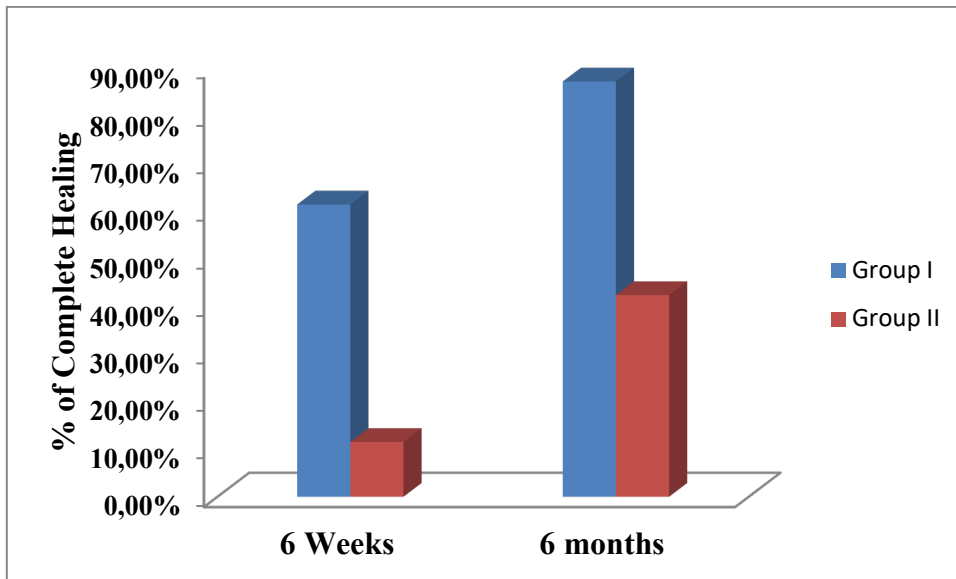


Figure 4: Progress of healing in diabetic ulcer affecting the heel in the honey group, A, Wagner grade III ulcer, B, 2 weeks after treatment, and C, 6 weeks after treatment.

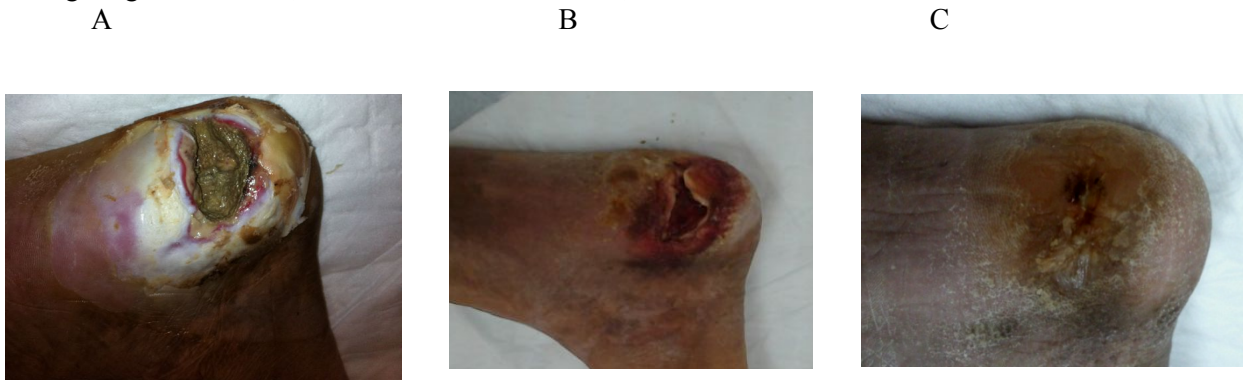

Figure 5: Healing of extensive ulceration the medial part of the sole of the right foot (Wagner, grade IV), one week, 4 weeks and 6 months after honey treatment of the medial part of the sole of the right foot.

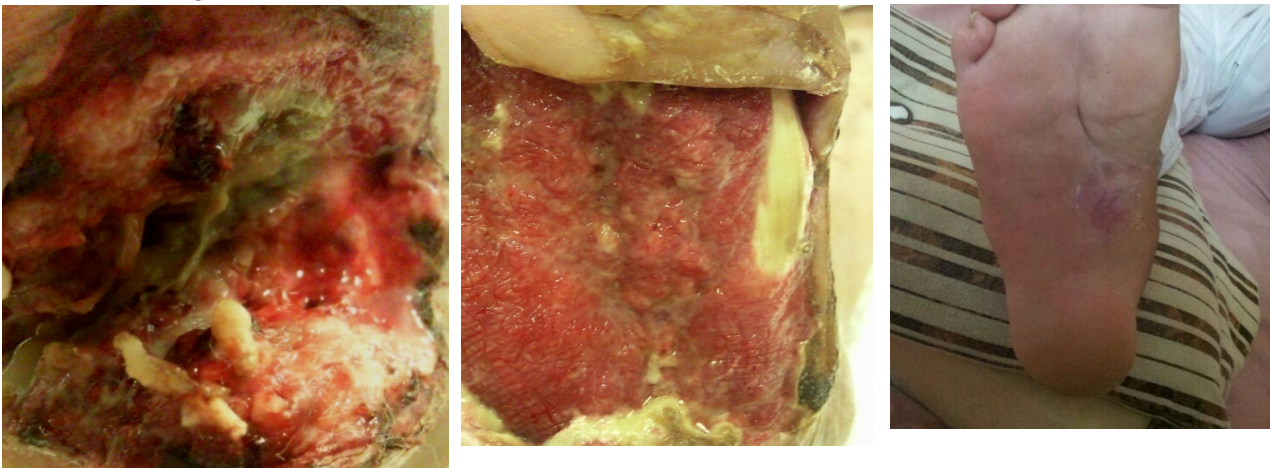


Figure 6: Complete healing of extensive ulceration (grade 4) of the sole of left foot 6 months after honey treatment.

