The Egyptian Journal of Hospital Medicine (October 2013) Vol. 53, Page 935– 946

Role of Diffusion MRI & Dynamic Contrast-enhanced MRI in Assessment of Hepatocellular Carcinoma after Trans-arterial Chemoembolization

Fatma S.El-dien Mohammed **, Hanaa Abd Elkader Abd Elhamed **, Yosra Abdelzaher Ibrahim **, Ali Haggag Ali Noreldien **

Radiodiagnosis Department, Faculty of Medicine, Ain Shams University, Cairo, Egypt

Abstract:**Purpose**: to assess the effectiveness of diffusion & Dynamic contrast enhanced MRI in imaging of hepatocellular carcinoma after chemoembolization.

Patients and Methods: between November 2011 & September 2013, 30 patients were treated with chemoembolization in our interventional radiology unit. All patients underwent pretreatment MRI within 10 days before chemoembolization & post-treatment MRI after one month from treatment. The arterial enhancement as well as the mean Apparent Diffusion Coefficient (ADC) of the focal lesion was prospectively assessed & the percent change in both was assessed. The significance of differences between ADC values of complete & partially responding lesions was calculated.

Results: Thirty male patients, ranging in age between 51 & 73 years who met the inclusion criteria were prospectively studied. According to the results of this study, there was a statistically significant difference between patients with partial response & those with complete response as regard the percent change in the mean ADC value of the focal lesion after treatment with P-value less than 0.001. There was significant positive correlation between the percent change in the mean ADC value & the percent change in the diameter of the enhancing tumor tissue after treatment. The percent change in the mean ADC value among patients with complete response was higher than that among patients with partial response with P-value less than 0.001. The best predictive cut off value for differentiation between complete & partial response was 24 % increase in the mean ADC value, with 99 % sensitivity, 84 % specificity, 90 % positive predictive value, 99 % negative predictive value & 86 % accuracy. The % change of the mean ADC value is considered better positive than negative predictor for response to treatment. On the otherhand, there was no statistically significant difference between patients with complete & partial response as regard the mean ADC of the focal lesion before chemoembolization.

Conclusion: After chemoembolization, completely responding HCC lesions exhibited more increases in the mean ADC than partially responding lesions. Pretreatment mean ADC values were not predictive of response to chemoembolization

Key words: Hepatocellular carcinoma, chemoembolization, diffusion, dynamic MRI.

Introduction

Hepatocellular carcinoma (HCC) is the fifth most common malignancy in the world **(14).** Transarterial chemoembolization (TACE) of hepatocellular carcinoma (HCC) is used in some cases as a bridge to liver transplantation. It is also used for patients with unresectable HCC, and has been shown to improve survival **(13).** Early assessment of the effectiveness of TACE is critical in planning future therapy **(5).** Assessment of tumor response after chemoembolization on CT is generally based on the radio-opacity of the iodized oil that selectively accumulates in the tumor in addition to tumor enhancement and tumor size on contrast enhanced CT. Iodized oil impairs the assessment of residual tumor enhancement on contrast enhanced CT **(25).**

In contrast to CT, the high concentration of iodized oil after chemoembolization does not affect MR signal intensity. Enhancing portions of the tumor are presumed to be viable, whereas non-enhancing portions are presumed to be necrotic. The disadvantage of contrast-enhanced MRI is the incapability to distinguish viable cells from reactive granulation tissue. **(25).**

Diffusion-weighted imaging (DWI), a functional MRI technique, detects MR signal changes in tissues due to water proton motion that varies based upon the degree of cell membrane integrity. The intact membranes of viable tumor cells restrict water diffusion, whereas necrotic tumor cells with disrupted cell membranes exhibit increased water diffusion. This mobility of water is quantified by a constant known as the apparent

DOI: 10.12816/0001656

diffusion coefficient (ADC) **(4).** Diffusion-weighted MRI (DWI) provides unique information related to tumor cellularity and the integrity of cell membranes and thus may be sensitive to changes in the tumor microenvironment that occur after treatment **(12).**

Patients & Methods:

Thirty patients were included in this prospective study. The study was performed between November 2011 & September 2013. Patients included in the study were all males, ranging in age between 51 & 73 years with a mean age of 58.2 years. They were Ain Shams University hospital patients. All patients were diagnosed as HCC patients based on typical enhancement pattern on triphasic CT scan. Patients with high serum creatinine (above 1.4 mg %), are excluded from this study, for fear of contrast induced nephrogenic systemic fibrosis. All thirty patients are prospectively studied. All thirty patients have undergone chemoembolization for 30 focal lesions. In patients with multiple HCC focal lesions the largest one was treated.

All patients were subjected to Complete liver profile, Abdominal MRI within 10 days before chemoembolization including pre- and post contrast dynamic MRI & diffusion-weighted imaging for 18 patients & diffusion-weighted imaging only for 12 patients in addition to Abdominal MRI one month after chemoembolization including pre- and post contrast dynamic MRI & diffusion-weighted imaging for all patients.

MRI imaging: A 1.5-T MR unit (Achieva; Philips Medical Systems, Best, the Netherlands) was used, using a phased array coil to cover the whole liver.

a) Pre-contrast imaging, with respiratory triggering included: T_1 weighted (T_1W) in & out of phase gradient echo sequence (GRE): repetition time (TR) = 10 ms, echo time (TE) = 4.6 ms, NEX (number of excitations) 2, flip angle 15°, matrix 150x236 with a field of view as small as possible, slice thickness 4 mm and slice gap 0.5 mm, T_1 weighted (T_1W) gradient echo sequence (GRE) with fat suppression (FS): repetition time (TR) = 100-200ms, echo time (TE) = 10 ms, NEX 1, flip angle 15°, matrix 150x236 with a field of view as small as possible, slice thickness 4 mm and-slice gap 0.5 mm & T_2 weighted (T_2W) images (fast spin echo sequence) (FS): TR = 2000ms, TE= 90-120 ms, NEX 3, matrix 150x236 with a field of view as small as possible, slice thickness 4 mm and slice gap 0.5 mm.

b) Dynamic study: Dynamic study was performed after bolus injection of 0.1mmol/kg body weight of Gd-DTPA at a rate of 2ml/s, flushed with 20ml of sterile 0.9 % saline solution from the antecubital vein. The injection of contrast media and saline solution was performed using pump injector. Breath-hold dynamic imaging using T1 weighted gradient echo sequence, with fat suppression (thrive) was performed in a triphasic manner [arterial phase (16-20 sec.), portovenous phase (45-60 sec.) and delayed equilibrium phase (3-5 min.)] after administration of contrast media. Subtraction images were also performed for each phase.

c) Diffusion study: Respiratory-triggered fat-suppressed single-shot echo-planar DW imaging was performed in the transverse plane with tri-directional diffusion gradients by using b values 0, 50, 200, 500 & 700 sec/mm^2. Parameters were as follows: repetition time (TR) = 1852 ms, echo time (TE) = 70 ms, number of excitations (NEX)= 3, matrix 150x236 with a field of view as small as possible, slice thickness 4 mm, slice gap 0.5 mm, scan time 5 min

Imaging evaluation:

- Conventional pre-contrast images were evaluated regarding the signal intensity of the focal lesion on T1 & T2W images. The dynamic post contrast images were evaluated regarding the enhancement pattern of the focal lesion, confirmed on subtraction images & the maximum transverse diameter of the enhancing tumor tissue is measured in the arterial phase images (fig. 1).
- This is done before & after chemoembolization & the percent reduction in the maximum transverse diameter of the enhancing tumor tissue is calculated. According to modified RECIST criteria for evaluation of HCC response to treatment **(15)**, the studied focal lesion was classified as:

-Complete response: disappearance of any intratumoral arterial enhancement.

-Partial response: at least 30% decrease in the maximum transverse diameter of the viable (contrast enhancement in the arterial phase) tumor tissue.

-Progressive disease: an increase of at least 20% in the maximum transverse diameter of the viable (enhancing) focal lesion.

-Stable disease: cases not qualifying for either partial response or progression

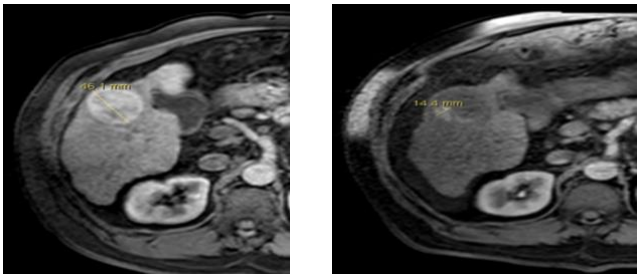

(fig. 1): Measurement of the maximum transverse dimension of the enhancing tumor tissue before (a) & after (b) chemoembolization in a patient with partial response to treatment showing residual enhancing tissue in the arterial phase after chemoembolization

ADC calculation: The mean ADC of the focal lesion was calculated by positioning multiple regions of interest (ROI) over the tumor in consecutive image sections & then the mean ADC was calculated. The ROIs may be placed directly onto the ADC map or copied onto the map from those drawn on morphological or *b*-value DW-MR images (fig. 2).The individual voxel values in the ROI placed on the maximum transverse diameter of the focal lesion is used to generate ADC histograms. The histogram-based approach can be also helpful to visualize tumor response to treatment by a change in the shape or distribution of the histogram.

Results: The mean duration between pretreatment MRI and chemoembolization was 4 days (range, 0–9 days), and the mean duration between treatment and post-treatment MRI was 32 days (range, 25–51 days).According to mRECIST criteria, patients are classified into two groups: Patients with complete response with complete absence of arterial enhancement in the post treatment MRI & Patients with partial response with residual arterial enhancement. Unfortunately we did not have cases who met the mRECIST criteria for stable or progressive disease.

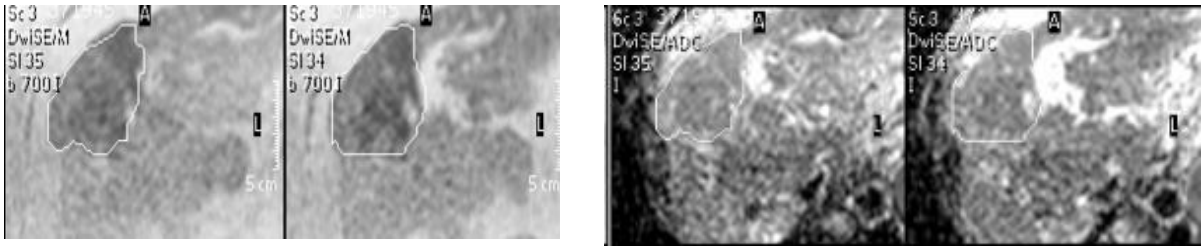

(a) ***(b)***

(fig. 2): Measurement of the mean ADC of the focal lesion, by positioning a ROI over the tumor in consecutive sections. The ROIs may be placed directly onto the ADC map (b) or copied onto the map from those drawn on morphological or b-value DW-MR images (a)

According to **Willcoxon sign test *(17)*** that was used to compare quantitative variables before & after treatment: The mean diameter of the enhancing tumor tissue before treatment was 5.9 mm $\pm$ 1.7 standard deviation (SD) & after treatment was 1.5 mm $\pm$ 1.3 SD with statistically significant difference (*P value less than 0.001*). The mean tumor ADC value before treatment was 1.2 x 10^{-3} mm^2/sec $\pm$ 0.1 SD. This value increased to 1.49 x 10^{-3} mm^2/sec $\pm$ 0.3 SD after treatment, with statistically significant difference (*P value less than 0.001*). The mean serum alpha fetoprotein level before treatment was 2031 ng/ml $\pm$ 5944 SD that

decreased to 843 ng/ml ± 1845 SD after treatment, with statistically non-significant difference (*P value more than 0.05*). According to **Mann Whitney-test *(17)*** there was a statistically significant difference between both groups as regard: The diameter of the enhancing tumor tissue after chemoembolization (P-value less than 0.05), the percent change in the diameter of the enhancing tumor tissue after treatment (P-value less than 0.001), the mean ADC of the focal lesion after treatment (P-value less than 0.05), the percent change in the mean ADC after treatment (P-value less than 0.001) & the serum alpha fetoprotein before & after treatment (P-value less than 0.05) (table 1).On the other hand, there was no statistically significant difference between patients with complete response & those with partial response as regard the patient age, the diameter of the enhancing tumor tissue before chemoembolization & the mean ADC of the focal lesion before treatment (P-value more than 0.05)

Variables	**Partial response** (mean±SD)	**Complete response** (mean±SD)	**P value**
Diameter (pre)	6.9±1.9	4.9±1.1	>0.05 NS
Diameter (post)	2.5±1.8	0+0	**<0.05 S**
% change in the diameter	65.2±19	100±0	**<0.001 HS**
Mean ADC (pre)	1.2±0.11	1.2±0.06	>0.05 NS
Mean ADC (post)	1.4±0.2	1.7±0.2	**<0.05 S**
% change in the ADC	11.6±7	34.6±10	**<0.001 HS**
Serum AFP (pre)	156(22-5395)	74(20-3288)	**<0.05 S**
Serum AFP (post)	7.5(6.2-95)	5.5(5-6.7)	**<0.05 S**
% change in the serum AFP	3.9+10	38+20	>0.05 NS
Patient age	61±5	56±10	>0.05 NS

(Table 1) Comparison between patients with complete & partial response regarding different statistical variables, S (Significant), HS (Highly Significant), NS (Non-Significant), pre (before chemoembolization), post (1month after chemoembolization)

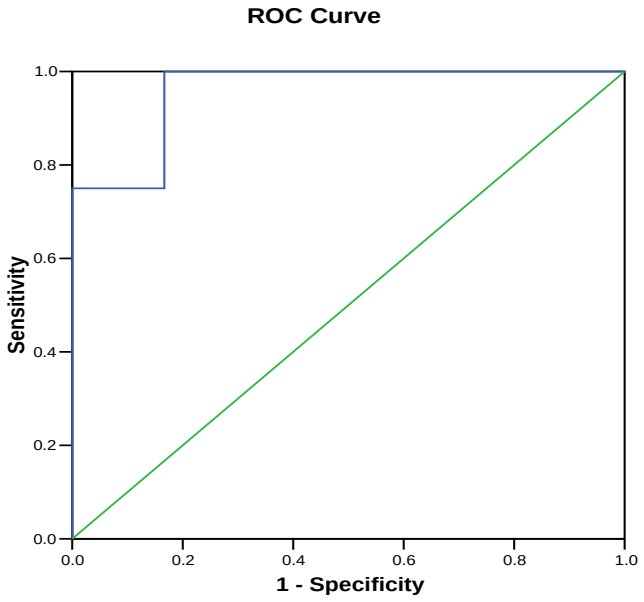

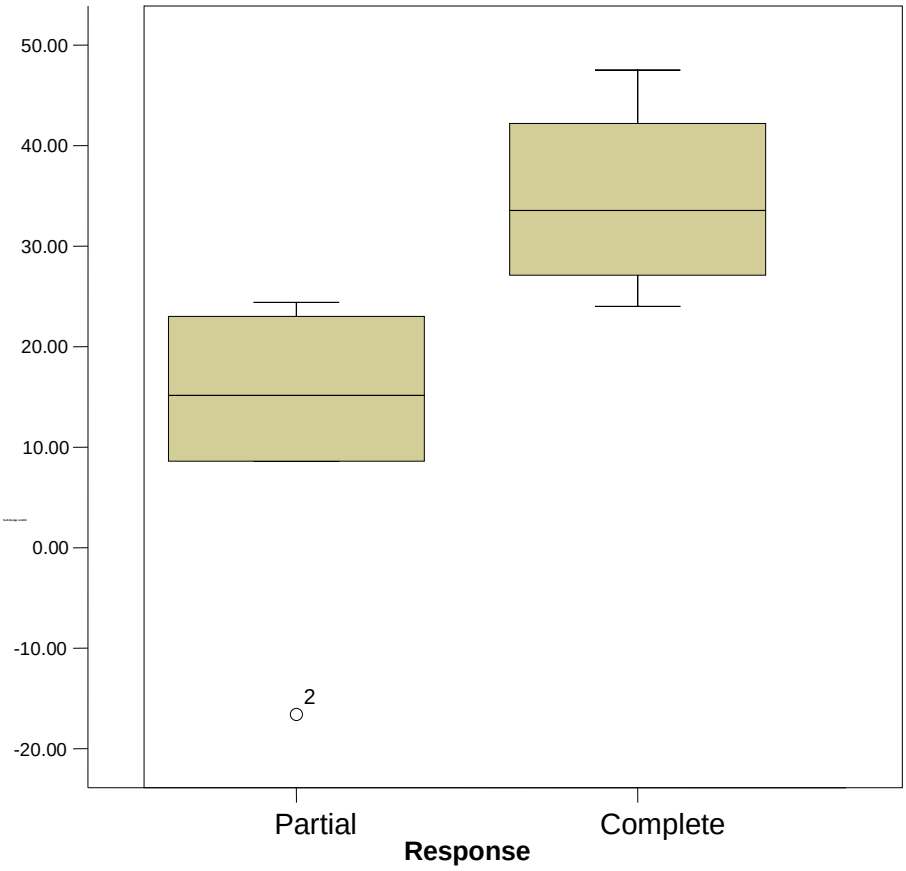

(Diagram 3) ROC curve showing significant correlation between the % change in the mean ADC of the tumor & the % change in the diameter of the enhancing tumor tissue, with the area under the curve being 0.96

% change of mean ADC

(Diagram 1) The percent change in the mean ADC of the tumor is higher in patients with complete response than those with partial response

According to **Mann Whitney-test (17)** the percent change in the mean ADC among patients with complete response was higher than that among patients with partial response (P-value less than 0.001) (Diagram 1). Results of **Receiver Operating Curve (ROC)** analysis revealed significant correlation between the percent change in the mean ADC & the percent change in the diameter of the enhancing tumor tissue after treatment, the area under the curve being 0.96 (Diagram 3). The best predictive cut off value for differentiation between complete & partial response was 24 % change in the mean ADC, with 99 % sensitivity, 84 % specificity, 90 % positive predictive value, 99 % negative predictive value & 86 % accuracy. The % change of the mean ADC is considered better positive than negative predictor for response to treatment

Illustrative Cases : Case 1

A 57 year old male patient presented with a single focal lesion in the right lobe of the liver (segment V), measuring 4.6 cm in its maximum transverse dimension, showing heterogeneous enhancement in the arterial phase & washout in the delayed phase (fig.3).

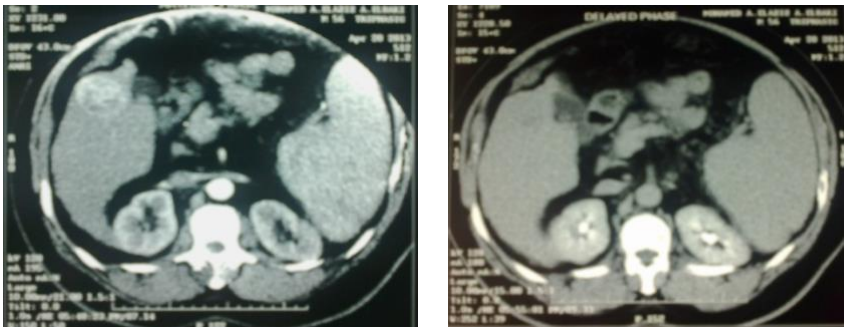

(a) (b)

(fig.3) Triphasic CT showing enhancement of the focal lesion in the arterial phase (a) & washout in the delayed phase (b)

Dynamic post-contrast MRI was done, showing the same pattern of enhancement (fig.4). On the Diffusion-weighted image, the lesion shows relative diffusion restriction (fig.5), with a mean ACD of 1.146 x 10^{-3} mm^2/sec.

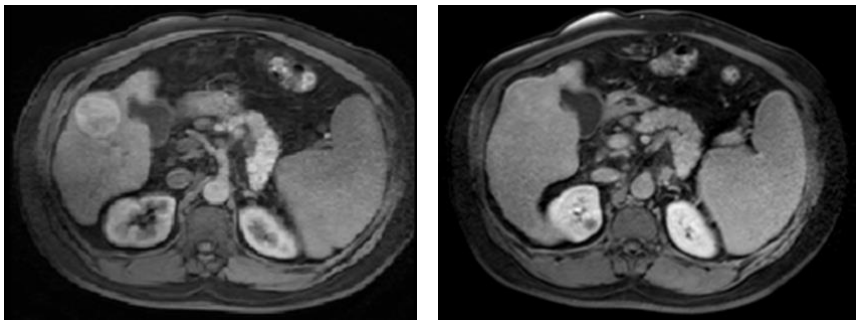

(a) (b)

(fig.4) Dynamic post-contrast MRI showing enhancement of the focal lesion in the arterial phase (a) & washout in the delayed phase (b)

(fig.5) Diffusion-weight MRI, inverted grayscale image, at b-value 500 sec/ mm2, the lesion shows relative diffusion restriction

Transcatheter arterial hepatic angiography shows the focal lesion to take supply from two arteries, the medial one being the principal feeder, with minor contribution from the lateral one (fig.6). Chemo-lipoidol injection is done (fig.7), with successful embolization of the medial vessel.

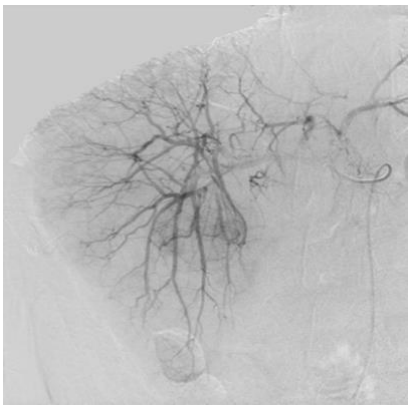

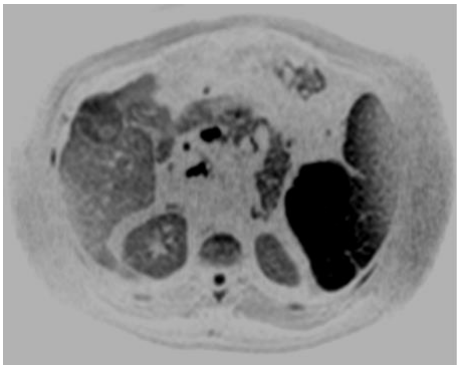

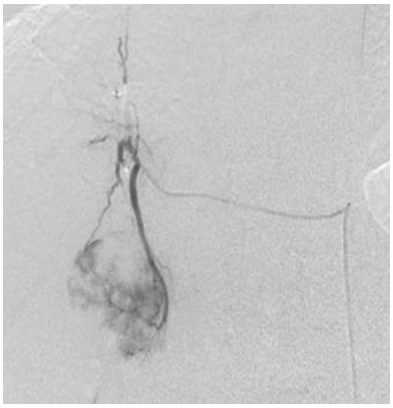

(a) (b)

(fig.6) (a) Transcatheter arterial hepatic angiography revealed abnormal blush at the site of the focal lesion. (b) Superselective catheterization shows the focal lesion to take supply from two arteries, the medial one being the principal feeder, with minor contribution from the lateral one.

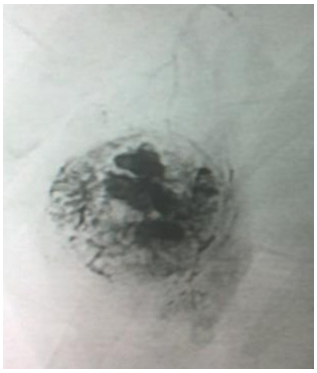

(fig.7) Subtracted image showing lipoidol concentration in the focal lesion

Follow up dynamic post-contrast MRI is done after one month & revealed small residual viable tumor tissue in the right postero-lateral portion of the focal lesion, showing enhancement in the arterial phase & washout in the delayed phase (fig.8), denoting partial response, with 60 % reduction in the maximum transverse dimension of the enhancing tumor tissue. Diffusion-weighted MRI revealed reduction in the relative diffusion restriction of the focal lesion, with a mean ADC of 1.391 x 10^{-3} mm^2/sec. A small area of relative diffusion restriction is noted at the right postero-lateral margin of the focal lesion (fig.9), corresponding to the residual enhancing tumor tissue evident in the dynamic post-contrast MR images. This residual viable portion is likely supplied by the lateral vessel that is not embolized & provides a minor contribution to the arterial supply of the focal lesion as previously shown by superselective transcatheter arterial angiography.

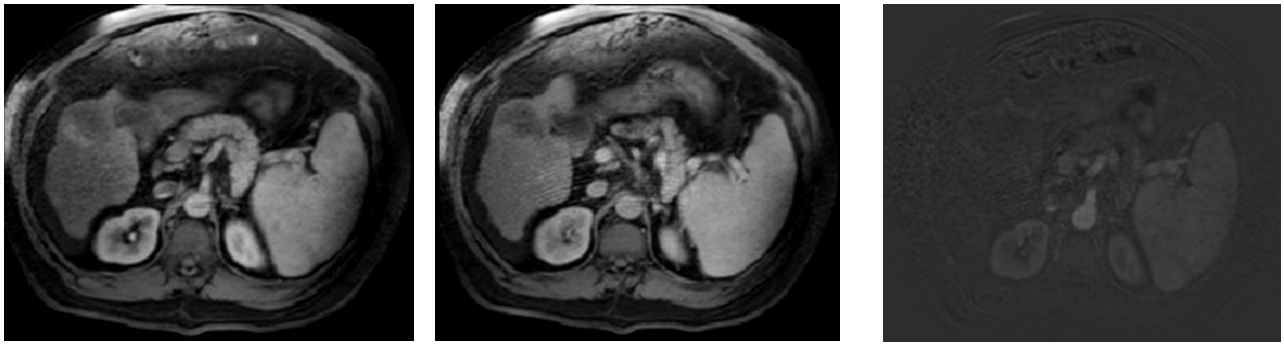

(a) (b)

(c)

(fig.8) Follow up dynamic post-contrast MRI after one month revealed small residual viable tumor tissue at the right postero-lateral margin of the focal lesion n showing enhancement in the arterial phase (a) & washout in the delayed phase (b). (c) Subtracted image in the arterial phase showing enhancement of the residual viable tumor tissue.

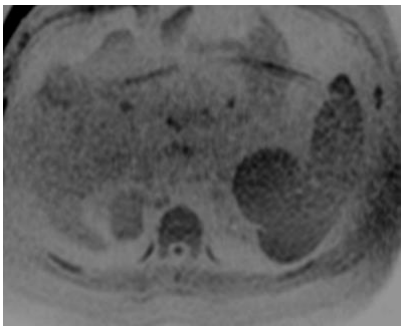

(fig.9) Follow up diffusion MRI inverted grayscale image, at b-value 500 sec/ mm2 after one month. The focal lesion shows relative reduction in diffusion restriction, with a small residual diffusion restriction at the right postero-lateral margin.

Case 2: A 73 year old male patient presented with a focal lesion in the right lobe of the liver, at segment VIII, measuring 4.8 cm in diameter, showing characteristic enhancement pattern of HCC, with enhancement in the arterial phase & washout in the porto-venous phase (fig.10). On MRI done before chemoembolization, the focal lesion shows enhancement in the arterial phase & washout in the portovenous phase (fig.11), with restricted diffusion on diffusion-weighted image (fig.12)

(a) 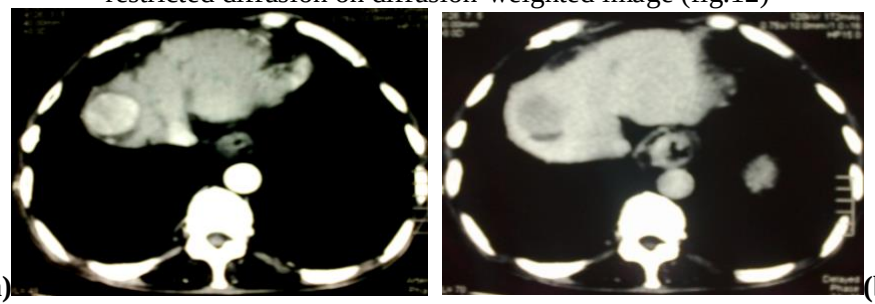 **(b)**

(fig.10) Triphasic CT showing enhancement of the focal lesion in the arterial phase (a) & washout in the portovenous phase (b)

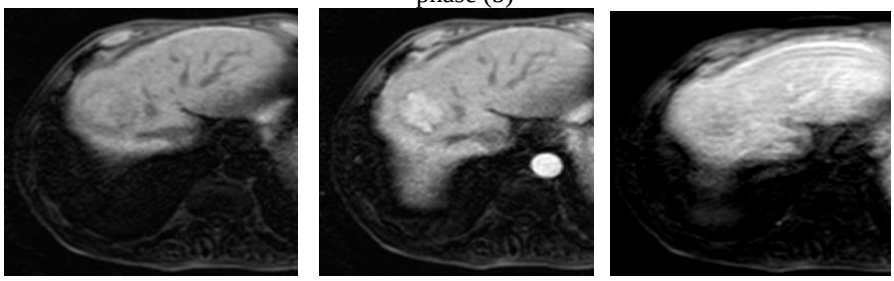

(a) (b) (c)

(fig.11) Pretreatment MRI, precontrast image (a), arterial phase image (b), showing enhancement of the focal lesion, portovenous phase image (c) showing washout of contrast from the focal lesion

(a) 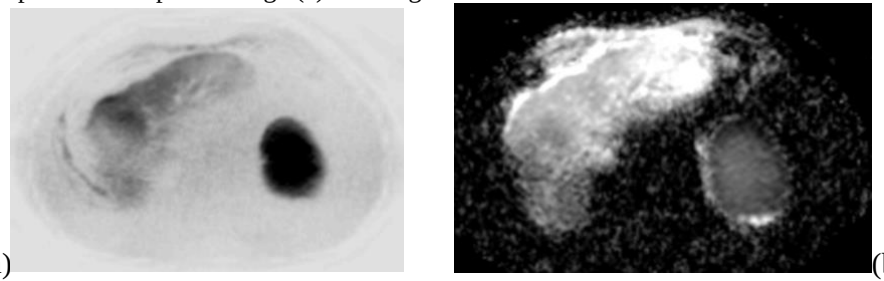 (b)

(fig.12) Diffusion MRI inverted grayscale image, at b-value 500 sec/ mm2 (a), the focal lesion shows relative diffusion restriction, evident on the corresponding ADC map (b)

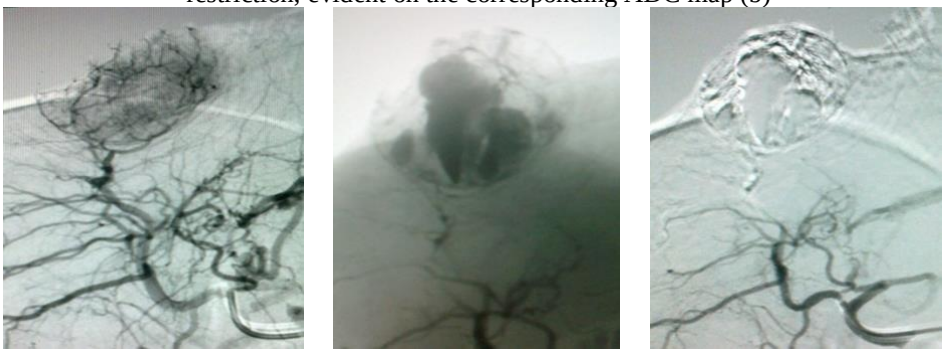

(a) (b) (c)

(fig.13) Hepatic arterial angiography (a) showing pathological vessels of the focal lesion, (b) showing lipoidol concentration in the lesion & (c) subtracted image showing embolization of the feeding vessel MRI done after one month revealed complete response, with absence of enhancing tissue in the arterial phase image (fig.14), resolution of diffusion restriction (fig.15), 36.9 % elevation of the mean ADC of the focal lesion & shift of the histogram curve to the right (fig.16).

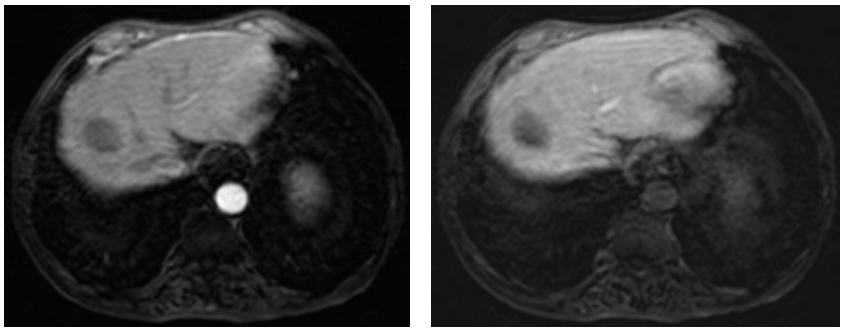

(a) (b)

(fig.14) Dynamic MRI done one month after treatment, arterial phase (a) & porto-venous phase (b) images, showing complete response with no evidence of residual enhancement in the arterial phase

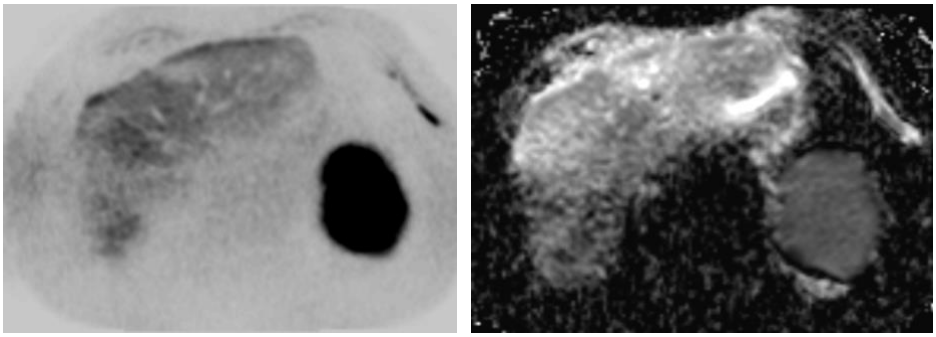

(a) (b)

(fig.15) Diffusion weighted MRI, inverted grayscale image, at b-value 500 sec/ mm2 (a), showing resolution of diffusion restriction, with the corresponding ADC map (b)

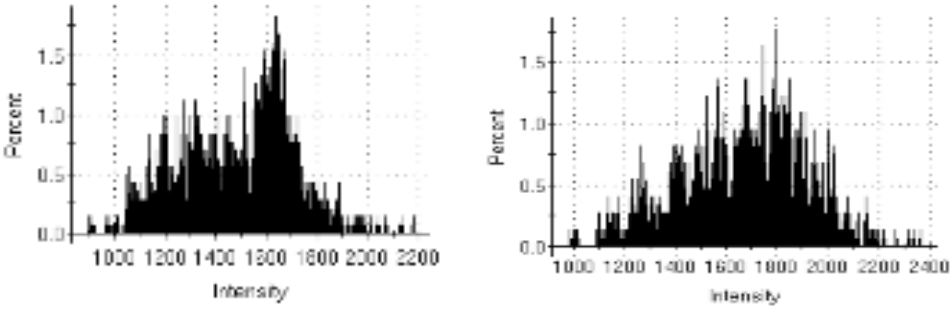

(a) (b)

(fig.16) Comparison between histogram of the focal lesion before (a) & after (b) chemoembolization, showing shift of the curve to the right side

Discussion

Assessment of tumor viability after TACE is important for evaluation of tumor response, subsequent treatment planning, and evaluation for liver transplantation. Although histopathologic assessment of the treated tumor remains the most definitive method to determine viability, it is not feasible as a method for follow-up **(23)**.

The goal of local treatment of HCC is tumor necrosis rather than tumor shrinkage. In time, it has become evident that RECIST standards for assessment of tumor response to therapy are not enough for response evaluation in HCC after chemoembolization, because they depend on changes in tumor size & do not take into account changes in tumor viability that may be associated with tumor response **(6)**. In 2000, the European Association for the Study of the Liver **(2)** proposed that the optimal method to evaluate response to local treatment is to assess the reduction in viable tumor volume, which is seen as a reduction in enhancing areas on contrast-enhanced images. The currently used method for assessment of HCC response to chemoembolization is the modified RECIST criteria that depend on the arterial enhancement of the viable tumor tissue **(15).** Although contrast-enhanced CT is able to reveal residual or recurrent tumors as areas of arterial enhancement, it is often difficult to assess accurately contrast enhancement in such areas adjacent to retained iodized oil on CT, because of the beam-hardening artifacts caused by such iodized oil. Residual viable tumor tissue is better depicted by gadolinium-enhanced MR imaging that is barely influenced by the presence of iodized oil **(7). Kalb et al., (9)** investigated the usefulness of early (1-month) post-therapy contrast-enhanced MR imaging for the detection of residual disease after chemoembolization for HCC. The results showed good sensitivity for the ability of the 1-month follow-up MR imaging study to predict the presence of residual disease using persistent arterial phase contrast enhancement as a marker of the viable tumor with 100% specificity in predicting complete response to therapy. **Murakami et al. (18)** reported a sensitivity of 80% with the use of dynamic MR imaging with gadopentetate contrast medium in 10 patients after chemoembolization with Lipoidol. Viable tumor was shown to correlate with early hyperintense enhancement, whereas lack of early enhancement corresponded to necrotic regions of the tumor. **Ito et al. (8)** reported a sensitivity of 92% with the use of multisection dynamic MR with gadopentetate contrast medium to assess tumor viability in 13 patients after chemoembolization with Lipoidol.

Riaz et al.(19) showed that the application of strict radiologic response criteria (EASL and WHO) after chemoembolization had a reasonable ability to predict actual tumor necrosis. These data consolidated the belief that changes in the amount of enhancing tissue after chemoembolization correspond to the actual necrosis. **Kim et al. (13)** observed that qualitative assessment of tumor necrosis of HCC following TACE based on subtracted datasets of contrast-enhanced MRI had an excellent correlation with histopathology, with higher interobserver agreement when compared with non-subtracted dataset, and a statistically significant difference for predicting complete tumor necrosis at the arterial phase.

Image subtraction was used in assessment of the post contrast dynamic series in the current study. This was of great value in demonstrating enhancement in the T1 hyperintense lesions. The use of subtracted image data sets was also reported in previous similar studies **(13 & 16**). In this cohort, we found a statistically significant difference in the diameter of the enhancing tumor tissue before and after chemoembolization, as well as, the percent change in the diameter of the enhancing tumor tissue after treatment between patients with complete response & those with partial response.

Response assessment is a newly developing scope of DWI that does not require the use of contrast media. The first studies of this issue were done in rabbit VX2 tumor models **(24).** According to those studies, necrotic areas have higher ADC values than viable tumor areas, and ADC of normal liver parenchyma. Several previous clinical studies have shown the ability of DWI to map water distribution within HCC tumors and quantify tumor necrosis after chemoembolization: **Kamel et al. (10, 11)** have confirmed the feasibility of DWI to measure tumor response, which shows an increase in the ADC value at 4-6 wk after TACE. In their studies, regions of increased ADC corresponded to non-enhancing regions of presumed coagulative necrosis on contrast-enhanced MRI. More recently **Kamel et al. (12)** have demonstrated ADC changes as early as 1 wk post-TACE with no significant changes occurring at 1 d of follow-up**. Chen et al. (3)** have further demonstrated on a 3.0-T MR scanner an increase in HCC ADC values as early as 2-3 d after therapy. **Chung et al. (4)** had addressed the role of

intra-procedural DWI in predicting a future anatomical response 1 mo after TACE. Specifically, they showed that patients whose ADC value increased or decreased from baseline by > 15% immediately after TACE had a 100% rate in predicting a positive EASL response after one month.

In the current study, the mean tumor ADC value increased from 1.2±0.1 x 10^{-3} mm^2/sec to 1.49±0.3 x 10^{-3} mm^2/sec. ADC values obtained were lower than the ADC values of focal lesions in the studies of **Kamel et al. (10, 11)** and **Chen et al.(3)** and higher than the ADC values of the lesions in the studies of **Sahin et al. (20)** and this may be a consequence of differences in parameters of DWI, including the b values, and magnetic strength in our opinion. Choice of b-values may have an influence on calculated ADC value, which is affected by tissue perfusion at low b-values. This may confound measurement of tissue diffusivity and cause higher ADCs by using lower b-values. The b values used were 0 and 500 sec/mm^2 in the study of **Chen et al. (3)** and 50, 400, and 800 sec/mm^2 in the study of **Sahin et al. (20).** The b values used in the present study were 0, 50, 200, 500 & 700 sec/$mm^{2.}$ Also of note is the difference in the percent increase in the ADC value after chemoembolization. In their study (**11** & **20**), the increase in the mean ADC value of the focal lesions was 20% and 15.4% respectively, whereas, in the present study, it was 11.6±7% in patients with partial response, and 34.6±10% in patients with complete response with a statistically significant difference between the two groups.

According to the current study, the best predictive cut off value for differentiation between complete & partial response was 24 % increase in the mean ADC value, with 99 % sensitivity, 84 % specificity, 90 % positive predictive value, 99 % negative predictive value & 86 % accuracy. The % increase of the mean ADC value is considered better positive than negative predictor for response to treatment. **Mannelli et al. (16)** reported 75% sensitivity & 87.5 % specificity of a pre-treatment tumor mean ADC cutoff value greater than 2.16 x 10^{-3} mm^2/sec for prediction of complete tumor necrosis. In addition, the present study showed a significant positive correlation between the percent change in the mean ADC value & the percent change in the diameter of the enhancing tumor tissue after chemoembolization. These results consolidate the belief that DWI is potentially useful for follow-up after TACE by showing changes in ADC value as an alternative to contrast- enhanced MRI in the care of patients who cannot receive gadolinium contrast material, such as patients with renal insufficiency at risk of nephrogenic systemic fibrosis. On the other hand there was no statistically significant correlation between the percent change in the serum AFP level & the percent change in the diameter of the enhancing tumor tissue after treatment. This means that serum AFP level cannot be used solely in the follow up of patients after chemoembolization.

Yuan et al. (24) proposed that high pretreatment mean ADC values of HCC were predictive of poor response to chemoembolization. In the current study, there was no statistically significant difference between patients with complete & partial response as regard the pre-treatment mean ADC value and this was in agreement with **Sahin et al. (20)**. However, further studies on this issue with larger numbers of patients are needed to reach a firmer conclusion.

In addition to the quantitative assessment of the DWI and ADC value measurements, we also assessed the DW images qualitatively (using the high b value images) for relative diffusion restriction in portions of the tumor that show arterial enhancement in the dynamic images. This was also done in conjunction with reviewing the angiographic images before & after chemoembolization. Also, the change in the shape & distribution of the histogram curve after chemoembolization was investigated & correlated with the tumor response to treatment.

Homogenous, thin rim enhancement around the tumor on delayed gadolinium-enhanced images represents chemoembolization-induced vasculitis, inflammation, and granulation tissue after local treatment **(21).** Contrast enhancement in granulation tissue is believed to be caused by increased capillary permeability and increased distribution of gadolinium **(25).** On the contrary, the presence of nodular ring enhancement should cast doubt on local progression. Yet, it is still difficult to detect small residual areas located in the capsule. In those situations, DWI may have a promising role in the differentiation of necrosis and viable tumor, as ADC values increase in the presence of necrosis **(23).**

Acknowledgment:

Special thanks to Dr: Mohammed El-gharib, the interventional radiologist who performed chemoembolization for the patients of the study.

References:

1-**Bonekamp S, Jolepalem P, Lazo M, Gulsun MA, Kiraly AP & Kamel IR (2011**): Hepatocellular carcinoma: Response to TACE assessed with

semiautomated volumetric & functional analysis of diffusion-weighted and contrast-enhanced MR imaging data. Radiology, 260 (3): 752-761.

2-**Bruix J, Sherman M, Llovet JM et al. (2001).** Clinical management of hepatocellular carcinoma. Conclusions of the Barcelona-2000 EASL conference. European Association for the Study of the Liver. J Hepatol.,35:421–430.

3-**Chen CY, Li CW, Kuo YT et al. (2006)** Early response of hepatocellular carcinoma to transcatheter arterial chemoembolization: choline levels and MR diffusion constants—initial experience. Radiology , 239:448–456.

4-**Churg JC, Naik NK, Lewandowski RJ et al. (2010)**.: Diffusion-weighted magnetic resonance imaging to predict response of hepatocellular carcinoma to chemoembolization. World Journal of Gastroenterology, 16 (25): 3161-3167.

5-**Eisenhauer EA, Therasse P & Bogaerts J (2009)**: New response evaluation criteria in solid tumors: revised RECIST guidelines (version 1.1). Eur J Cancer, 45(2): 228-247.

6-**Forner A, Ayuso C, Varela M et al. (2009)**: Evaluation of tumor response after locoregional therapies in hepatocellular carcinoma. Cancer , 115: 616–623.

7-**Goshima S, Kanematsu M, Kondo H et al. (2008)**: Evaluating Local Hepatocellular Carcinoma Recurrence Post-Transcatheter Arterial Chemoembolization: Is Diffusion-Weighted MRI Reliable as an Indicator? Journal of Magnetic Resonance Imaging ,(27):834–839.

8-**Ito K, Honjo K, Fujita T et al. (1995)**: Therapeutic accuracy of transcatheter arterial chemoembolization for hepatocellular hepatocellular carcinoma: MRI and pathology. J Comput Assist Tomogr ., 19:198– 203.

9-**Kalb B, Chamsuddin A, Nazzal L et al. (2010)**: Chemoembolization Follow-up of Hepatocellular Carcinoma with MR Imaging: Usefulness of Evaluating Enhancement Features on One-month Posttherapy MR Imaging for Predicting Residual Disease. J Vasc Interv Radiol., 21:1396–1404.

10- **Kamel IR, Bluemke DA, Ramsey D et al. (2003):** Role of diffusion weighted imaging in estimating tumor necrosis after chemoembolization of hepatocellular carcinoma. AJR Am J Roentgenol ., 181:708–710.

11-**Kamel IR, Bluemke DA, Eng J et al. (2006):** The role of functional MR imaging in the assessment of tumor response after chemoembolization in patients with hepatocellular carcinoma. J Vasc Interv Radiol ., 17:505–512.

12-**Kamel IR, Liapi E & Reyes DK (2009)**: Unresectable hepatocellular carcinoma: serial early vascular & cellular changes after transarterial chemoembolization as detected with MR imaging. Radiology, 250(2): 466-473.

13-**Kim S, Mannelli L, Hajdu CH, B abb JS, Clark T W I, Hecht EM & Taouli B (2010)**: Hepatocellular carcinoma: Assessment of response to transarterial chemoembolization with image subtraction. Journal of Magnetic Resonance imaging., 31: 348-355.

14-**Kloeckner R, Otto G, Biesterfeld S, Oberholzer K, Dueber C & Pitton M B(2010)**: MDCT versus MRI assessment of tumor response after transarterial chemoembolization for the treatment of hepatocellular carcinoma. Cardiovasc Intervent Radiol., 33: 532-540.

15-**Lencioni R & Josep M (2010)**: Modified RECIST (mRECIST) Assessment for Hepatocellular Carcinoma in Seminars in liver disease. Barcelona, 30: 52-60.

16-**Mannelli L, Kin S, Hajdu CH, Balb JS, Clark TW & Taouli B (2009)**: Assessment of tumor necrosis of hepatocellular carcinoma after chemoembolization: Diffusion-weighted & contrast enhanced MRI with histopathologic correlation of the explanted liver. AJR AmJ Roentgenol., 193(4): 1044-1052.

17-**Miller M (1992)**: Clinical epidemiology and Biostatistics. William & Wilkins, Maryland, 3rd edition: 120-153.

18-**Murakami T, Nakamura H, Hori S et al. (1993):** Detection of viable tumor cells in hepatocellular carcinoma following transcatheter arterial chemoembolization with iodized oil. Pathologic correlation with dynamic turbo-FLASH MR imaging with Gd- DTPA. Acta Radiol ., 34:399–403.

19-**Riaz A, Robert J, Kulik L et al. (2010)**: Radiologic–Pathologic Correlation of Hepatocellular Carcinoma Treated with Chemoembolization. Cardiovasc Intervent Radiol., (33):1143–1152.

20-**Sahin H, Harman M, Cinar C et al. (2012)**: Evaluation of Treatment Response of Chemoembolization in Hepatocellular Carcinoma with Diffusion-Weighted Imaging on 3.0-T MR Imaging. J Vasc Interv Radiol .,23:241–247.

21-**Semelka RC, Worawattanakul S, Mauro MA, Bernard SA, Cance WG (1998):** Malignant hepatic tumors: changes on MRI after hepatic arterial chemoembolization-- preliminary findings. J Magn Reson Imaging , 8:48–56.

22-**Stephen J., Yu W, Weintraub J et al. (2009)**: Radiologic Monitoring of Hepatocellular Carcinoma Tumor Viability after Transhepatic Arterial Chemoembolization: Estimating the Accuracy of Contrast-enhanced Cross-sectional Imaging with Histopathologic Correlation. J Vasc Interv Radiol , (20): 30–38.

23-**Thabet A, Kalva S, Gervais DA (2008):** Percutaneous image-guided therapy of intraabdominal malignancy: imaging evaluation of treatment response. Abdom Imaging , 34:593–609.

24-**Yuan YH, Xiao EH, Liu JB et al. (2007)**: Characteristics and pathological mechanism on magnetic resonance diffusion-weighted imaging after chemoembolization in rabbit liver VX-2 tumor model. World J Gastroenterol ., 13:5699–5706.

25-**Yuan Z, Ye XD, Dong S, et al. (2010)**: Role of magnetic resonance diffusionweighted imaging in evaluating response after chemoembolization of hepatocellular carcinoma. Eur J Radiol ., 75:e9–e14.