

## Gallstone Ileus: Case Report of a Rare Cause of Intestinal Obstruction in An Unexpected Age Group

\*Bashaer Ahmed Shafei<sup>1</sup>, Rami Issam Arabi<sup>1</sup>, Ahmed Abdulrahim Fallatah<sup>2</sup>

<sup>1</sup>Ibnsina National College for Medical Studies, <sup>2</sup>King Abdulaziz Hospital and Oncology Center

\*Corresponding author: Bashaer Ahmed Shafei, email: [bashaer.shafei@hotmail.com](mailto:bashaer.shafei@hotmail.com), Tel no: 00966566200082

### ABSTRACT

**Background:** gallstone ileus is a rare complication of cholelithiasis and considered as a type of mechanical bowel obstruction in which a gallstone is impacted in the gastrointestinal tract. This condition is seen more frequently in old patients with females' predominance. Gallstone ileus is responsible for 1%-5% of mechanical intestinal obstruction.

**Case presentation:** we report a case of 48 years old medically free, male patient presented to Emergency Department with severe abdominal pain, distention, constipation, multiple attacks of vomiting associated with nausea and with a chronic history of cholecystitis. The diagnosis of gallstone ileus was confirmed by abdominal X-ray and abdominal computed tomography (CT) scan findings. The patient was stabilized before doing an exploratory laparotomy.

**Conclusion:** gallstone ileus is an emergency condition associated with high morbidity and mortality rates. To get the most favorable outcome, high clinical suspicion aided by the use of diagnostic modalities such as CT abdomen is needed to reach the diagnosis since it is usually present with nonspecific signs and symptoms.

**Keywords:** gallstone ileus, intestinal obstruction, fistula, pneumobilia, male patient, and middle age

### INTRODUCTION

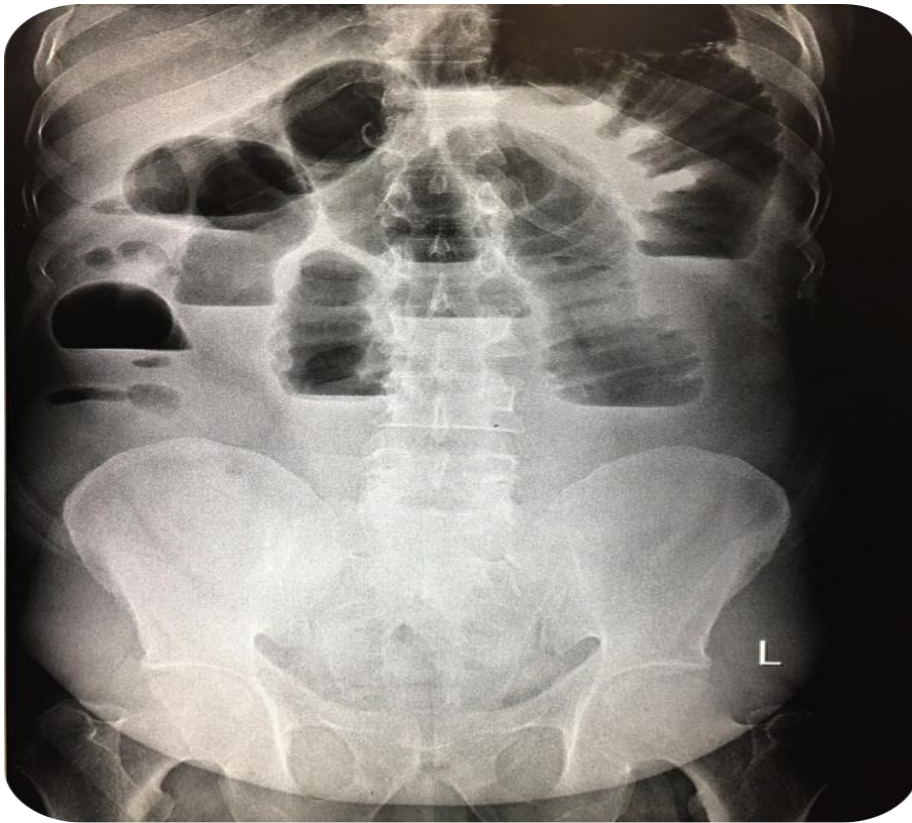
Gall stone ileus is a mechanical bowel obstruction typically affecting the elderly female patients caused by gallstone passing through fistula between the gall-bladder and intestine known as cholecystoenteric fistula allowing the gall stones to enter the GI tract<sup>(1,2)</sup>. The most common fistula forms between the gallbladder and duodenum and the most common site of gallstone impaction is the terminal ileum<sup>(1-4)</sup>. Surgery is considered as the cornerstone to manage gallstone ileus aiming to relieve the obstruction as soon as possible, and enterotomy with stone extraction alone without approaching the fistula is the most common surgical method used to manage this condition due to low incidence of complications<sup>(1)</sup>.

### CASE PRESENTATION

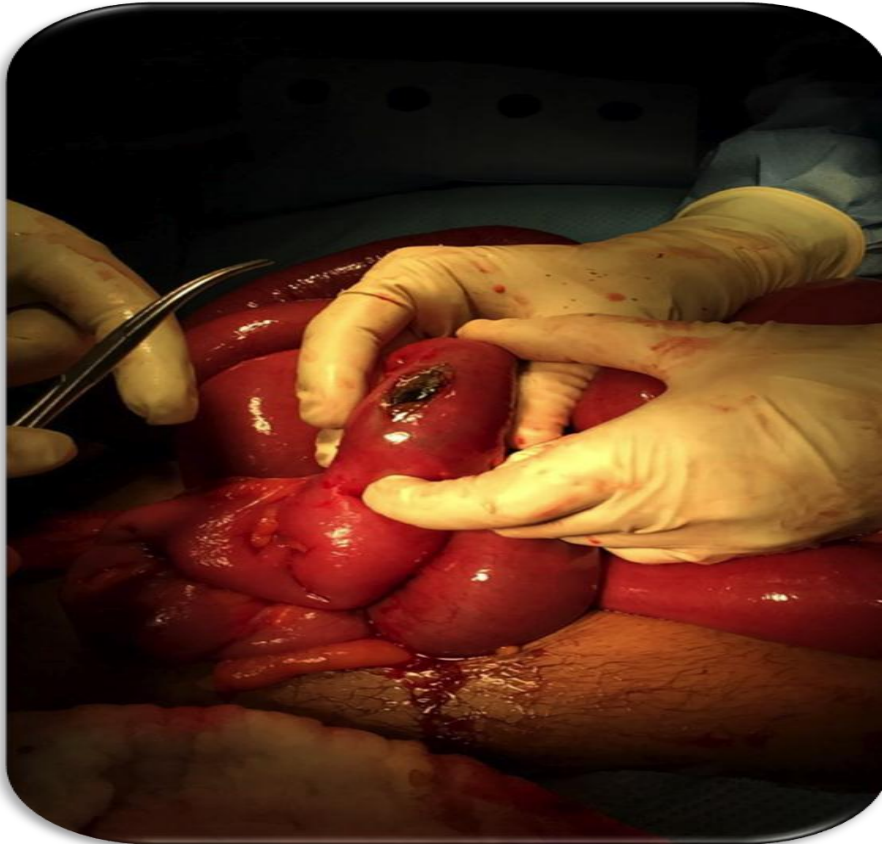A 48 years old medically free, male patient, presented to ER complaining of moderate to thesevere abdominal pain of one-week duration. The pain started gradually and became severe one day before presentation in which the patient developed abdominal distention, constipation, multiple attacks of vomiting and worsening of his symptoms. There was no history of fever, loss of weight, anorexia, melena or hematemesis. He had a history of gallstones and gastric ulcer in which he was treated as a case of peptic ulcer disease and chronic cholecystitis. Upon presentation, the patient was conscious, alert, oriented, looks ill and in pain. Vital signs: Blood pressure: 120/60 mmHg, pulse: 70 beats per minute and temperature: 37.3 cesius. The abdomen was distended, soft and lax but with tenderness on the right side, Murphy sign was negative and right inguinal swelling was noted. On auscultation, the bowl sound was sluggish, and per-rectal examination was unremarkable. Initial labs showed white blood cells (WBC) 11.7 billion/L, hemoglobin (Hb): 13

g/dl, platelets (Plt) : 456\*10<sup>9</sup>/L, Na: 137 mmol/L, K: 4.1mmol/L, Urea: 8 mmol/L, Creatinine (Cr): 95umol/L, Amylase: 60 U/L, liver function test (LFT), coagulation profile and arterial blood gases (ABG) were normal. The patient was resuscitated with intravenous (IV) fluids, X-ray and CT abdomen with oral and IV contrast were done for the patient. X-ray showed multiple air fluid levels with dilated bowel loops which suggested intestinal obstruction (figure 1), while CT scan demonstrated large stone impacted in the distal ileum, causing small bowel obstruction, evidence of pneumobilia was noted as well. Upon the X-ray and CT findings of intestinal obstruction due to a gallstone, the patient was prepared for exploratory laparotomy.

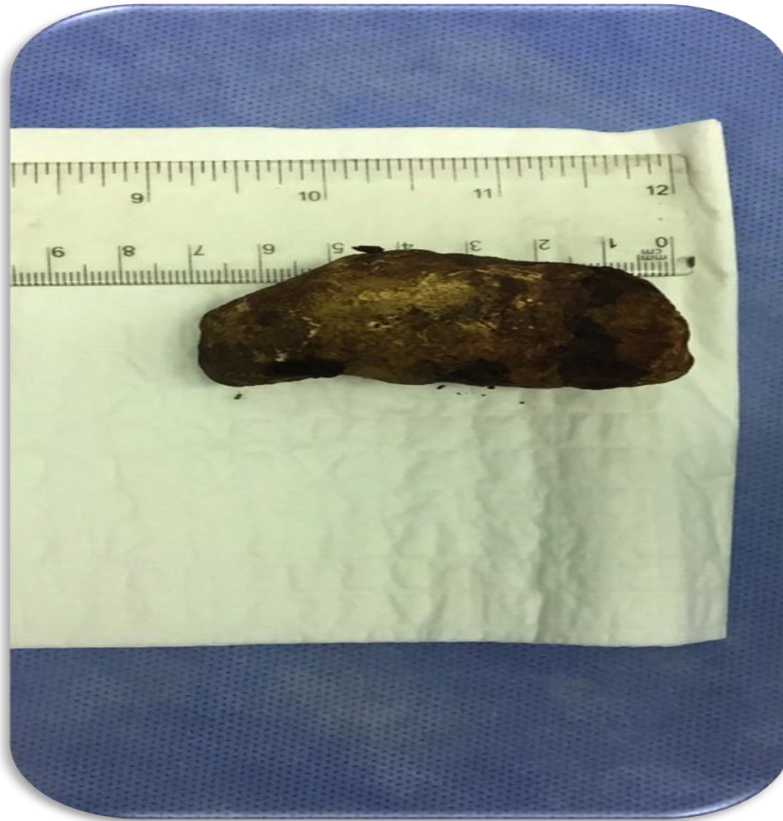Intra-operatively, no collection or perforation were noticed, yet, a stone 7cm x 3cm x 2.5cm was lodged in the terminal ileum and decision was made to perform enterotomy and stone extraction. Enterotomy was performed proximal to the site of the stone, and successful milking with extraction of the gallstone was achieved. (figure 2).



**Figure 1:** Abdominal X-ray is showing multiple air-fluid levels, which indicates an intestinal obstruction.



**Figure 2:** Intraoperative photo demonstrates the site of enterotomy.



**Figure 3: Ppostoperative photo showing the size of the gallstone, 7cm x 3cm x 2.5cm.**

## DISCUSSION

In general, a gallstone ileus is a rare complication of gallbladder stones, and it is uncommon to present in this age especially in males because it affects mainly the elderly female patients<sup>(1)</sup>. Gallstone ileus is caused when one or multiple stones migrate through a cholecystoenteric fistula to the intestine leading to bowel obstruction. The most common fistula forms between the gallbladder and the duodenum, and the most common site of gallstone impaction is the terminal ileum<sup>(1-4)</sup>. The gallstone must be more than 2-2.5 cm in size to cause obstruction<sup>(5,6)</sup>. When an obstruction is suspected, it's important to perform a plain abdominal X-ray in which, a pathognomic triad can be found in up to 50% of patients with gallstone ileus known as rigler's triad and constitutes 1) Ectopic gallstone, 2) bowel obstruction, and 3) air in biliary tree (pneumobilia)<sup>(7,8)</sup>, but in our patient's X-ray showed only a distended bowel loops which suggested intestinal obstruction, yet, the CT scan of this patient showed distended bowel loop, gallstone lodged in the terminal ileum, and pneumobilia. Many studies mentioned that the most effective radiological technique to diagnose gallstone ileus is the CT scan<sup>(8-10)</sup>. The most common surgical method to manage gallstone ileus is enterotomy and stone

extraction alone without fistula closure due to the low incidence of complications, and it was reported that closure of fistula during the initial operation is independently associated with higher mortality rate and longer length of hospital stay<sup>(1,11)</sup>.

**The study was done after approval of ethical board of Ibsina National College for Medical Studies.**

## CONCLUSION

Gallstone ileus is an emergency condition associated with high morbidity and mortality rates. This condition is most commonly seen in elderly patient and predominantly in females. To get the most favorable outcome, high clinical suspicion aided by the use of diagnostic modalities such as CT abdomen is needed to reach the diagnosis since it is usually present with nonspecific signs and symptoms including nausea, vomiting, abdominal pain and abdominal distension. Enterotomy and stone extraction without fistula closure is considered the treatment of choice in case of gallstone ileus aiming to decrease the incidence of complications.

## REFERENCES

- 1- Halabi WJ, Kang CY, Ketana N, Lafaro KJ, Nguyen VQ, Stamos MJ, Imagawa DK, Demirjian AN (2014): Surgery for gallstone ileus: a

## Gallstone Ileus...

- nationwide comparison of trends and outcomes. *Annals of Surgery*, 259(2):329-35.
- 2- **Brockis JG, Gilbert MC (1957):** Intestinal obstruction by gall-stones: a review of 179 cases. *British Journal of Surgery*, 44(187):461-6.
  - 3- **Day EA, Marks C (1975):** Gallstone ileus: review of the literature and presentation of thirty-four new cases. *The American Journal of Surgery*, 129(5):552-8.
  - 4- **Clavien PA, Richon J, Burgan S, Rohner A (1990):** Gallstone ileus. *British Journal of Surgery*, 77(7):737-42.
  - 5- **Kasahara Y, Umemura H, Shiraha S, Kuyama T, Sakata K, Kubota H (1980):** Gallstone ileus: review of 112 patients in the Japanese literature. *The American Journal of Surgery*, 140(3):437-40.
  - 6- **Al-Obaid O (2007):** Gallstone ileus: a forgotten rare cause of intestinal obstruction. *Saudi Journal of Gastroenterology*, 13(1):39.
  - 7- **Rigler LG, Borman CN, Noble JF (1941):** Gallstone obstruction: pathogenesis and roentgen manifestations. *Journal of the American Medical Association*, 22; 117(21):1753-9.
  - 8- **Mohamed ZK, Balupuri S, BoobisLH (2007):** Colonic gallstones: a case report. *HBPD INT.*, 15;6:324-5.
  - 9- **Lassandro F, Gagliardi N, Scuderi M, Pinto A, Gatta G, Mazzeo R (2004):** Gallstone ileus analysis of radiological findings in 27 patients. *European journal of radiology*, 30;50(1):23-9.
  - 10- **Reimann AJ, Yeh BM, Breiman RS, Joe BN, Qayyum A, Coakley FV (2004):** Atypical cases of gallstone ileus evaluated with multidetector computed tomography. *Journal of computer assisted tomography*, 28(4):523-7.
  - 11- **Dai XZ, Li GQ, Zhang F, Wang XH, Zhang CY (2013):** Gallstone ileus: case report and literature review. *World Journal of Gastroenterology*, 19(33):55-86.