

Horizontal Recti Muscle Plication Versus Resection in Squint Surgery

Madeha Abdelfatah Kamel, Zeinab Sayed Hasan, El Sayed Mohammed El Toukhi,
Amani Mohammed Ali*

Department of Ophthalmology, Faculty of Medicine, Al-Azhar University

*Corresponding author: Amani Mohammed Ali, Tel: (+20)01155050833, E-mail: dramenna@hotmail.com

ABSTRACT

Background: Strabismus surgery serves to align the visual axes to provide binocular single vision, or improve cosmesis, or restore normal eye contact, or enhance the quality of life.

Objective: this study aims at evaluating muscle scleral plication technique as regards efficacy, stability, predictability and possible complications and comparing it to the standard resection technique.

Patients and Methods: this study was carried out in the Ophthalmology Department in Al-Zahraa University Hospital and Research Institute of Ophthalmology between 2015 and 2018 on 40 patients. Their ages ranged from 1 to 40 years. 28 patients were males and 22 were females. 23 patients were exotropia and 17 patients were esotropia.

Results: from this study it was found that the effect of plication is more or less the same as that of resection. But it can be noted that muscle scleral plication offers a safe, predictable, alternative to resection with no especially alarming complications that differ from those of ordinary strabismus surgery. This technique can be used instead of resection whenever there is fear of anterior segment ischaemia (ASI), such as when there is a possibility of operating on more than two rectus muscles or when the patient suffers from blood diseases or dysthyroid ophthalmopathy.

Conclusion: from the results of this study, it can be concluded that the muscle-scleral plication technique is an easy alternative to resection that can be used on horizontal muscles especially when anterior ciliary vessels sparing is needed.

Keywords: Horizontal Recti Muscle Plication, Squint Surgery

INTRODUCTION

Resection of an extraocular muscle is generally classified as a strengthening procedure. A muscle resection consists of tightening a muscle by removing part of the muscle and reattaching the shortened muscle to its original insertion site. A resection produces incomitance as the tightened muscle restricts rotation away from the restricted muscle ⁽¹⁾.

Resection procedure is easy to learn and perform. Resection procedure produce more redness and lumpiness of the conjunctivae particularly in the area of medial rectus. Natural barriers to orbital fat are also brought more anteriorly around the medial rectus, promoting the possibility of unsightly fullness after resection. Inferior oblique is often included inadvertently during resection of the lateral rectus leading to limited elevation in the involved eye ⁽²⁾.

Muscle scleral plication can be performed on patients at risk of developing anterior segment ischemia e.g., atherosclerosis, carotid artery disease and dysthyroid ophthalmopathy ⁽³⁾.

A typical tuck procedure is performed through a fornix based incision producing a conjunctivo-tenons flap and thereby exposing the muscle tendon. The tendon is seized in a tucker and tucked. The muscle in the tuck is folded over on itself and sutured with 6/0 suture. Tucking procedure is a saving time technique with avoidance of muscle loss and preservation of

circulation in muscle scleral attachment, thus decreasing any potential anterior segment problems ⁽⁴⁾.

Plication is a quick, simple surgery whose effect is quantitatively similar to resection, and has the advantage of causing lesser surgical trauma and preserving anterior ciliary circulation. This is of specific value where anterior segment ischemia is a consideration as in patients of atherosclerosis and carotid artery disease ⁽⁵⁾.

Plication with minimal dissection through a small incision technique may have further advantages ⁽⁶⁾. Another possible advantage of plication is that it can be readily performed under topical anesthesia as it does not entail relatively painful crushing of extraocular muscles (EOMs) as in resection ⁽⁷⁾.

AIM OF THE WORK

This work aims at comparing muscle scleral plication technique to the standard resection in patients suffering from horizontal deviations.

PATIENTS AND METHODS

This study was carried out in the Ophthalmology Department in Al-Zahraa University Hospital and Research Institute of Ophthalmology between 2015 and 2018 on 40 patients, their ages ranged from 1 to 40 years. 28 patients were males and 22 were females. 23 patients were exotropia and 17 patients were esotropia.

Written informed consent:

An approval of the study was obtained from Al-Azhar University Academic and Ethical Committee. Every patient signed an informed written consent for acceptance of the operation.

Methodology:

All cases were subjected to the following preoperative examination:

- 1- Full ophthalmological examination, including cycloplegic refraction, fundus examination and measurement of visual acuity and best corrected visual acuity whenever possible.
- 2- Assessment of type of fixation.
- 3- Ductions and versions were evaluated in the 6 cardinal directions of gaze.
- 4- A-V pattern and oblique muscle dysfunction were assessed.
- 5- Measurements of the angle of deviation for distant and near fixation with and without correction by prism and cover test. Patients with refractive partially accommodative esotropia were given their full correction before surgery and the surgery was done on the residual angle not corrected with glasses.
- 6- Assessment of stereopsis and binocularity was done whenever possible using Worth's 4 dot test for binocularity and synoptophore for stereopsis.

Operative procedure:**Resection:**

Resection of 3-5 mm from the medial rectus muscles in the exotropic patients and 4-8 mm from the lateral rectus muscles in the esotropic patients was done.

Resection was done according to the standard technique using single suture and limbal approach⁽¹⁾:

- 1- General anesthesia was used in all cases.
- 2- Lid speculum was applied.
- 3- Limbal conjunctival incision was done in all cases to expose the extraocular muscle. An inferior radial incision was performed, then a second radial incision through the Tenon's capsule.
- 4- Westcott scissors were used to undermine the anterior Tenon's capsule and conjunctiva. A limbal peritomy close to the sclera was performed over 4 o'clock hours, then a second radial incision was performed superiorly.
- 5- The muscle was hooked.
- 6- The muscle was freed from the intermuscular septa. This was done further beyond the designated resection distance to help easy manipulation of the muscle.

- 7- Calipers were placed at the intended site of resection. We use 6/0 Vicryl double armed suture for securing the central 2 mm of the muscle (half muscle thickness).
- 8- A full thickness locking bite was then placed through 2 mm of the muscle edge. This was repeated with the other end of the suture.
- 9- The muscle was then clamped anterior to the sutures, and was excised anterior to the clamp.
- 10- The muscle stump was removed close to the sclera.
- 11- The muscle was secured to the original insertion with deep scleral bites.
- 12- The muscle was pulled to the scleral insertion by gently pulling on the suture, the suture were tied using a double throw overhand knot.
- 13- The conjunctiva was closed using interrupted inverted 6/0 Vicryl sutures.

Muscle scleral plication: (Figure 1)**Plication of the medial rectus muscles for exotropic patients and the lateral rectus muscle for esotropic patients:**

- 1- The conjunctiva was incised and the muscle was exposed as described before in steps 1-7 in resection.
- 2- The amount of plication was measured by a caliper.
- 3- The muscle was secured with a Vicryl 6/0 double armed suture with spatula needles at the position indicated by the caliper.
- 4- The needles were passed through half thickness muscle, starting in the center of the muscle, aiming perpendicular to the muscle fibres, towards the edge of the muscle. This was repeated in the other side of the muscle.
- 5- The anterior ciliary arteries were avoided as they lie superficial to the muscle and the sutures were placed somehow deeper and if the vessels came in the way of the locking suture, they were moved aside using a smooth instrument like a blunt Steven's hook
- 6- A scleral bite was taken by each needle just anterior to the muscle insertion, avoiding as many anterior ciliary vessels as possible.
- 7- A double throw overhand knot was secured and the needle holder or non-toothed forceps pinched the knot so it did not loosen then a second throw was placed.
- 8- The conjunctiva was closed using interrupted inverted 6/0 Vicryl sutures⁽⁸⁾.

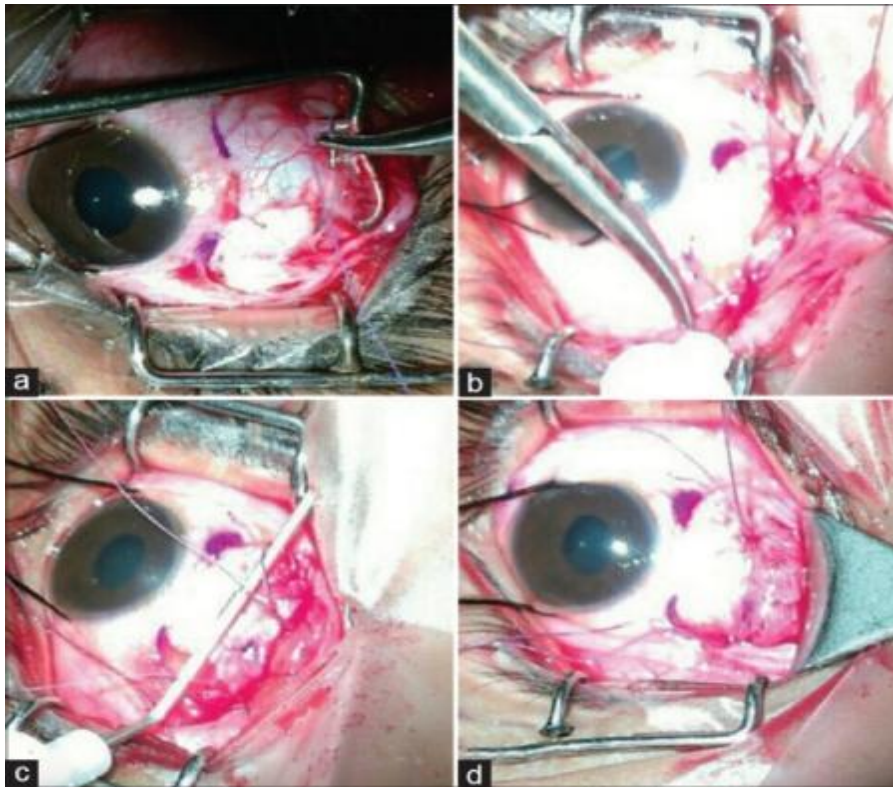


Figure (1): Steps of plication: (a) Passing the locking sutures in rectus muscle at the desired position, (b) passing partial thickness scleral sutures at each end of muscle insertion, (c) folding the muscle on the global aspect with the help of wide bore needle, (d) the plicated muscle

Postoperative management: Postoperative medications included a combination of antibiotic steroid eye drops 4 times daily and combined antibiotic/steroid eye ointment by night.

Follow up: The patients were seen postoperatively on 1 day, 1 week and every month for six months following surgery. In the follow-up visits, the postoperative alignment was evaluated using prisms and cover. Any postoperative complication was also reported.

Statistical analysis

Recorded data were analyzed using the statistical package for social sciences, version 20.0 (SPSS Inc., Chicago, Illinois, USA). Quantitative data were expressed as mean±standard deviation (SD). Qualitative data were expressed as frequency and percentage.

The following tests were done:

- Independent-samples t-test of significance was used when comparing between two means.
 - Chi-square (χ^2) test of significance was used in order to compare proportions between two qualitative parameters.
 - The confidence interval was set to 95% and the margin of error accepted was set to 5%. The p-value was considered significant as the following:
 - Probability (P-value)
- P-value <0.05 was considered significant.

- P-value <0.001 was considered as highly significant.
- P-value >0.05 was considered insignificant.

RESULTS

This study was carried out in the Ophthalmology department, in Al-Zahraa Hospital in Al-Azhar University and Research institute of ophthalmology between October 2015 and May 2017.

Table (1): Classification of studied patients according to type of surgery

Variables		Tucking	Resection
Studied patients	N	20	20
	%	50%	50%

This table show that 20 patients were subjected to tucking surgery and 20 patients were subjected was subjected to resection surgery.

Table (2): Comparison between studied groups as regard age

Variables		Tucking (N = 20)	Resection (N = 20)	P-value
Age (years)	Mean	20.6	22.9	0.6
	±SD	11.4	12.4	

This table shows no statistical significant difference (p-value > 0.05) between studied groups as regard age.

Table (3): Comparison between studied groups as regard follow up.

Variables		Tucking (N = 20)	Resection (N = 20)	P-value
Follow up	Ortho	18 (90%)	16 (80%)	0.4
	Under correction	4 (20%)	2 (10%)	

This table shows no statistical significant difference (**p-value > 0.05**) between studied groups as regard follow up.

Table (4): Comparison between studied groups as regard postoperative lump.

Variables		Tucking (N = 20)	Resection (N = 20)	P-value
P.O Lump	No	8 (40%)	20 (100%)	< 0.001*
	Yes	12 (60%)	0 (0%)	

*: p-value < 0.001 is considered highly significant.

This table shows highly statistical significant difference (**p-value < 0.001**) between studied groups as regard postoperative lump.

Table (5): Comparison between studied groups as regard postoperative ischemia.

Variables		Tucking (N = 20)	Resection (N = 20)	P-value
P.O ischemia	No	20 (100%)	20 (100%)	1
	Yes	0 (0%)	0 (0%)	

This table shows no statistical significant difference between studied groups as regard postoperative ischemia.

Examples of preoperative and postoperative cases:

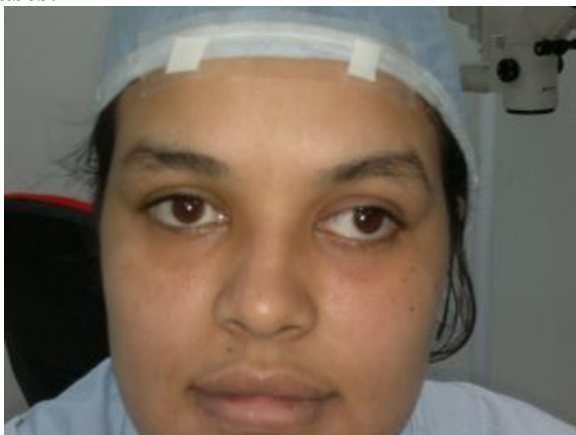

Figure (2): Lt. sensory exotropia underwent Lt. lateral rectus recession 7 mm and medial rectus tucking 5 mm.

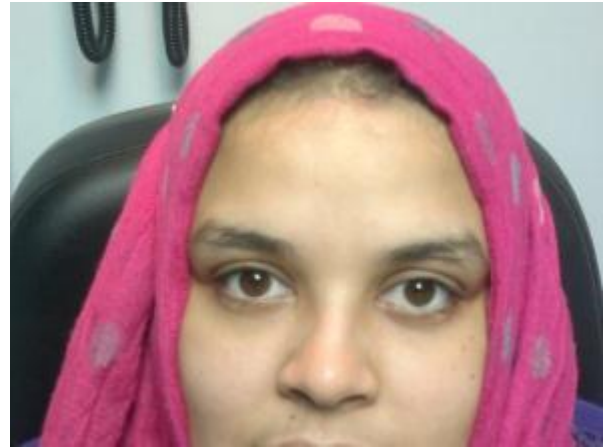

Figure (3): Postoperative orthotropia in primary position.

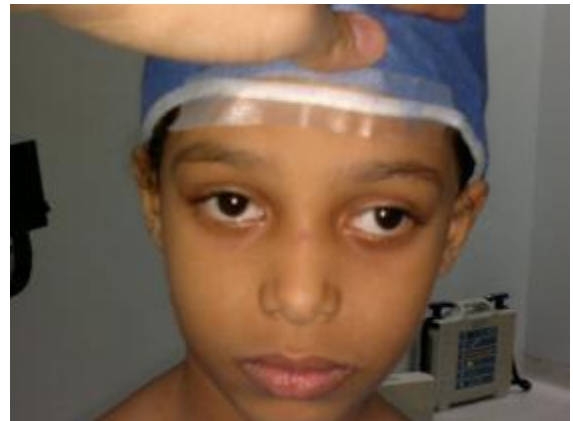

Figure (4): Intermittent exotropia poor control underwent Lt. lateral rectus recession 7 mm and medial rectus tucking 5 mm.

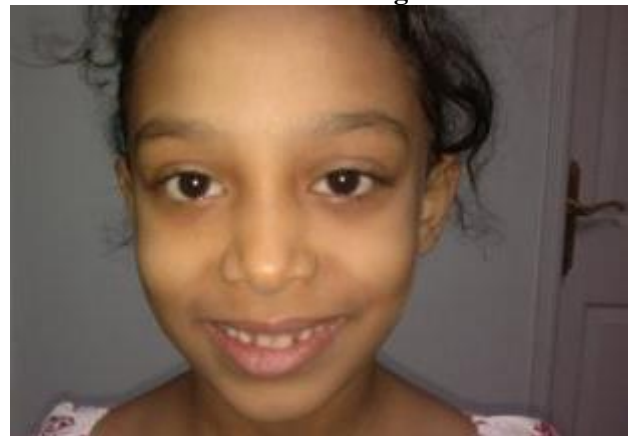

Figure (5): Postoperative result.



Figure (6): Lt. sensory exotropia underwent bilateral lateral rectus recession 9 mm and right medial rectus tucking 6 mm.

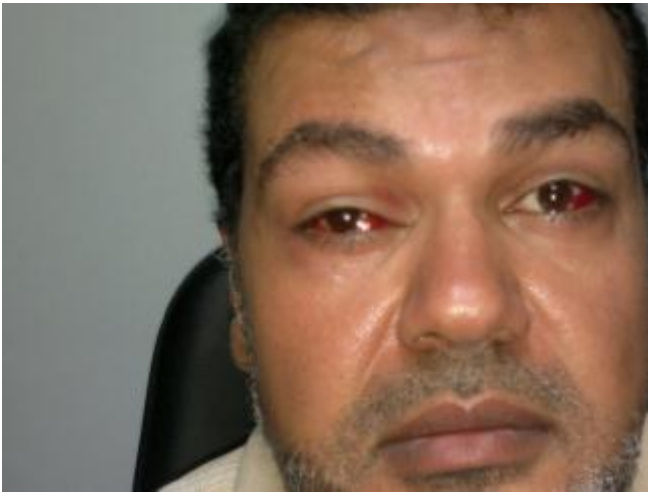

Figure (7): Postoperative result.

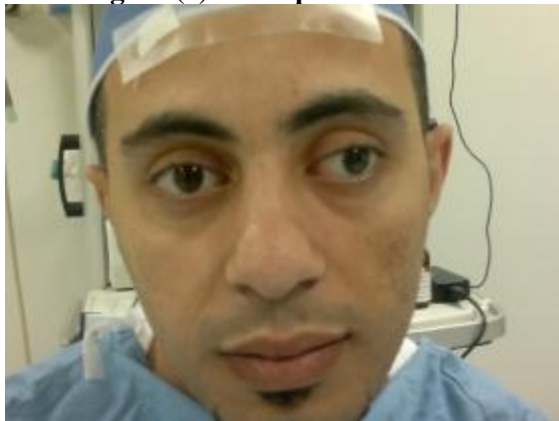

Figure (8): Intermittent exotropia poor control underwent Lt. lateral rectus recession 9 mm and medial rectus tucking 6 mm.




Figure (9): Result after 6 months of follow up.

Discussion

Patient's ages ranged from 2 to 40 years. We selected this wide range of ages to observe the effect of plication in both young and adult patients, and also there was a difference in the duration of squint of all patients.

In our study there were 23 patients with exotropia suffering from convergence weakness, we

excluded exotropic patients with divergence excess from our study because those patients needs bilateral lateral rectus recession but in our study we strengthen the two medial rectus muscles of both eyes to strengthen convergence.

There were 17 patients with non-accommodative esotropia. We selected esotropic patient to study plication effect on lateral rectus muscle.

The angle of squint ranged from 30-65 prism dioptre. This range of deviation needs strengthening of 2 muscles for correction according to the primary deviation.

We encountered a few complications in our study; three of them were related to the plication technique. These were the postoperative lump, and suture complications in the form of suture cutting while tightening the muscle to its final place, and suture tearing through the sclera also during tightening of the suture and initial residual angle of under correction. The plicated part was folded externally toward the conjunctiva in this study with a cosmetically noticeable postoperative lump was apparent in 15 patients.

In our study, the postoperative lump related to the effect of plication was noted and we tried to find a relation between it and the amount of plication and the muscle plicated.

In this study the lump disappeared by the third month of the follow up. This is in contrast with the reported literature by **Wright**⁽¹⁾ that stated that the lump flattened over 6 weeks without leaving any cosmetic problems.

Inadvertent disruption of the anterior ciliary arteries did not occur in any of our cases, although this complication was encountered by **Wright and Lanier**⁽⁹⁾ in their study on animal models while dissecting the check ligaments of the inferior rectus muscle. This may be explained by our use of the operating surgical microscope or magnifying loop in most of plication cases that we did, which made visualization of the vessels easier⁽⁹⁾.

While ASI is a rare complication of strabismus surgery, its significant consequences force surgeons to be cautious when operating on several rectus muscles or in patients with vascular risk factors. Reported complications range from mild, self-limited iritis to severe ischemic changes, such as iris atrophy, keratopathy, posterior synechiae, cataract and even phthisis bulbi⁽¹⁰⁾.

In our study, other complications that, we encountered were not specific to the plication technique. They included exposure of Tenon's capsule, tearing of the conjunctive and premature locking of the sutures.

In our study, prolapse of Tenon's capsule occurred in one of our patients, but it was so small that it needed no treatment and it shrink back to its

original site under the conjunctiva. This was supported by **Helveston**⁽¹¹⁾ who stated that the prolapsed Tenon's capsule would shrink back into the conjunctival wound, unless it is excessive then it should be excised and the conjunctiva overlying it sutured.

The plication techniques certainly offers many advantages that make it an appropriate choice for certain situations. With this technique, there is preservation of the anterior ciliary blood flow, which decreases the incidence of (ASI). This makes the plication a favorable choice when we operate on multiple recti at the same time (horizontal and vertical). It is also helpful when operating on certain types of patients with blood dyscrasias, hypercoagulability states, dysthyroid ophthalmopathy or carotid artery disease⁽¹¹⁾.

However, **Alkharashi and Hunter**⁽⁸⁾ concluded that the modified rectus tuck does not have to be preferred over standard resection for reasons of blood supply, yet their conclusions could be challenged by the fact that their study included children who were not at risk of developing ASI and it was conducted on two rectus muscles, while it is known that operating on two rectus muscles is considered safe and provided no risk of ASI⁽⁸⁾.

We found study, by **Chaudhuri and Demer**⁽¹⁰⁾, in which the author compares the surgical outcomes of resection and plication. Like us, they found no significant differences in the postoperative surgical outcomes between patients plicated and/or resected. Their study involved a series of 22 patients (17 males and 5 females) undergoing plications (either bilateral or combined with recession of the antagonist), compared to 31 historical controls (14 males and 17 females) who had undergone resections (again either bilateral or combined with the recessions of the antagonist). Their technique of rectus muscle plication was similar to the technique used in our study. At last follow-up, like our study, similar outcomes were reported both among esotropes and exotropes, whether the patients were resected or plicated. The preoperative deviation in Chaudhuri and Demer's study was of lesser amount as compared to our study; therefore, the amount of muscle plicated, resected, and recessed was also of lesser amount in their study as compared to ours. Our patients were fewer: 40 overall as compared to 53 of Chaudhuri and Demer's. Interestingly, Chaudhuri and Demer included reoperations in their study, whereas we excluded such patients⁽¹⁰⁾.

In a small retrospective case series involving five patients, **Velez et al.**⁽¹²⁾ described plication using adjustable sutures. Their steps for plication were similar to our study. The mean age of patients was 49 years. Of the five patients, three underwent lateral rectus plication and two underwent superior rectus plication. The amount of

plication ranged from 5.5 mm to 7 mm for lateral rectus and 3 mm to 4 mm for superior rectus. All patients had satisfactory alignment within six prism diopters (PD) for horizontal deviation and two PD for vertical deviation⁽¹²⁾.

Our study did not include any change in anterior segment circulation and the time taken for both the procedures although other studies reported plication as being quicker and better in preserving the vascularity of anterior segment⁽¹³⁾.

Plication also has certain benefits over resection: it is far less bloody, with diminished chance of anterior segment ischemia. Moreover, since muscle plication does not require any disinsertion of the EOM from the globe, it has no risk of "slipped" or "lost" muscles in the postoperative period. Moreover, since it is less "invasive," it does appear technically easier than a resection⁽¹³⁾.

In our study with muscle-scleral plication, we do not get a surgically induced A-V pattern as the insertion of the muscle does not change. However, we also cannot correct an A-V pattern by transposing the muscle insertion either. As for the bulky lump that appears with this procedure, it will flatten after a few months leaving no trace and will become cosmetically indistinguishable from resection.

We found the plication technique is not very difficult to master after a short period of time.

Conclusion

From the results of this study, it can be concluded that the muscle-scleral plication technique is an easy alternative to resection that can be used on horizontal muscles especially when anterior ciliary vessels sparing is needed.

The muscle scleral plication has the same effect as resection as obvious by the similar success rate. Its stability is good and is comparable to the resection. It has the advantages of sparing the anterior ciliary vessels which makes it a tempting choice of surgery in patients with dysthyroid ophthalmopathy, blood dyscrasias, carotid artery disease and with those patients who had previous muscle surgery involving other horizontal or vertical recti i.e., patients with a risk of developing anterior segment ischemia.

Plication also eliminates the possibility of muscle slippage, which makes it convenient for residents or surgeons not familiar with strabismus surgery. It reduces bleeding and cauterization during surgery.

The procedure is also potentially reversible within the first few days of surgery. The unsightly muscle bulk that is produced by this technique disappears all together within 3 months of surgery.

It can be seen that muscle scleral plication presents an easy, stable, safe technique that can

replace resection under certain circumstances where there is risk of anterior segment ischemia or muscle slippage.

REFERENCES

1. **Wright KW (2007):** Color Atlas of strabismus surgery strategies and techniques. 2^d ed. Ed. Bosnall. LB. & Kiss T. Panama: JP, Lioppincott.
2. **Helveston EM (1993):** Brown syndrome: anatomic considerations and pathophysiology. *Am Orthopt J.*, 43:31-35.
3. **Saunders RA, Bluestein EC, Wilson ME *et al.* (1994):** Anterior segment ischemia after strabismus surgery. *Ophthalmology*, 95: 533-537.
4. **Hamtil LW (1983):** A study in tucking extraocular muscles to correct strabismus. *Ann Ophthalmol.*, 15: 135-137.
5. **Yoo S, Pineles SR and Velez FG (2012):** Rectus Muscle Resection in graves ophthalmopathy ARVO. FT Lauderdale, Florida, USA.
6. **Mojon DS (2010):** A modified technique for rectus muscle plication in minimally invasive strabismus surgery. *Ophthalmologica*, 224:236-42.
7. **Mojon DS (2008):** Minimal invasive squint surgery for horizontal rectus muscle reoperations. *Br J Ophthalmol.*, 92: 1648-52.
8. **Alkharashi M, Hunter DG (2017):** Reduced surgical success rate of rectus muscle plication compared to resection. *J AAPOS.*, 21(3):201-204.
9. **Wright KW, Lanier AB (1991):** Effect of a modified rectus tuck on anterior segment circulation in monkeys. *J Pediatr Ophthalmol.*, 28: 77-81.
10. **Chaudhuri Z, Demer JL (2014):** Surgical outcomes following rectus muscle plication. *Ophthalmol.*, 132:579–85.
11. **Helveston EM (2005):** Surgical anatomy and resection technique of a rectus muscle Atlas of strabismus surgery. 3^d ed. Ed. Klein EA. St. Louis: Mosby, PP. 141-161.
12. **Velez FG, Demer JL, Pihlblad MS *et al.* (2013).** Rectus muscle plication using an adjustable suture technique. *J AAPOS.*, 17:480-3.
13. **Oltra EZ, Pineles SL, Demer JL *et al.* (2015):** The effect of rectus muscle recession, resection and plication on anterior segment circulation in humans. *Br J Ophthalmol.*, 99:556-60.
14. **Yoo SH, Pineles SL, Goldberg RA *et al.* (2013):** Rectus muscle resection in Graves' ophthalmopathy. *J AAPOS.*, 17(1):9-15.