

An Overview about Mitral Valve Replacement Surgery Options: Review Article

Amany G. Abdallah, Amr Tawfek, Wisam Ashour Alsadiq*,
Mamdouh Elsharawy, Nabil Alsadik, Dina Said Shemais

Department of Cardiothoracic Surgery, Faculty of Medicine, Zagazig University, Egypt

*Corresponding author: Wisam Ashour Alsadiq, Mobile: (+20) 01151942408, E-mail: dr.wisam.cardiothoracic@gmail.com

ABSTRACT

Background: For many years, median sternotomy has been the gold standard for doing any kind of open-heart surgery. The standard full sternotomy method to mitral valve surgery has been shown to be unnecessary, and minimally invasive surgery has been shown to be a viable option with reduced perioperative morbidity as well as short-term mortality.

Objective: Review of literature about Mitral Valve Replacement Surgery Options.

Methods: We searched PubMed, Google Scholar, and Science Direct for relevant articles on Mitral Valve Replacement Surgery Options. Only the most recent or thorough study was taken into account between October 2011 and February 2023. Documents written in languages other than English have been ignored due to lack of translation funds. Unpublished works, oral presentations, conference abstracts, and dissertations were generally agreed upon not to qualify as scientific research.

Conclusion: By minimizing the need for large incisions and the associated risks of blood loss, pain, and infection, minimally invasive surgery has gained popularity and has been shown to be effective in a large number of patients undergoing mitral valve surgery. This method provides superior cosmetic outcomes, lowers the risk of sternal infection, minimises pain, necessitates fewer blood transfusions, speeds healing, and shortens the length of hospital staying.

Keywords: Mitral valve replacement, Mitral regurgitation, Open-heart surgery.

INTRODUCTION

The median sternotomy, the most common method of open-heart surgery, has been criticised for being too lengthy, painful, and dangerous. Mitral valve surgery is decided based on the patient's condition, comorbidities, illness severity, surgeon's experience, and treatment facility. Capabilities beyond those required for cardiopulmonary bypass or sternotomy are necessary for less invasive cardiac treatments. Minimally invasive heart valve surgery was first criticised due to the expectation of poor results from tiny incisions ⁽¹⁾.

Minimally invasive techniques like mitral valve surgery are gaining popularity because of the burden they put on patients. Safe, low-morbidity, and reoperation rates are all associated with minimally invasive mitral valve surgery. It has the potential to replace a full sternotomy because it is less invasive, hastens healing, boosts patient satisfaction, and reduces costs without compromising efficiency. Thoracic endoscopy-assisted minimally invasive mitral valve repair, many mitral valve procedures benefit from this technique's improved aesthetics and decreased sternal infection, pain, blood transfusion, and hospital stay rates ⁽²⁾.

Mitral valve surgery anatomy

The components of a healthy mitral valve (MV) are the annulus, leaflets, chordae tendinae, papillary muscles, and chambers. During diastole, its complicated shape allows blood to flow into the left ventricle (LV), whereas during systole, it prevents blood from flowing backwards from the LA into the LV. The proper operation of MV depends on the consistency and coordination of these parts ^(3, 4). Interstitial cells that respond to mechanotransduction and endothelial cells

on the valve surface work together to keep the valves in proper mechanical and metabolic shape ⁽⁵⁾.

Mitral annulus: During systole, the fibrous mitral annulus contracts like a sphincter, restricting the size of the mitral valve. An inability to completely close the mitral valve due to dilation, especially at the point of posterior leaflet insertion ⁽⁶⁾.

Leaflets: The mitral valve has two leaflets, one in front and one in back. The anterior leaflet occupies two-thirds of the valve opening and one-third of the annular ring. It's the thicker, zonal posterior leaflet that wraps around the annulus. Histologically, leaflets are composed of the fibrosa, atrial, and spongiosa tissues ⁽⁶⁾.

Chordae Tendinae: Main and secondary chordae tendinae make up the subvalvular apparatus. Primary chordae that are thinner avoid edge prolapse, while secondary chordae that are thicker reduce leaflet tension ⁽⁶⁾.

Papillary muscles: During systole, the papillary muscles contract and the chordae tendinae shorten to shut the mitral valve and prevent regurgitation. The anterior and posterior papillary muscles help hold the mitral valve in place ^(6, 7).

The left atrium: The left atrium sits above the left ventricle and is situated behind the right atrium. The pulmonary veins supply it with oxygenated blood ⁽⁸⁾.

The left ventricle: The left ventricle, located in the left lower quadrant of the heart, has thick walls and a rounded tip. The aortic valve is reached via the mitral valve mechanism ⁽⁹⁾.

Blood and lymphatics: The anterior papillary muscle is fed by the anterior descending and circumflex arteries. The posterior papillary muscle is nourished by tributaries of the right coronary artery. The left atrium receives oxygenated blood from the pulmonary veins, whereas the left ventricle receives deoxygenated blood from the left coronary artery ⁽⁶⁾.

Nerves: Mitral valve stiffness is reduced by acetylcholine and increased by norepinephrine. Valve innervation weakens with age ⁽¹⁰⁾.

Mitral valve disease pathophysiology

Mitral Stenosis: Left atrial pressure, pulmonary venous pressure, and dyspnea are all exacerbated by physical activity, emotional stress, and atrial fibrillation in patients with mitral stenosis (MS), which is most typically rheumatic and occurs when the mitral valve area is less than 2 cm² ⁽¹¹⁾.

Mitral regurgitation (MR): An aperture larger than the aortic orifice is deadly in cases of mitral regurgitation (MR). The vicious loop of chronic MR leads to left ventricular dilation and a larger regurgitant orifice. Compatibility between the pulmonary vein bed and the left atrium affects MR appearance ⁽¹²⁾.

Natural history: Treatment for MS symptoms like dyspnea slows the disease's progression to higher levels of function. Pre-surgery 5-year survival rates for New York Heart Association (NYHA) stages III and IV were 62% and 15%, respectively. The progression of MR is determined by its severity, ventricular function, and valve dysfunction. The prognosis is bad for patients with severe MR and impaired cardiac function, yet mitral valve prolapse can be tolerated for years before surgery ⁽¹³⁾.

Clinical signs and diagnosis: Symptoms of MS include difficulty breathing, fatigue, low exercise tolerance, bleeding gums, and chest pain. Until left ventricular failure occurs, people with chronic MR have no symptoms. Transesophageal echocardiography (TEE) and echocardiography are used to confirm the diagnosis if they are necessary. The results of angiograms rule out coronary artery disease ⁽¹⁴⁾.

Treatment

Mitral stenosis: Medications such as salt restriction, diuretics, warfarin as well as beta-blockers for atrial fibrillation are beneficial for people with MS. Mitral valve repair or percutaneous balloon valvotomy is performed depending on the patient's condition. In

severe cases of fibrosis, a new valve may be necessary ⁽¹⁵⁾.

Mitral insufficiency: For both acute and chronic MR, nitroprusside is required for cardiogenic shock and afterload reduction. When symptoms arise from MR, surgery is required; those under 50 years of age typically opt for repair, while those in NYHA functional groups III and IV favour replacement. The decision to repair a mitral valve depends on the patient's pathology and the surgeon's expertise. Long-term rheumatic MR correction that is less than ideal. It is reasonable to treat MR caused by prolapse. Details of prolapse and the viability of repair can be determined by TEE ⁽¹⁶⁾.

Mitral valve surgery indications: Treatments in Class I are generally agreed upon as effective by both the American Heart Association and the European Society of Cardiology. Reckless or hazardous methods are prohibited by Class III regulations ⁽¹⁷⁾. In the hands of a trained professional, mitral valve repair that includes leaflet excision, chordal transfer or replacement, edge-to-edge suturing, and annuloplasty to address pathophysiology, has a success rate of greater than 95%. In the event that the mitral valve cannot be repaired, a replacement can be performed while the attachments of the annulus to the papillary muscles are preserved. These suggestions are supported by randomised trials, non-random studies, and consensus assessments ⁽¹⁸⁾.

Regurgitation guidelines for mitral valve surgery: Mitral valve surgery is advised for patients with symptomatic chronic severe primary mitral regurgitation (MR) and LVEF > 30%. Repair is advantageous for LV preservation and lower surgical mortality. Therefore, it should be considered for symptomatic patients with chronic severe MR, LVEF 30-60%, or LVESD more than 40 mm. When dealing with chronic, severe, primary MR of the posterior leaflet, mitral valve repair is preferable to replacement. Patients who need extensive repairs may benefit from a mechanical prosthesis. When MR is severe and persistent, surgery to replace the mitral valve is suggested. Sustained LV function, new-onset atrial fibrillation, or resting pulmonary hypertension are all conditions that may be improved by treating silent chronic severe non-rheumatic primary MR (PMR). Repair for rheumatic MR involves anticoagulation and durability ⁽¹⁹⁾.

ESC/EACTS recommendations on indications for intervention in severe primary mitral regurgitation: Figure (1) indicate the ESC/EACTS-recommended surgical indications for severe chronic PMR.

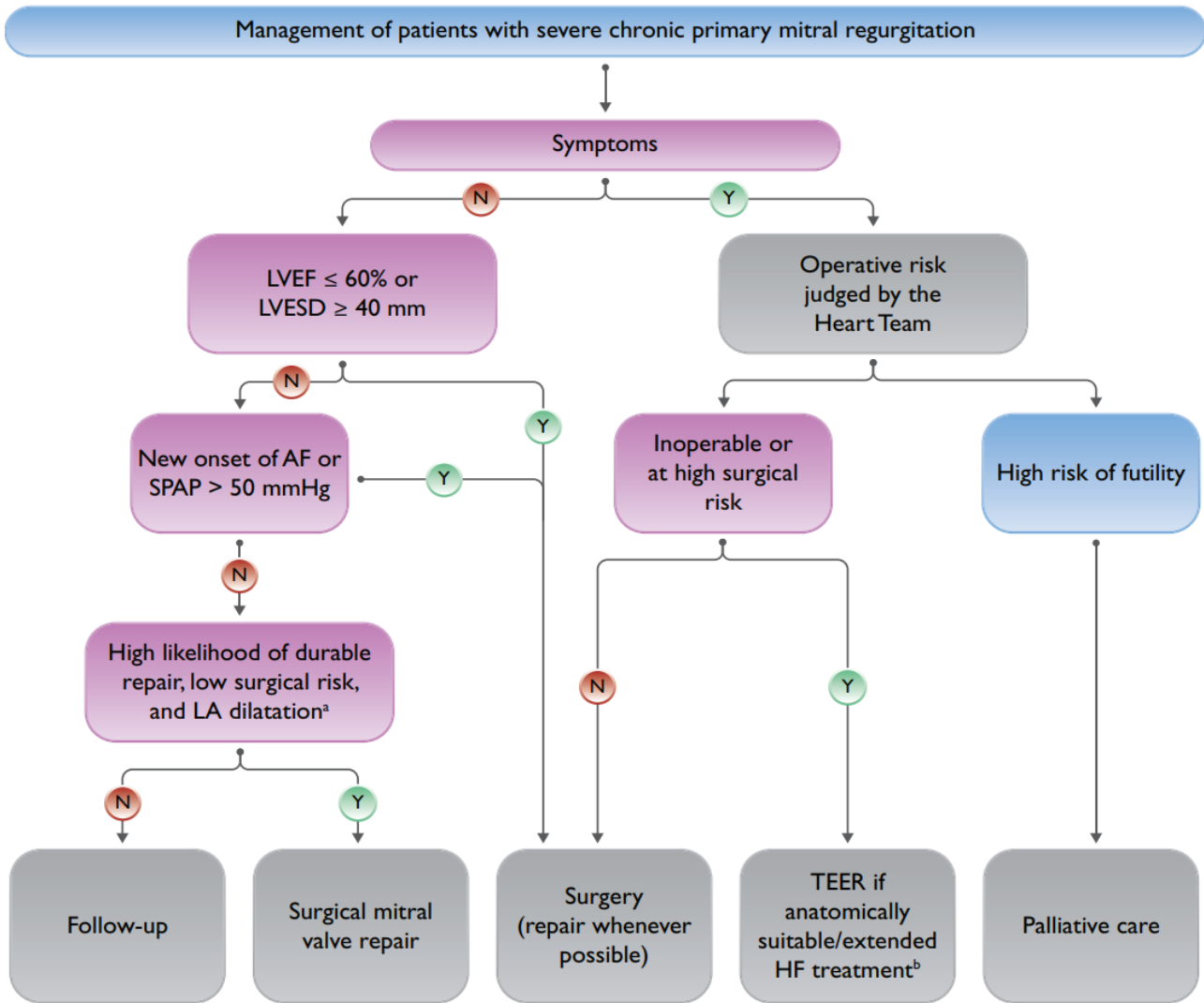


Fig. (1): How to treat people with severe, chronic, primary mitral regurgitation ⁽²⁰⁾.

Mitral stenosis and surgical indications:

Patients with severe mitral stenosis symptoms (NYHA functional class III or IV) and mitral valve area (MVA) 1.5 cm² who are not high surgery risk and who are either ineligible for or have failed percutaneous mitral balloon commissurotomy should consider mitral valve surgery (repair, commissurotomy, or replacement). Replacement is typically preferred when the entire mitral valve complex is severely thickened and calcified. MS worsens slowly, therefore surgical intervention isn't recommended until patients experience severe symptoms (NYHA class III or IV) ⁽²¹⁾.

When a patient undergoing cardiac surgery for another cause has severe MS (MVA 1.5 cm²), it is recommended that they also have concomitant mitral valve surgery. For those who have an MVA between 1.6 and 2.0 cm², it could be an option. Mitral valve surgery in conjunction with left atrial appendage excision should be considered for individuals with severe MS and recurrent embolic episodes despite sufficient anticoagulation ⁽²²⁾.

Mitral valve replacement

Technique and anesthesia for conventional median sternotomy mitral valve surgery:

Anesthesia used during major surgery. In some cases, a double-lumen endotracheal tube is required for single-lung breathing. An adequate amount of anaesthetic is given prior to a sternotomy in order to prevent stimulation. Pre-sternal lung deflation. Large venous access and matched blood must be available for re-exploration sternotomy due to the danger of hemorrhage. Patient is rolled between the scapulae to facilitate access to the sternum while lying supine. Exposure is improved by extending the neck and raising the sternal notch ⁽²³⁾.

Obesity is associated with a paucity of jugulum and xiphoid markers. In young women, an incision from the sternal notch to the xiphoid tip, above the linea alba, can be used for either a coronary artery bypass graft (CABG) exposure or for cosmetic purposes. The incision is made 2 cm below the xiphisternum, under the suprasternal notch. Diathermy for fat and a knife for skin. After cutting the pectoral major muscles from the periosteum to the outside sternum, make sure there is no

bleeding. Using a knife, scissors, or saw, sever the xiphisternum down the middle. Suprasternal augmentation and interclavicular ligament separation using diathermy ⁽²⁴⁾.

The xiphoid and jugular are medial structures. Suture the midline and cut the subcutaneous and pectoral fascia. Using the sternochondral connections and the midline intercostal spaces, you can access the periosteum. Bleeding can be stopped by snipping the transverse venous arch at the jugulum. Dissect the interclavicular ligament and retract the sternum. Mark the midline, and then cut the linea alba to separate the xiphoid from the diaphragm. Stop bleeding from an upward sawing by cutting the xiphoid with scissors and cauterising any crossing veins ⁽²⁵⁾.

Osteotomy planning for the jugulum, xiphoid, and midline. The operating room is outfitted with an air or electric saw. Anesthesiologists prevent pleural rupture by cutting off oxygen. Above-down osteotomy is the option chosen by the surgeon. Sawed away at the ectatic ascending aorta, while protecting the pleura, pericardium, innominate vein, and brachiocephalic artery. Closure and healing require proper midline sternum division. Incorrect division may necessitate osteosynthesis with plates ⁽²⁶⁾.

Cauterizing small punctures and stuffing gauze between the pericardium and the sternal borders can help stop bleeding and prevent necrosis during the retraction/bleeding control process. Cut back on the bone wax. Tense muscle strains can be avoided with the help of towels, gloves, and a cautious approach to retraction. Fractures and postoperative pain can be avoided by retracing the sternum slowly. Patients benefit from muscle relaxants and sternopericardial ligament relaxation.

In order to begin mitral valve replacement, central and arterial cannulation, pericardial opening, and heparin are required. Aortic root cardioplegia is achieved by cross-clamping the distal ascending aorta. In a right-sided rotation, the left atrium of the heart is on display. The MV can be located by performing an atriotomy from the left atrium anterior to the right pulmonary veins. Fixing a leaking mitral valve. Replacement of the affected leaflets or artificial chordae may be necessary. To prevent annular dilatation during surgical mitral valve repair, ring annuloplasty is performed. To test the LV, fill it with salt water. If the valve cannot be repaired, a mechanical or biological prosthesis must be inserted. Left heart deairing with subsequent close atriotomy. The patient is taken off of cardiopulmonary bypass, heparin, and cannulas. Valve function and paravalvular regurgitation can be detected by sternal wire transesophageal echocardiography. After cardiac surgery, 24 F tubes are inserted below the rectus muscle fascia through epigastric incisions, completing the sternal closure. Towel covering the right ventricle of the chest. Avoid overriding and graft damage by meticulously placing 4-8 stainless steel wires. Removing bone wax can prevent healing issues.

Wire ends can cause problems if not approximation, forced, twisted, cut, and buried correctly ⁽²⁷⁾.

Repair tissue and wounds: To achieve a complete closure, it is necessary to re-approach the linea alba. Seal the wound using absorbable sutures or clips after stitching through both layers of the pectoral fascia. A re-thoracotomy or more clips may be necessary to prevent dehiscence and infection in patients with large breasts or obesity. Plaster the wound for 5 days while keeping it clean with iodine. Patients at risk of contracting an illness can have their bodies held still for up to four weeks by using a thoracic vest ⁽²⁸⁾.

Outcomes

Even though it's not the least invasive option, this is the gold standard. The use of MIMVS is on the rise as a means of lowering risk. The six-inch incision required for a conventional median sternotomy is painful and slows healing. Pain, swelling, and scarring at the incision site are possible. The prolonged hospital stay is another challenge, since patients must be closely monitored for several days and then spend weeks recovering at home. This makes it difficult to get anything done. The risks of infection, bleeding, and tissue damage from the operation outweigh those from less invasive alternatives. Professional surgeons can reduce but not eliminate dangers. The risk of developing pneumonia or a blood clot following surgery increases with bed rest. Physical activity may be restricted for several weeks or months as recuperation from more invasive procedures might take longer ⁽²⁹⁾.

Minimal mitral valve replacement

No sternotomy and small incisions are necessary for minimally invasive cardiac surgery. Helps cut down on bleeding, breathing difficulties, hospital stays, and pain. There are four invasiveness levels. Mini-thoracotomy to the right chest is a common technique, among others. Needs lengthy implements. Direct or primary vision is provided by cameras (2D or 3D) without the need for rib-spreading ⁽²⁹⁾.

Technique/Details/Operative steps

Preoperative evaluation and cardiac workup:

The impact of aortic regurgitation on anterograde cardioplegia is the primary focus of transthoracic echocardiography (TTE) in determining surgical planning. After an inconclusive transthoracic echocardiogram (TTE), a transesophageal echocardiogram (TEE) is required for surgical guidance, however its contraindications limit the applicability of a minimally invasive approach. Radial coronary angiography is preferable to femoral angiography before surgery in order to preserve femoral access ⁽³⁰⁾.

Vascular checkup: Peripheral cannulation for minimally invasive mitral valve surgery (MIMVS) is

performed through the femoral artery. For the vascular workup, surgical teams may opt for either an aortic or coronary CT scan ⁽³⁰⁾.

Thoracic Exam: The thoracic workup is directed by the patient's history and chest X-ray. Adhesions in the pleura can make it difficult to reach the left atrium. The incision site and skin condition are evaluated the day before surgery ⁽³⁰⁾.

Patient preparation and anesthesia: Standardization is necessary for cooperation between anesthesiologists, nurses, and surgeons. Similar to valvular operations, anaesthesia involves the use of a central line, an arterial catheter, and endotracheal intubation. Ventilation can be stopped early if cardiopulmonary bypass and peripheral cannulation are performed. Thoracotomy restrictions necessitate the use of transcutaneous defibrillation pads. Two venous cannulation stages are typically required for right cavity drainage as determined by TEE ⁽³¹⁾.

Patient positioning and room setup: The patient is supine with a gel bolster under his or her shoulders and the right arm flexed at the hip. With the suitable body orientation, skin preparation, and draping, the surgical field (right thorax to midaxillary line, both groins) is easily accessible. The sterile sternum is kept in place during the sternotomy procedure. After surgery, women can see their inframammary groove by lifting their right breast using adhesive films, while men can move their areola to the fourth right intercostal space. A thoracoscopic tower, long-shafted equipment, retractors, and disposables are all housed in the space ⁽³¹⁾.

Steps in surgery cannulation peripheral: Site-selection markers and a minimally invasive incision (often the fourth intercostal gap on the right) are used for this procedure. If you want to prevent fractures or nerve damage, you shouldn't use intercostal spacers. Additional incisions are required for CO₂ insufflation, a thoracoscope, an aortic clamp, an atrial retractor, and a pericardium suspension. Careful incision selection has been shown to decrease mortality ⁽³¹⁾.

Cardiopulmonary bypass and cardiac exposure surgery: When the thoracic incision was made, good, activated clotting time was allowed before CPB was initiated. After the aorta has been clamped, the pericardium is incised and the arteries and veins are cannulated. The cardioplegia cannula is placed in the aorta anterior to the aortic purse string. Vascular injury can be avoided when clamping the transverse sinus. Crystalloid cardioplegia, as practised clinically. If the mitral valve is opened, blood will drain through an opening in the left atrium just posterior to the syndergaard interatrial groove. Valvular exposure is improved with the aid of the mitral retractor ⁽³²⁾.

End of procedure and results: Left atrial obstruction after aortic clamp release calls for close monitoring. TEE gives his opinion on the cost of maintenance. Thoracic drains inserted, blood loss controlled, bypass withdrawal begun. Closed layers, intravenous sedation, and a reduced intercostal gap ⁽³³⁾. Within a week of surgery, patients typically have no further difficulties and can leave the intensive care unit. For most mitral abnormalities, minimally invasive mitral valve surgery (MIMVS) is a viable treatment option, with repair rates and functional status on par with those after sternotomy ⁽³⁴⁾.

CONCLUSION

By minimizing the need for large incisions and the associated risks of blood loss, pain, and infection, minimally invasive surgery has gained popularity in recent years. This technique has been shown to be effective in a large number of patients undergoing mitral valve surgery, and its benefits have been lauded for their aesthetic quality, decreased risk of infection in the chest wall (the sternum), reduced pain after surgery, and shorter recovery times.

Supporting and sponsoring financially: Nil.

Competing interests: Nil.

REFERENCES

1. **Salik I, Lee L, Widrich J (2022):** Mitral Valve Repair. Treasure Island (FL): StatPearls Publishing. <https://www.ncbi.nlm.nih.gov/books/NBK549879/>
2. **Gupta P, Porwal M (2022):** Minimally invasive mitral valve replacement (MIMVR) through right minithoracotomy: a single-center experience from central India. <https://doi.org/10.32553/ijmbs.v6i1.2371>
3. **Nicoletti I, Avallato C, Locatelli A (2019):** Mitral Valve. Textbook of Echocardiography for Intensivists and Emergency Physicians. 2nd edition, Pp: 173-186. <https://link.springer.com/content/pdf/10.1007/978-3-319-99891-6.pdf>
4. **Sidebotham D, Allen S, Gerber I et al. (2014):** Intraoperative transesophageal echocardiography for surgical repair of mitral regurgitation. *J Am Soc Echocardiogr.*, 27: 345–66
5. **Goode D, Dhaliwal R, Mohammadi H (2020):** Transcatheter mitral valve replacement: state of the art. *Cardiovascular Engineering and Technology*, 11: 229-253.
6. **Vaca F, Bordoni B (2022):** Anatomy, Thorax, Mitral Valve. In StatPearls. StatPearls Publishing. <https://www.ncbi.nlm.nih.gov/books/NBK549884/>
7. **Rich N, Khan Y (2021):** Anatomy, thorax, heart papillary muscles. In StatPearls. StatPearls Publishing. <https://www.ncbi.nlm.nih.gov/books/NBK557802/>
8. **Whiteman S, Alimi Y, Carrasco M et al. (2021):** Anatomy of the cardiac chambers: A review of the left ventricle. *Translational Research in Anatomy*, 23: 100095. <https://doi.org/10.1016/j.tria.2020.100095>
9. **Takla M, Youssef D, Andonakakis A et al. (2021):** Basic Cardiovascular Anatomy. In *Cardiac Anesthesia: The Basics of Evaluation and Management*. Springer

- International Publishing. pp. 3-19. DOI:10.1007/978-3-030-51755-7_1
10. **Bordoni B (2023):** Anatomy, Thorax, Mitral Valve. In: StatPearls. Treasure Island (FL): StatPearls Publishing. <https://pubmed.ncbi.nlm.nih.gov/31751074/>
 11. **Rimsukcharoenchai C, Pandis D, El-Eshmawi A et al. (2021):** Complex mitral valve regurgitation: surgical evaluation, complex approach and repair techniques. *J Vis Surg.*, 7: 15-19.
 12. **Chaudhari S, Mani B (2022):** Mitral Valve Insufficiency. In StatPearls. StatPearls Publishing. <https://www.ncbi.nlm.nih.gov/books/NBK557898/>
 13. **Watanabe N (2019):** Acute mitral regurgitation. *Heart*, 105 (9): 671-677.
 14. **Steitieh D (2023):** Imaging findings of mitral arcade. *J Clin Med Img Case Rep.*, 3 (1): 1365-69.
 15. **Shah S, Sharma S (2022):** Mitral stenosis. In StatPearls. StatPearls Publishing. <https://www.ncbi.nlm.nih.gov/books/NBK430742/>
 16. **Chichareon P, Nilmoje T, Suwanugorn S et al. (2022):** Procedural success and outcomes after percutaneous balloon mitral valvuloplasty in rheumatic mitral stenosis with moderate mitral regurgitation: a retrospective cohort study. *Cardiovascular Diagnosis and Therapy*, 12 (5): 552-562.
 17. **Otto C, Nishimura R, Bonow R et al. (2021):** 2020 ACC/AHA guideline for the management of patients with valvular heart disease: executive summary: a report of the American College of Cardiology/American Heart Association Joint Committee on Clinical Practice Guidelines. *Journal of the American College of Cardiology*, 77 (4): 450-500.
 18. **Dayan V, Garcia-Villarreal O, Escobar A et al. (2021):** The Latin American Association of Cardiac and Endovascular Surgery statement regarding the recently released American Heart Association/American College of Cardiology Guideline for the Management of Patients With Valvular Heart Disease 2020. *The Journal of Thoracic and Cardiovascular Surgery*, 162 (2): 584-586.
 19. **Bavry A, Arnaoutakis G (2021):** Perspective to 2020 American College of Cardiology/American Heart Association (ACC/AHA) guideline for the management of patients with valvular heart disease. *Circulation*, 143 (5): 407-409.
 20. **Ponikowski P, Voors A, Anker S et al. (2016):** 2016 ESC Guidelines for the diagnosis and treatment of acute and chronic heart failure. *Polish Heart Journal*, 74 (10): 1037-1147.
 21. **Tian B, Wu F, Han J et al. (2022):** Short-Term Results on Leaflet Mobility in Patients Undergoing Rheumatic Mitral Valve Repair With an Efficient 4-Step Commissuroplasty Technique. *Texas Heart Institute Journal*, 49 (6): e217801. doi: 10.14503/THIJ-21-7801.
 22. **Otto C, Nishimura R, Bonow R et al. (2022):** 2020 ACC/AHA Guideline for the Management of Patients With Valvular Heart Disease: Executive Summary: A Report of the American College of Cardiology/American Heart Association Joint Committee on Clinical Practice Guidelines. *Circulation*, 143 (5): 35-71.
 23. **Raj N (2019):** Regional anesthesia for sternotomy and bypass—Beyond the epidural. *Pediatric Anesthesia*, 29 (5): 519-529.
 24. **Puerto D, Rubin J (2022):** Surgical Approach to the Thoracic Cavity. *Small Animal Surgical Emergencies*, 22: 459-465.
 25. **Ogawa H, Fukuda H (2019):** Median Sternotomy (Re-do and Closure): Kyobu geka. *The Japanese Journal of Thoracic Surgery*, 72 (10): 749-751.
 26. **Wells F, Coonar A (2018):** Median Sternotomy. In: *Thoracic Surgical Techniques*. Springer International Publishing, Pp: 43-44
 27. **Fiore, A, Grande, A. M, & Gatti, G. (2023):** Major Complications of Cardiac Surgery. In: *The High-risk Surgical Patient* Springer International Publishing, Pp: 537-550
 28. **Dunning J, Gao H, Chambers J et al. (2011):** Aortic valve surgery: marked increases in volume and significant decreases in mechanical valve use—an analysis of 41,227 patients over 5 years from the Society for Cardiothoracic Surgery in Great Britain and Ireland National database. *J Thorac Cardiovasc Surg.*, 142: 776–82.e3.
 29. **Paparella, D, Fattouch, K, Moscarelli, M, Santarpino, G, Nasso, G, Guida, P, Margari, V, Martinelli, L, Coppola, R, & Albertini, A. (2020):** Current trends in mitral valve surgery: a multicenter national comparison between full-sternotomy and minimally-invasive approach. *International Journal of Cardiology*, 306: 147-151.
 30. **Reshmi J, Gopan G, Varma P et al. (2022):** Transesophageal echocardiographic assessment of the repaired mitral valve: a proposed decision pathway. *Seminars in Cardiothoracic and Vascular Anesthesia*, 26 (1): 68-82.
 31. **Grinberg D, Cosset B, Pozzi M et al. (2023):** Minimally Invasive Mitral Valve Repair/Replacement. In *Essentials of Operative Cardiac Surgery*. Springer International Publishing, Pp: 133-143. <https://www.ncbi.nlm.nih.gov/books/NBK567730/>
 32. **Hartley P, Kyriazis P, Punjabi P (2023):** Surgery for Mitral Valve Disease: Degenerative Repair. In *Essentials of Operative Cardiac Surgery*. Springer International Publishing, Pp: 107-115. <https://link.springer.com/book/10.1007/978-3-031-14557-5>
 33. **Ryaan E, Fialka N, Nagendran J (2023):** Enhanced recovery after cardiac surgery: The next step towards optimized care. *International Journal of Cardiology*, 372: 48-49.
 34. **Eqbal A, Gupta S, Basha A et al. (2022):** Minimally invasive mitral valve surgery versus conventional sternotomy mitral valve surgery: a systematic review and meta-analysis of 119 studies. *Journal of Cardiac Surgery*, 37 (5): 1319-1327.