

Comparative Review of Outcomes between Enhanced View Totally Extraperitoneal Technique with Inherently Divided Douglas' Line and Totally Extraperitoneal Technique for Repairing Inguinal Hernia

Mohamed Elsayed Seifalyazal*, Mohamed Elnagar, Sameh Said Mohamed, Ahmed Elnabil-Mortada

Department of General Surgery, Faculty of Medicine, Ain Shams University, Egypt

*Corresponding author: Mohamed Elsayed Seifalyazal, Mobile: (+20) 01157327366,

E-mail: seifalyaz1976@gmail.com, seifalyaz1976@med.asu.edu.eg

ABSTRACT

Background: The inguinal hernia can be repaired using a variety of laparoscopic methods. The most popular procedures are transabdominal preperitoneal (TAPP) and totally extraperitoneal (TEP). TEP technique is regarded closet to ideal. However, it has limitations that inspired the evolution of e-TEP. This small e stands for enhanced or extended view. Although the division of Douglas' line is not inherent to e-TEP technique, it offers a wider working place for secondary ports. **Objective:** To compare extended view totally extraperitoneal repair with inherently divided Douglas' line to totally extraperitoneal repair of inguinal hernia concerning operative time, ease of the procedure and postoperative complications. **Patients and Methods:** This prospective cohort study enrolled 55 patients diagnosed with inguinal hernia underwent laparoscopic repair between January 2019 and November 2021. Thirty-one patients (56.4%) underwent e-TEP technique with inherently divided Douglas' line (group I) and twenty-four patients (43.6%) underwent TEP technique (group II). **Results:** No significant difference was found between the two groups regarding age, sex and body mass index. Overall complication rate was higher in TEP group than in e-TEP group. Mean operative time, hospital stay, and pain score were less in e-TEP technique with inherently divided Douglas' line. The number of used tacks, and early return to work were significantly different for favor of e-TEP group.

Conclusion: Enhanced view TEP technique with inherently divided Douglas' line is superior to TEP technique for repairing inguinal hernia in providing a better visual angle and ergonomics with lower complication rates and shorter operative time

Keywords: Hernia, Douglas' line, TEP, e-TEP.

INTRODUCTION

Since the first published laparoscopic hernia surgery by Dr. Ralph Ger in 1982, many endolaparoscopic techniques to repair inguinal hernia have gained more advances in recent years ⁽¹⁾, as transabdominal preperitoneal (TAPP), totally extraperitoneal (TEP), extended totally extraperitoneal (e-TEP), laparoscopic intraperitoneal onlay mesh (IPOM) and robotic transabdominal preperitoneal (r-TAPP). Numerous research has compared TAPP with TEP methods. There was no discernible difference between the two procedures in terms of perioperative complication rates, according to the German hernia registry ⁽²⁾. Contrarily, register-based studies conducted in Japan and Switzerland revealed that the TEP group experienced greater perioperative problems than the TAPP group ⁽³⁾.

TEP technique has many advantages over TAPP as no penetration of the abdominal cavity, low risk of visceral or vascular injury and minimal risk of trocar site hernia. However, it has challenges such as field restriction caused by pneumoperitoneum due to peritoneal tears. In addition to bleeding, it is the conversion factor that leads to e-TEP growth ⁽⁴⁾.

Enhanced or extended view TEP concept was first developed in 2009 at Clinica Bautista, Colombia by Dales for inguinal hernia repair ⁽⁵⁾. It is based on the anatomical tenet that practically every point along the front abdominal wall can access the extra-peritoneal area ⁽⁶⁾. Later, Belyansky *et al.* ⁽⁷⁾ employed this method in laparoscopic ventral hernia surgery.

e-TEP technique has outstanding features such as: fast and easy creation of large extraperitoneal space, flexible port placement, more tolerance to pneumoperitoneum and better ergonomics ⁽⁶⁾. Although the division of Douglas' line is not inherent to e-TEP technique, it allows wider access to both Retzius and Bogros spaces and provides more comfortable dissection of the critical view of myopectineal orifice ⁽⁵⁾. e-TEP technique has its specific indications as short umbilicus-pubis distance, previous pelvic surgery, complicated hernia cases (sliding or large inguinoscrotal one), obese patient or post bariatric surgery. Finally, mastering e-TEP technique will open the door to encompass the repair of more complex cases of inguinal, incisional, ventral and lumbar hernias ⁽⁸⁾.

The aim of the study was to compare extended view totally extraperitoneal repair with inherently divided Douglas' line to totally extraperitoneal repair of inguinal hernia concerning operative time, ease of the procedure and postoperative complications.

PATIENTS AND METHODS

Population

We conducted a prospective cohort study. Fifty-five eligible patients aged between 18 and 66 years diagnosed with unilateral non-complicated inguinal hernia between January 2019 and November 2021 at Al-Jedaani Hospitals, KSA were included and divided between two groups. We excluded any patients who were unfit for general anesthesia, diagnosed with

bilateral or incarcerated hernia, and who had hernia recurrence after TEP/e-TEP previous repair.

Intervention & Surgical Technique

Port placement (Figure 1, 2)

TEP: one 10-mm optical port: 1 cm infra-umbilical in the midline and two 5mm secondary ports; the first one was placed 7.5 cm lateral to and on the same line of the umbilicus. The second one was placed midway between the umbilicus and symphysis pubis.

e-TEP: one 10-mm optical port: 3 cm above and lateral to the umbilicus, just medial to semilunar line and two 5mm secondary ports; the first one was placed at the umbilicus and the second one was placed 7.5 cm lateral to and on the same line of the umbilicus. Syringe needle was used as a guide (Global Positioning System or GPS) before inserting secondary ports to avoid their placement in the intra-peritoneal position or inferior epigastric vessels injury.

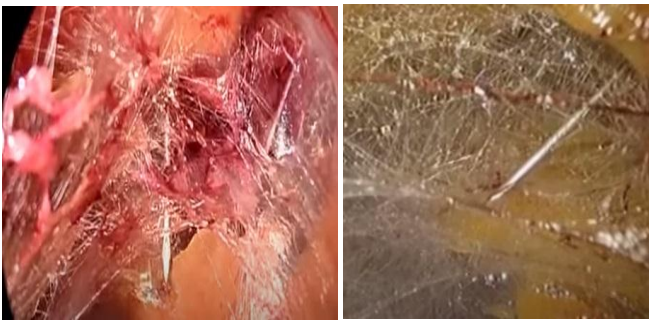

Figure (1): GPS needle.

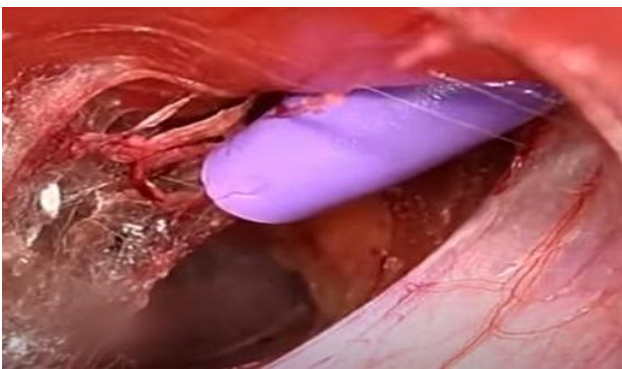


Figure (2): Secondary port inserted.

Space creation (figure 3)

The initial 10-mm incision was carried down sharply to the fascia, the anterior rectus sheath was incised transversely with a no. 11 blade to expose the rectus abdominis muscle. Avoiding the linea alba to avoid inadvertent entry into the peritoneum, the rectus muscle fibers were retracted laterally in TEP, and split along the direction of its fibers in e-TEP to expose the posterior rectus sheath. Then the surgeon's index finger was inserted into the preperitoneal space and is swept from side to side to open the space which was lifted by the retractor to allow 10-mm port insertion without the trocar. We used 30° scope and Co2 insufflation to create the working space. We did not use Balloon system for space creation, despite saving

time and decreasing bleeding by tamponade due to commercial issues.

Dissection & mesh placement (figure4-6)

Myopectineal orifice was checked for all potential hernias. Energy devices were used for dissection. After hernia reduction and parietalization, a prolene mesh was inserted to reinforce the whole myopectineal orifice.

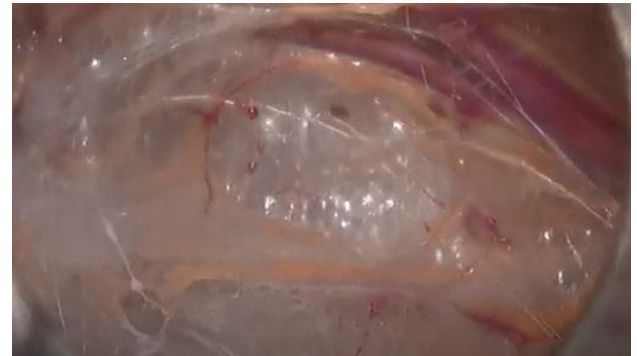

Figure (3): Space creation.

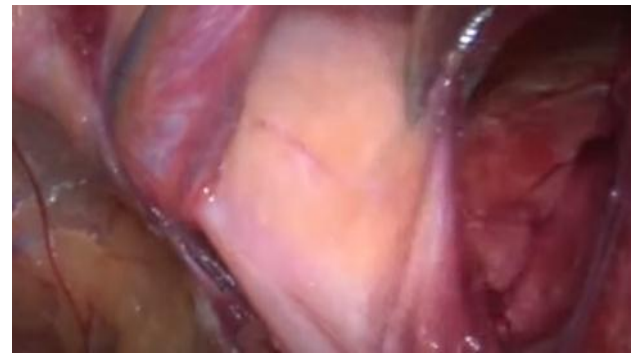

Figure (4): Sac lateral to epigastric vessels.

Division of the arcuate line "Douglas' line (figure 7)

A pair of scissors was introduced through the lowest trocar port to cut Douglas' line just at the level of the camera. Additionally, the Douglas' line can be properly dissected away from the underlying peritoneum with the use of a 5-mm laparoscope inserted via the lowest trocar while performing this division under vision. Because the two layers frequently join at the midline, this separation was simple to accomplish laterally. To prevent accidentally injuring the peritoneum and the gap collapsing, keep splitting Douglas' line up towards the roof. The surgical field acquired using this method is indubitably larger than that achieved using the TEP technique

Technical tips to decrease perioperative complications

1. To avoid recurrence: sufficient mesh size was used according to the defect size (smallest mesh size was 15×13 cm), adequate mesh marsupial was created (Figures 5 & 6).
2. Inferomedial aspect of the mesh was trimmed to avoid the less common postoperative complication of mesh penetration into the bladder.

3. To avoid postoperative chronic pain: triangle of pain was kept covered with fascia during dissection to avoid direct contact between the mesh and the nerves. Also, fewer issues of mesh fixation were used or sometimes we did not use any.
4. To alleviate postoperative seroma formation: external compression by pressure dressing was applied.
5. To avoid intraoperative bleeding: inferior epigastric vessels were kept on the roof during dissection to avoid injury and to maintain a proper space.

Patients were reviewed on the first and the seventh postoperative day. Patient's mean Visual Analogue Scale (VAS) (0=no pain to 10=most intense pain) was recorded postoperatively after 12 and 48 hours respectively. All patients were advised to contact the hospital if there were any of scrotal swelling, abdominal swelling, extensive skin discoloration, abdominal pain refractory to analgesia to rule out any of the potential postoperative complications and a follow-up ultrasonography/CT was done if indicated. All patients were followed-up for 6 months to detect early recurrence

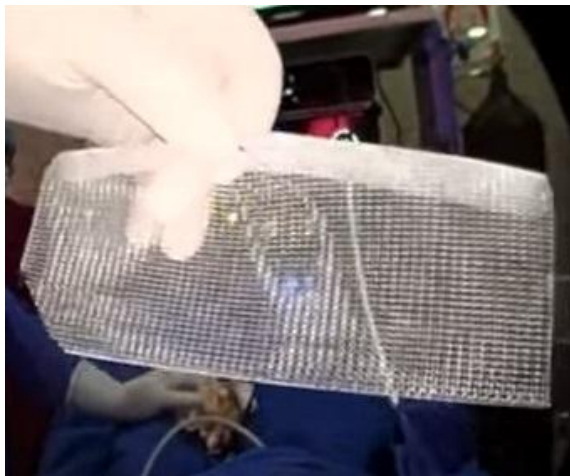


Figure (5): Trimmed mesh

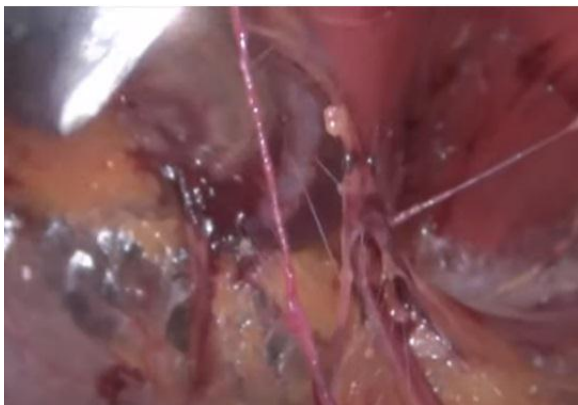

Figure (6): Epigastric vessels at the roof

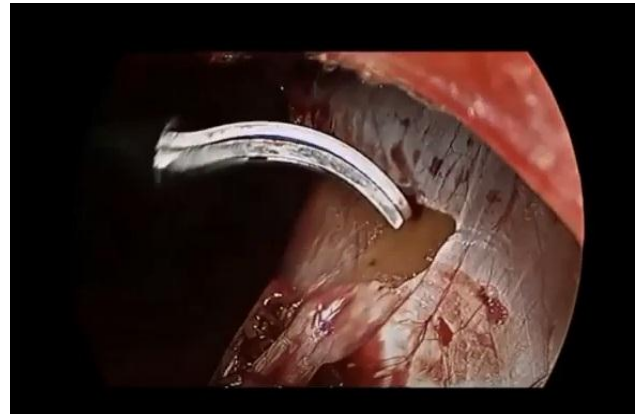
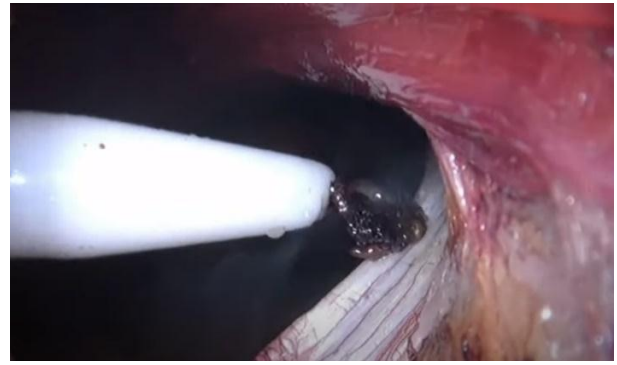


Figure (7): Division of the arcuate line "Douglas' line"

Comparators

Two groups of patients; group I who underwent e-TEP technique with inherently divided Douglas' line and group II who underwent TEP technique.

Outcomes

Demographics data, hernia characteristics, perioperative outcome, intraoperative complications, and postoperative complications were collected and statistically analyzed.

Ethical consent: The Ethical Institutional Review Board approved the study after explaining our research objectives. Informed consents were obtained from all study participants. This study was conducted in compliance with the code of ethics of the world medical association (Declaration of Helsinki) for human subjects.

Statistical analysis

We conducted a prospective cohort study. Statistical analyses of the data were done using IBM SPSS version 22.0. Mean \pm standard deviation was used to express results of continuous variables, whereas numbers (percentage) showed results for categorical variables. To compare data, Chi-square and two- sample t-tests were used. A p value ≤ 0.05 was considered significant.

RESULTS

A total of 55 patients were enrolled with thirty-one patients (56.4%) underwent e-TEP technique with divided Douglas' line (group I) and 24 (43.6%) underwent TEP technique (group II).

Age, gender, BMI showed statistically non-significant correlation as shown in table 1.

Patients’ Demographics

In our study, the mean age of group 1 was less than group II. There was male dominance in both groups. Mean body mass index (BMI) in group 1 and group II was 28.6±4.2 kg/m² and 27.5±3.2 kg/m², respectively.

Hernia characteristics

In this study, right sided hernia was more common in group I. Indirect hernia was more prevalent than direct hernia in both groups as shown in table 2.

Table (1): Patients’ characteristics

Parameters	e TEP with divided Douglas’ line group 1(n=31)	TEP group II (n=24)	p-value
Mean age (years)	41.5±12.5	42.5±11.3	0.771
Gender			0.958
Male	26 (83.9%)	20 (83.3%)	
Female	5 (16.1%)	4 (16.7%)	
Mean BMI (kg/m ²)	28.6±4.2 kg/m ²	27.5±3.2 kg/m ²	0.833
Diabetes	7 (22.6%)	6 (25%)	0.838
Hypertension	6 (19.4%)	4 (16.7%)	0.802

e-TEP: Extended totally extraperitoneal repair, TEP: Totally extraperitoneal repair. BMI: Body mass index.

Table (2): Hernia characteristics

Parameters	e TEP with divided Douglas’ line group I (n=31)	TEP group II (n=24)	p value
Side			
Right	22 (71%)	12 (50%)	0.117
Left	9 (29%)	12 (50%)	
Type			
Indirect	23 (74.2 %)	18 (75%)	0.947
Direct	8 (25.8%)	6 (25%)	

e-TEP: Extended totally extraperitoneal repair, TEP: Totally extraperitoneal repair.

Perioperative outcomes

In our study, the mean operative time and the mean Hospital stay after surgery were shorter in group 1. The mean number of used tacks was less in group 1 as compared to group II and proved to be statistically significant. Mean duration to return back to work after surgery was longer in group 1 than in group II with statistically significant P value. Mean VAS score at 12 hours after surgery was nearly the same in both groups, but at 48 hours after surgery, it was less in group I. Mean operative time, mean hospital stay after surgery and mean VAS score were less in group, I as shown in Table 3

Table (3): Peri-operative parameters

Parameters	e TEP with divided Douglas’ line group I (n=31)	TEP group II (n=24)	P-value
Mean operative time (min)	114.5±18.5	123.3±16.9	0.077
Mean Hospital stay after surgery (days)	1.8±0.44	2.1±0.51	0.282
Mean number of used tacks	1.2±0.3	2.7±0.66	0.000
Mean duration to return back to work after surgery (days)	8.8±1.2	9.5±1.5	0.048
Mean VAS Score			
12 hours after surgery	5.25±1.2	5.33±1.04	0.804
48 hours after surgery	2.1±0.7	2.2±0.8.	0.614

Intraoperative complications

In this study, intraoperative complications as peritoneal tears, conversion to TAPP or open procedures and intraoperative bleeding were more in group II as shown in Table 4

Table (4): Intraoperative complications

Parameters	e TEP with divided Douglas' line group I (n=31)	TEP group II (n=24)	p value
Peritoneal tears	3 patients (9.7%)	5 patients (20.8%)	0.253
Conversion to TAPP/open	2 patients (6.5%)	3 patients (12.5%)	0.448
Bleeding	3 patients (9.7%)	5 patients (20.8%)	0.253

Postoperative complications

In this study, postoperative complications as seroma formation were more in group II, while recurrence was only detected in group II. No chronic pain was reported in both groups as shown in Table 5

Table (5): Postoperative complications

Parameters	e TEP with divided Douglas' line group I (n=31)	TEP group II (n=24)	p value
Seroma	4 patients (12.9%)	6 patients (25%)	0.257
Recurrence	0%	1 patient (4.2%)	0.260
Chronic pain	0%	0%	1

DISCUSSION

In this study, the mean age was 41.5 ± 12.5 and 42.5 ± 11.3 years in e-TEP and TEP groups respectively, which was nearly the same as **Yildiz's** ⁽⁹⁾ study. Male sex was dominant in both groups in contrast to **Baig and Priya** ⁽¹⁰⁾ study on ventral hernia repair as they reported female dominance. In the present study, Age, gender, BMI, diabetes and hypertension showed no significant statistical difference that is in agreement with **Köckerling et al.** ⁽¹¹⁾ and **Penchev et al.** ⁽¹²⁾.

In our study, the mean operative time of e-TEP group was less than in TEP group. The same finding is reported by **Singh et al.** ⁽¹³⁾ as his mean operative time of TEP group was 40 minutes longer than e-TEP group. Also, **Korkowski** ⁽¹⁴⁾ showed less operative time for e-TEP repair (45 minutes). Our finding is in contrast to **Kumar et al.** ⁽¹⁵⁾ who reported significantly higher operative time for e-TEP repair. The variation in the mean duration is attributed to many factors like the different surgeons' skills and learning curves and the plenty of methods used for access and space creation.

In the current study, the mean Hospital stay after surgery was shorter in e-TEP group than in TEP group with no significant statistical difference. This is in agreement with **Rekhi et al.** ⁽¹⁶⁾ who reported no statistical difference between groups. Also, **Joshi and Dekhaiya** ⁽¹⁷⁾ reported shorter stay in e-TEP group.

In the present study, the mean duration to return back to work after surgery was shorter in e-TEP group than in TEP group with a significant statistical difference. This agrees with **Singh et al.** ⁽¹³⁾ as their duration to return back to work was longer in TEP group than in e-TEP group. But our finding contrasts

with **Rekhi et al.** ⁽¹⁶⁾ who reported no statistical difference between TEP and e-TEP.

In our study, the mean number of used tacks in e-TEP group was less than in TEP group with a significant statistical difference. The same finding was reported by **Singh et al.** ⁽¹³⁾.

In the current study, the mean VAS at 48 hours after surgery was less in e-TEP group than in TEP group. **Penchev et al.** ⁽¹²⁾ reported a lower pain score in e-TEP group from the day of surgery till the 7th post-operative day. Also, **Rekhi et al.** ⁽¹⁶⁾ and **Hallen et al.** ⁽⁴⁾ reported a higher pain score in TEP group.

Any surgical technique's value mostly depends on the overall volume and severity of complications. Perioperative complications were greater in the TEP group in a Swiss registry research ⁽¹⁸⁾. Our results are consistent with the Swiss study.

The most prevalent side effect following laparoscopic hernia surgery is seroma development. Large and scrotal hernias considerably enhance the incidence and amount of seroma ⁽¹⁹⁾. Postoperative seroma usually resolves spontaneously. Intervention is only needed for symptomatic seroma as strongly suggested by hernia communities ⁽²⁰⁾. The seroma rate after inguinal hernia repair was reported to be 0.5% to 12.2% ⁽²¹⁾. In our study, the seroma rate was 12.9% for e-TEP and 25% for TEP groups. Conservative measures were successful except for only one case of e-TEP and 3 cases of TEP as aspiration was needed. In a single-center study, seroma occurred in 6 patients out of 76 but only one case needed aspiration ⁽⁹⁾. **Lau et al.** ⁽²²⁾ reported 5.7% seroma rate in non-scrotal hernias and 22.9% in scrotal hernias following TEP repair. In addition, **Misra et al.** ⁽²³⁾ found that 70% of severe scrotal hernias that had TEP surgery experienced

seroma. In a similar vein, **Cihan et al.** ⁽²⁴⁾ found that employing ultrasonography instead of manual inspection showed a seroma rate of 66.7% in big hernias following TEP treatment.

The recurrence rate after laparoscopic hernia repair is 10% to 15%. The major causes are lack of surgical expertise and inadequate myopectineal orifice or hernia sac dissection ⁽²¹⁾. In our study, Recurrence was detected only in 1 patient of TEP group. **Yildiz** ⁽⁹⁾ reported 2 recurrent cases after TEP repair; one case was due to mesh contraction and was treated by open surgery. **Hallen et al.** ⁽⁴⁾ reported 3 recurrences in TEP group.

Chronic postoperative pain is described as discomfort that persists for longer than six months following surgery ⁽⁹⁾. In the current study, no chronic pain was reported in both groups. Our result is harmonious to **Li et al.** ⁽²⁰⁾ and **Meyer et al.** ⁽²⁵⁾ results as none complained of chronic pain in their studies. Routine mesh fixing is not advised since it may cause discomfort without reducing recurrence ⁽²⁶⁾.

To prevent postoperative infection, mesh displacement, and recurrence, intraoperative bleeding should be under control. Only symptomatic hematomas should be recognized as a postoperative complication, according to the Hernia Surge Group ⁽²¹⁾. In the present study, intraoperative bleeding due to inferior epigastric vessels injury was detected in 3 patients of e-TEP group and 5 patients of TEP group and it was successfully controlled by applying clips or using Ligasure. Two patients out of 76 had hematoma in TEP group ⁽⁹⁾.

In our study, Intraoperative peritoneal tears were reported in 9.7% of e-TEP group and in 20.8% of TEP group. First, we decreased the abdominal pressure, lowered the patient's head and inserted a Veress needle into Palmer's point if needed to maintain the space. Suturing or endoloop was used for peritoneal closure in some cases. Among the 3 e-TEP patients with peritoneal tears, conversion to TAPP procedure (hybrid method) was done in two patients. On the other hand, regarding the 5 TEP patients with peritoneal tears; hybrid TAPP was applied to two patients and one patient was converted to open surgery. So our conversion rate was 6.5% in e-TEP group and 12.5% in TEP group. Peritoneal tears were observed in 7.9% in TEP group ⁽⁹⁾. In comparison with three studies, the conversion rate of TEP to open or TAPP was 5.3% ⁽²⁷⁾. Peritoneal tears were detected in 47% of patients using the TEP method in 123 cases; 13% of these tears were substantial, therefore conversion was preferable ⁽⁷⁾.

We found that e-TEP technique with divided Douglas' line is superior to TEP technique in providing a better visual angle along with lower complication rates, which agrees with **Reza et al.** ⁽⁸⁾ who reported that e-TEP procedure has minimum complications and easier learning curve than TEP.

CONCLUSION

Enhanced view TEP technique with inherently divided Douglas' line is superior to TEP technique for repairing inguinal hernia in providing a better visual angle and ergonomics with lower complication rates and shorter operative time.

Disclosures: There are no conflicts of interest or financial ties to disclose

REFERENCES

1. **Ger R (1982):** The management of certain abdominal herniae by intra-abdominal closure of the neck of the sac. *Annals of the Royal College of Surgeons of England*, 64 (5): 342-44.
2. **Bittner R, Montgomery M, Arregui E et al. (2015):** Update of guidelines on laparoscopic (TAPP) and endoscopic (TEP) treatment of inguinal hernia (International Endohernia Society). *Surgical Endoscopy*, 29 (2): 289-321.
3. **Shiroshita H, Inomata M, Bandoh T et al. (2019):** Endoscopic surgery in Japan: the 13th national survey (2014- 2015) by the Japan Society for Endoscopic Surgery. *Asian Journal of Endoscopic Surgery*, 12 (1): 7-18.
4. **Hallén M, Bergenfelz A, Westerdahl J (2008):** Laparoscopic extraperitoneal inguinal hernia repair versus open mesh repair: long-term follow-up of a randomized controlled trial. *Surgery*, 143 (3): 313-7.
5. **Daes J (2012):** The enhanced view–totally extraperitoneal technique for repair of inguinal hernia. *Surgical Endoscopy*, 26 (4): 1187-9.
6. **Ferzli G, Iskandar M (2019):** Laparoscopic totally extra-peritoneal (TEP) inguinal hernia repair. *Ann Laparosc Endosc Surg.*, 4 (0): 35-5.
7. **Belyansky I, Daes J, Radu V et al. et al. (2018):** A novel approach using the enhanced-view totally extraperitoneal (eTEP) technique for laparoscopic retromuscular hernia repair. *Surg Endosc.*, 32: 1525-1532.
8. **Reza S, Hoque M, Akther S et al. (2019):** Early Outcomes of “Extended View Total Extraperitoneal (eTEP)” Procedure for Inguinal Hernia. *Journal of Shaheed Suhrawardy Medical College*, 11 (2): 96-100.
9. **Yildiz A (2022):** Laparoscopic transabdominal preperitoneal and totally extraperitoneal techniques in inguinal hernia surgery: comparison of intraoperative and postoperative early complications of two techniques. *Journal of Minimally Invasive Surgery*, 25 (1): 18-23.
10. **Baig S, Priya P (2019):** Extended totally extraperitoneal repair (eTEP) for ventral hernias: Short-term results from a single centre. *Journal of Minimal Access Surgery*, 15 (3): 198-203.
11. **Köckerling F, Bittner R, Kuthe A et al. (2017):** TEP or TAPP for recurrent inguinal hernia repair-register-based comparison of the outcome. *Surgical Endoscopy*, 31 (10): 3872-82.
12. **Penchev D, Kotashev G, Mutafchiyski V (2019):** Endoscopic enhanced-view totally extraperitoneal

- retromuscular approach for ventral hernia repair. *Surgical Endoscopy*, 33 (11): 3749-56.
13. **Singh S, Kala S, Jauhari R et al. (2022):** A prospective randomized study of eTEP and TEP repair for inguinal hernia in terms of ease of operability, complication and recurrences. *Asian Journal of Medical Sciences*, 13 (3): 87-94.
 14. **Korkowski J (2018):** Experiencia inicial en cirugía endoscópica de hernia inguinal con técnica total extraperitoneal de vista extendida eTEP. *Revista Mexicana de Cirugía Endoscópica*, 19 (2): 59-62.
 15. **Kumar N, Palanisamy N, Parthasarathi et al. (2021):** A comparative prospective study of short-term outcomes of extended view totally extraperitoneal (e-TEP) repair versus laparoscopic intraperitoneal on lay mesh (IPOM) plus repair for ventral hernia. *Surgical Endoscopy*, 35 (9): 5072-5077.
 16. **Rekhi H, Singh G, Sharma E et al. (2020):** Assessment of perioperative outcome in primary unilateral inguinal hernia: A comparative study. *Int J Surg Sci.*, 4 (2): 229-32.
 17. **Joshi J, Dekhaiya F (2020):** A Comparative study between E-TEP versus IPOM hernia repair. *IOSR J Dent Med Sci.*, 19 (3): 19-21.
 18. **Gass M, Banz V, Rosella L et al. (2012):** TAPP or TEP? Population-based analysis of prospective data on 4,552 patients undergoing endoscopic inguinal hernia repair. *World J Surg.*, 36: 2782-2786.
 19. **Köckerling F, Bittner R, Adolf D et al. (2018):** Seroma following transabdominal preperitoneal patch plasty (TAPP): incidence, risk factors, and preventive measures. *Surgical Endoscopy*, 32 (5): 2222-31.
 20. **Li J, Ji Z, Shao X (2018):** Prevention of seroma formation after laparoscopic inguinoscrotal indirect hernia repair by a new surgical technique: a preliminary report. *International Journal of Abdominal Wall and Hernia Surgery*, 1 (2): 55-9.
 21. **Hernia Surge Group (2018):** International guidelines for groin hernia management. *Hernia*, 22: 1-165. doi: 10.1007/s10029-017-1668-x.
 22. **Lau H, Lee F (2003):** Seroma following endoscopic extraperitoneal inguinal hernioplasty. *Surgical Endoscopy*, 17 (11): 1773-7.
 23. **Misra M, Bhowate P, Bansal V et al. (2009):** Massive scrotal hernias: problems and solutions. *Journal of Laparoendoscopic & Adv Surg Tech A.*, 19 (1): 19-22.
 24. **Cihan A, Ozdemir H, Uçan B et al. (2006):** Fate or fate. Seroma in laparoscopic inguinal hernia repair. *Surg Endosc.*, 20 (2): 325- 8.
 25. **Meyer A, Blanc P, Balique J et al. (2013):** Laparoscopic totally extraperitoneal inguinal hernia repair: twenty-seven serious complications after 4565 consecutive operations. *Revista do Colégio Brasileiro de Cirurgiões.*, 40 (1): 32-6.
 26. **Ferzli G, Edwards E, Khoury G (2007):** Chronic pain after inguinal herniorrhaphy. *J Am Coll Surg.*, 205: 333-41.
 27. **Goksoy B, Yilmaz G, Azamat I et al. (2021):** Laparoscopic inguinal hernia repair-TAPP versus TEP: results of 301 consecutive patients. *Surg Technol Int.*, 39: 191-195.