

Anatomical Variables as Predictive Factors of Intra-Operative Residual during Adenoidectomy

Mohamed Ahmed Alshawadfy Saleh, Nasser Najeeb Nasr, Monira Abdulrahman Salem Elkaseh, Ibrahim Mohamed Saber

Department of Otorhinolaryngology, Head and Neck surgery, Faculty of Medicine, Zagazig University

*Corresponding author: Monira Abdulrahman Salem Elkaseh, Mobile: (+20) 01012585954,

E-mail: 0925548894mk@gmail.com

ABSTRACT

Background: Children with adenoids that have grown too large often have difficulty breathing or get infections among upper respiratory tract because their airways are blocked. In most cases, adenoidectomy can reduce clinical symptoms and boost quality of life.

Objectives: This study aimed to determine if there are any factors that can influence the usual procedure of adenoidectomy and its ability to remove all adenoid tissue.

Subjects and Methods: Intra-operative variables for assessing demographic and anatomical characteristics, such as age, sex, weight, height, BMI, and soft palate length were observed in a retrospective analysis to determine their impact on adenoidectomy success. Every child had a standard trans-oral curettage adenoidectomy completed under endoscopic control, and if there were any adenoid remnants, a revision adenoidectomy was done at the same time. The total number of patients included was 208.

Results: In 43.7% of patients (91/208), complete adenoidectomy was challenging since traditional surgery could not access the most important parts of the nasopharynx. The average soft palate length in this group was 2.8 centimeters, 5 millimeters longer than the sample as a whole, and 1 cm larger than the typical patient who undergoes only standard surgical procedure alone ($p < 0.001$). **Conclusion:** Intraoperatively, the soft palate length can be used as a factor for choosing which patients would undergo endoscopic control following standard adenoidectomy.

Keywords: Intra-operative residual, Adenoidectomy, TECCA, Revision adenoidectomy.

INTRODUCTION

Hypertrophied adenoids are a common cause of pediatric upper airway obstruction. Along with obstructive sleep disorder, snoring, persistent rhinorrhea, as well as hyponasal speech, nasal blockage is one of the main symptoms they come with. Hyperplastic adenoids, on the other hand, can be colonized by bacteria and may serve as a source of chronic illness^(1,2). Obstruction of the upper airway, particularly during sleep, can cause distress to the respiratory system and a host of related problems. Adenoid hypertrophy is the leading cause of childhood upper airway obstruction, and it is quite prevalent. Mouth breathing, snoring, sleep apnea, and a hoarse or weak voice are just some of the symptoms that may result from nasal passage obstruction caused by enlarged adenoids. Adenoid hypertrophy can also lead to facial asymmetry, chronic middle ear infections, and sinus infections⁽³⁾.

When performed alone, adenoidectomy can alleviate nasal congestion and the symptoms of frequent colds and other respiratory illnesses⁽⁴⁾. However, after surgery, some patients still experience considerable nasal problems. Nineteen to twenty-six percent of individuals suffer persistent symptoms, like stuffy noses and frequent infections of the upper respiratory tract⁽⁵⁾.

It is widely held among doctors and the general public that some individuals may continue to experience symptoms related to their adenoids even after they have been surgically removed. Sometimes, this viewpoint is what fuels the debate about this procedure. Some authors claim that adenoids rarely re-grow to the point where they induce symptoms of nasal obstruction, however there is a lack of data to support this. Others argue that anomalies

other than a deviated septum or overgrown turbinates could be to blame for post-operative discomfort⁽⁵⁾.

Otolaryngologists perform adenoidectomy and tonsillectomy more frequently than any other surgical operation in children. Several methods have been offered to lessen the risk of bleeding and make it simpler and safer to remove adenoid tissue. The co-ablator, adenoid curette, bipolar cautery, and power-assisted microdebrider are all variable options for this procedure⁽⁶⁾. The nasopharyngeal airway is clearly visible in the lateral view of the skull, in stark contrast to the shadows cast by the soft tissues and the skull base. As a result, the lateral skull view is frequently employed in the detection of adenoid hypertrophy⁽⁷⁾.

When the adenoid or tonsil is removed, the obstructive symptoms typically improve. With adenotonsillectomy, there is an estimated 80% success rate in curing obstructive sleep apnea⁽⁵⁾. Adenoid residual following surgeries is a potential cause of recurrent nasopharyngeal blockage symptoms. Residual rates might be anywhere from 1.3% to 26.4%. Recent focus has been virtually entirely on intra-operative patient-independent factors⁽⁸⁾.

This study aimed to determine whether or not factors specific to each patient would affect how well the standard method of removing adenoid lymphoid tissue worked.

SUBJECTS AND METHODS

Subjects:

Children were included in retrospective observational research that included 208 participants (aged less than fifteen years) who underwent

adenoidectomy or adenotonsillectomy, were evaluated at the Unit of Upper Airway Endoscopy Surgery (Otorhinolaryngology Department, Zagazig University Hospitals).

Inclusion criteria: All children with adenoid hypertrophy of grades II, III, and IV, chronic adenoiditis with persistent secretory otitis media not responding to medical therapy, recurrent acute otitis media with adenoiditis and obstructive sleep apnea not responding to medical treatment and associated with tonsillectomy. Pre-operative radiological evaluation and grading of adenoid size, age, sex, weight, height, and laboratory investigation.

Exclusion criteria: Personal history of cleft lip and/or palate whether surgically corrected. Patient unfit for anesthesia and surgery excluded from the study.

Surgical technique and patient management

All subjects included in the study underwent adenoidectomy or adenotonsillectomy. Intubation of the patient's trachea was done under general anaesthesia before the procedure, and a Bowel-Davis mouth gag was used to expose the surgical area while the patient lay supine. We used a bendable surgical ruler to measure the soft palate, beginning at the point where the fibromuscular component of the soft palate attaches to the bone palate and ending at the point where the uvula insertion is present on the posterior palatal pillar (Figure 1).

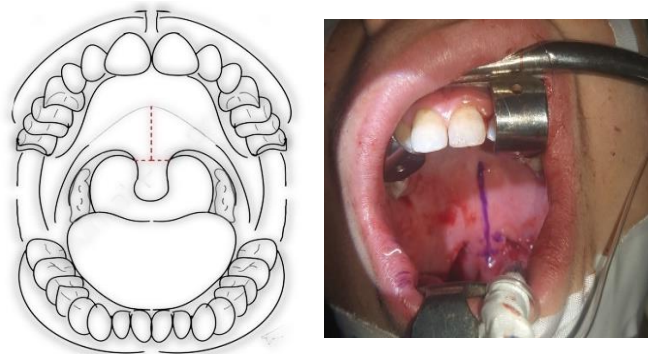


Figure (1): Measurement length of the soft palate.

All kids had a typical transoral adenoidectomy using a curette of varying diameters. The nasopharynx was not viewed during this surgical procedure. Endoscopic nasopharyngeal control at zero degree and 2.7 mm rigid nasal optic, and a 4 mm rigid nasal optic in older children, was performed at the conclusion of the normal surgical procedure. If all lymphoid tissue had been successfully excised during surgery, so the procedure had finished (**Group A**). Under endoscopic endonasal control, the remaining lymphoid tissue was removed using a curette or coblation in cases where adenoid tissue persisted (**Group B**). Curette and transnasal devices sometimes failed to reach lymphoid tissue in the nasopharynx, in these cases, the

adenoidectomy was completed transorally under endoscopic control (TECCA) with a curved microdebrider (Figure 2). To prevent injury to the oropharynx, the suction was turned off before the microdebrider is introduced and the soft palate was retracted using a rubber catheter. Then, the device was advanced through the mouth and nasopharynx and the remaining lymphoid tissue was removed while the endoscope monitors the procedure. Damage must be avoided at all costs. The torustubaris is a power-assisted instrument that uses continual suction to completely remove lymphoid tissues and to stop the bloodless field removal when it reaches the fascia covering the pharyngeal muscles. In a few cases, hemostasis was achieved by using hydrogen peroxide-soaked pledgets or suction diathermy, the mouth gag was removed from the mouth (**Group C**).

Standard adenoidectomy procedures were used, and the length of the soft palate was measured (**Group A**), curette was used for endoscopic revision (**Group B**) and TECCA (**Group C**). The BMI, age, sex, weight, height were calculated for each patient.

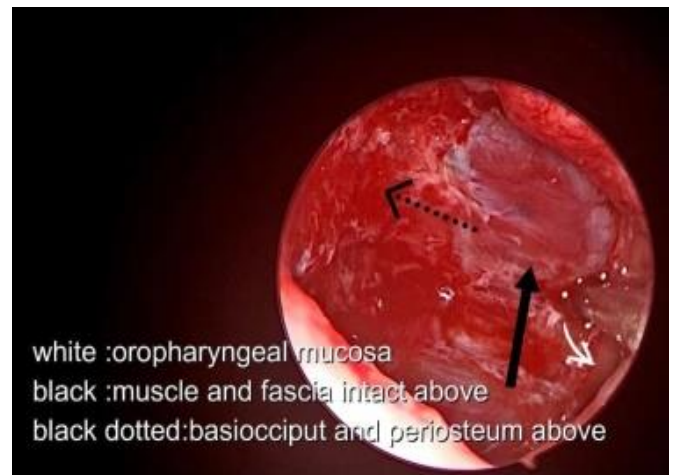
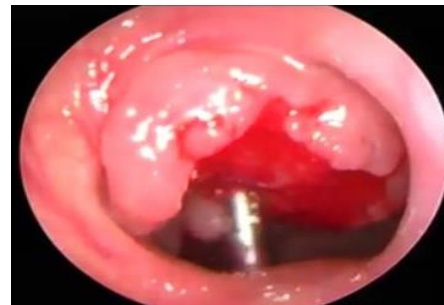
Figure (2): Transoral endoscopic controlled combined adenoidectomy (TECCA)

Ethical consent:

Research ethics council at Zagazig University approved the study (ZU-IRB#8055). All participants provided informed consent forms. Ethics guidelines for human experimentation were adhered to by the World Medical Association's Helsinki Declaration.

Statistical analysis:

In order to analyze the data acquired, Statistical Package of Social Sciences version 20 was used to execute it on

a computer (SPSS). In order to convey the findings, tables and graphs were employed. The quantitative data was presented in the form of the mean, median, standard deviation, and confidence intervals. The information was presented using qualitative statistics such as frequency and percentage. The student's t test (T) was used to assess the data while dealing with quantitative independent variables. Pearson Chi-Square and Chi-Square for Linear Trend (X²) were used to assess qualitatively independent data. The significance of P value of 0.05 or less was determined.

RESULTS

Ninety females (43.3% of the total) and one hundred and eighteen males (56.7%) were included in the 208 patients. The mean age was 8.7 ± 4.2 years. Group A: The majority, or 80%, of these patients (38.5%) had the traditional surgical procedure done. Group B: Endoscopic correction using a curette or coblation was performed on 37 patients (17.8%). Group C: while TECCA was used in 91 cases (43.7%) (Figure 3). Of the patients who had surgery, 196 had 1st time procedures, while 12 (5.1% of the total) had revision surgery because to adenoid hypertrophy that had persisted or returned after the 1st time procedure.

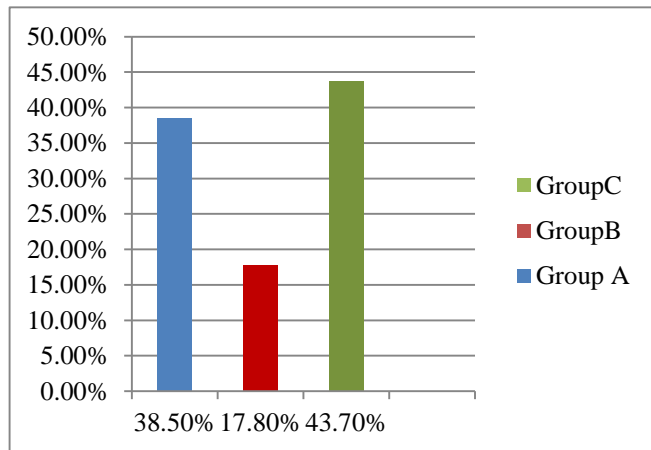


Figure (3): Bar chart for groups of adenoidectomy

Studied group average age was 8.7 ± 4.2 ranging from 3 to 15 years, weight was 37.6 ± 14.9, height was 123.4 ± 27.2, BMI was 25.2 ± 10.2 Kg/m² and 56.7% were males and 43.3% females (Table 1).

Table (1): Characteristics of the studied group

| Descriptive data | The studied group (n=228) | |
|------------------|---------------------------|------------------------|
| | Mean ± SD | Median (Range) |
| Age (years) | 8.7 ± 4.2 | 9 (3 -15) |
| Weight (Kg) | 37.6 ± 14.9 | 37.5 (13 -67) |
| Height (cm) | 123.4 ± 27.2 | 119 (72 -162) |
| BMI | 25.2 ± 10.2 | 23.6 (13.54 -66.77) |
| Gender N (%) | Male | 118 (56.7%) |
| | Female | 90 (43.3%) |

Study participants had an average soft palate length of 2.6 ± 0.4 centimeters. Calculated mean palate length across patient groups (Figure. 3). On average, the soft palate was 2.5 ± 0.3 cm in length in group A, which used the usual procedure.

Group B patients who underwent endoscopic revision with curette or coblation had a 2.8 ± 0.4 cm softer palate. Within the TECCA population (group C) length averaged 3.1 ± 0.4 centimeters. Significant statistical evidence linked palate length to surgical approach (p < 0.001).

The statistical association with demographic factors including age, height, and palate length was determined to be moderate. However, there was no link discovered between body mass index and soft palate length (Table 2).

Table (2): Comparing age, BMI and soft palate length in the studied groups

| Variables | Group A No=80 (38.5%) Mean ± SD (Range) | Group B No=37 (17.8%) Mean ± SD (Range) | Group C No=91 (43.7%) Mean ± SD (Range) | Test | P-value |
|--------------------------------|--|--|---|---------------------|-----------------|
| Age (years) | 5.5 ± 2.8 (3-12) | 10.8 ± 3.5 (4-15) | 10.2 ± 3.1 (5-13) | 62.5 | 0.001** |
| BMI (kg/m ²) | 25.2 ± 7.7 (13.5-40.15) | 25.8 ± 13.01 (16.3-66.7) | 23.3 ± 4.3 (17.3-28.8) | 0.7 | 0.4 |
| Length of the soft palate (cm) | 1.7 ± 0.3 (1.3-2.3) | 2.9 ± 0.35 (2.5-3.6) | 2.6 ± 0.69 (1.5-3.8) | 168.9 | 0.0001** |
| Sex | | | | | |
| Male | 40 (50.0%) | 51(56.0%) | 27 (72.9%) | χ ² =4.9 | 0.07 |
| Female | 40 (50.0%) | 40 (43.9%) | 10 (27.1%) | | |

**Highly statistically significant different.

Table (3) showed that there was highly statistically significant increase in age and soft palate length among patients with group B and C endoscopic repair than with group A, adenoidectomy. Otherwise, there was no statistically significant difference regarding sex and BMI. There was highly statistically significant higher length of soft palate among patients with adenoid residual than without. More than half of the studied group had adenoid residual (61.5%) as shown in figure (4).

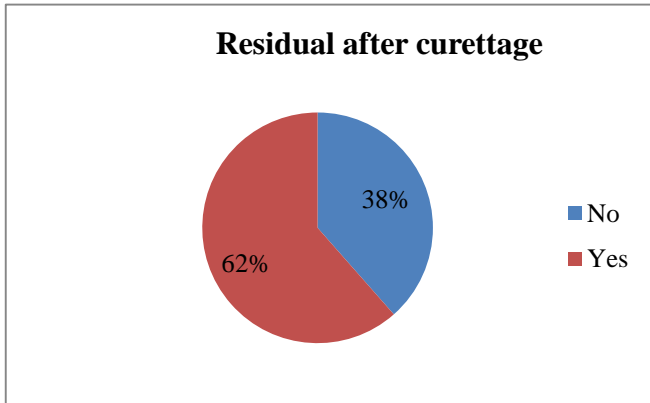


Figure (4): Pie chart for adenoid residual among the studied group.

Table (3): Comparison between patients with and without adenoid residual regarding, weight, age, height sex and length of soft palate

| Variables | Adenoid residual No= 128 (%) Mean ± SD Median (Range) | No residual No=80 (%) Mean ± SD Median (Range) | Test | P-value |
|-----------------------|--|---|--------------|----------|
| Age | 10.8 ± 3.1 11.5 (4-15) | 5.5 ± 2.8 4.5 (3-12) | 11.1 | 0.001** |
| Weight | 45 ± 11.3 48 (18-68) | 26 ± 6.8 28.5 (13-39) | 11.2 | 0.001** |
| Height | 136.8 ± 24.2 138.5 (94-169) | 101.9 ± 15.3 100 (72-136) | 11.5 | 0.001** |
| Sex | | | | |
| Male | 82 (64.0%) | 36 (45.0%) | $\chi^2=2.9$ | 0.06 |
| Female | 46 (36.0%) | 44 (55.0%) | | |
| Length of Soft Palate | | | 19.4 | 0.0001** |
| Mean ± SD | 2.8 ± 0.49 2.8 (1.5-3.8) | 1.7 ± 0.3 1.8 (1.3-2.3) | | |
| Median (Range) | | | | |

DISCUSSION

Otitis media, adenoid hypertrophy, and obstructive sleep apnea are all conditions that call for an adenoidectomy to be performed (OSA). Throughout the world, adenoidectomy is currently among the most common surgical procedures performed on children. Moreover, adenoidectomy can be done alone or in

conjunction with other procedures such as nose surgery, breathing tube insertion, and tonsillectomy (9).

Adenoidectomy typically improves clinical symptoms and quality of life, but in certain cases, considerable obstructive lymphatic tissue may remain following surgery, causing nasal obstructive problems to persist or return (10). Adenoid regrowth from residual is common due to the non-encapsulated nature of adenoid vegetation, making a complete adenoidectomy extremely unlikely (5). Adenoid tissue at the posterior choanae used to be confirmed for potential

completeness through blind digital palpation, but with the advent of laryngeal mirrors and telescopes in recent decades, adenoid surgery can now be performed with visualization, allowing for a more thorough removal of adenoid tissue (10).

Non-patient-specific intraoperative factors have been studied. In reality, several studies have examined the surgical efficacy of the different devices, with contradictory findings (8).

Continually large residual in many situations, residual adenoid tissue remains following a standard adenoidectomy, making transnasal endoscopic vision, in particular, essential for a thorough procedure. Deletion of lymphoid tissue is precise for prevention of bleeding and reduction of surgical consequences as well as reduction in the occurrence of subsequent recurrence. Individual and physical parameters including age, sex, weight, height, BMI, and the length of the soft palate can influence surgical efficacy (11). Our study was a retrospective observational analysis of these factors.

Our research showed that in 43.7% of TECCA-Group C cases, the most important parts of the nasopharynx are not reachable by normal instruments of traditional surgery, making it difficult to undertake complete excision of lymphoid tissue using this technique. Statistical testing revealed no significant correlation between gender or body mass index and adenoid residual, however soft palate length was found to have a significant impact. There was highly significant increase on age, weight and height among patients with adenoid residual than with without. 38.5% of cases (80 patients) in group A, where adenoid tissue was successfully removed using standard surgical methods, there was no need for any additional adenoid removal procedures. In this group, the average length of the soft palate was 1.7 centimeters. However, 17.8% of patients (37 cases of group B) required a second endoscopic procedure, either adenoid curette or coblation. The average length of the soft palate in these individuals was 2.6 centimeters, which was 0.9 centimeters longer than in the group that underwent conventional surgery alone (group A). Complete removal of the adenoid's lymphoid tissue is difficult in these patients due to the length of the soft palate, but is doable with endoscopic aid and the same surgical instruments used for conventional adenoidectomy. Overall, entire adenoid tissue excision was possible with transoral endoscopic controlled combined

adenoidectomy in 43.7% of patients (91 cases) despite endoscopic control (TECCA). The average length of the palate in this population was 2.9 centimeters, which was 1.2 centimeters longer than the average length of the palate in patients undergoing conventional surgery alone (Group A). There was a statistically significant difference here, supporting the idea that longer soft palates make it more difficult to eliminate all nasopharyngeal lymphatic tissue. The average soft palate length of individuals who had revision adenoidectomy was longer than the sample average by 5.1% points (12 patients), which is another significant finding. These findings showed that a longer soft palate is linked to a higher risk of surgical revision, and they may lend support to the theory that the persistence of residual adenoid tissue in these patients is not related to the approach or technique employed, but is instead primarily determined by anatomical characteristics of the oropharynx. There was no association found between palate length and either age or body mass index, according to the data. This suggests that the length of the soft palate is a significant predictor of whether lymphatic tissue leftovers will persist following standard adenoidectomy. The length of soft palate is easily measurable and is not affecting surgical times. In clinical practice, it can be useful parameter, helping the selection of the most useful technique of adenoidectomy. Despite the challenges in obtaining an extremely accurate measurement of the soft palate, particularly at the free margin of the soft palate, it remains a valid criterion with established predictive significance.

Our patients characteristics are similar to the findings of **Pagella et al.** (10) whose study include 612 patients, 353 male (57.68%), 259 female (42.32%). There were 432 patients with an average age of 6.39 years who underwent standard surgical procedures (group A). Sixty-seven patients (10.9%) had curette-assisted endoscopic revisions (Group B). While, TECCA was used in 113 of the instances (18.4%) (Group C). In that study's participants, the average length of the soft palate was 2.6 ± 0.4 cm (SD.4). While, the average length of the soft palate among groups of our study was 2.4 ± 0.67 cm.

CONCLUSION

In our study standard adenoidectomy with blind digital palpation was not effective for complete removal of adenoid tissues. Transnasal endoscopic visualization of the nasopharynx must be done in all patients, but the cost and surgical time will increase. So, intraoperatively, the soft palate length can be used as a factor for choosing which patient would undergo endoscopic control following standard adenoidectomy.

LIMITATIONS

- Since the study was retrospective, the 6-month follow-up period may not have been long enough to detect any remaining adenoids.

- Subjective symptom improvement was analyzed independently of other medical diagnosis.
- Finally, the impact of simultaneous tonsillectomy in some individuals, which could affect the shift in symptoms, was not evaluated.
- Some kids just won't help out.

Conflict of interest: The authors declared no conflict of interest.

Sources of funding: This research did not receive any specific grant from funding agencies in the public, commercial, or not-for-profit sectors.

Author contribution: Authors contributed equally in the study.

REFERENCES

1. **Fasunla A, Totyen E, Onakoya P et al. (2020):** Short-term effect of adenotonsillectomy on growth and nutritional anthropometric parameters of children with obstructive adenotonsillar enlargement. *Egyptian Pediatric Association Gazette*, 68 (1): 1-6.
 2. **Zeid N, El Fouly M, Azooz K et al. (2018):** Impact factor of using local steroid nasal spray in the prevention of recurrent nasal symptoms and adenoid regrowth after adenoidectomy. *Pan.*, 8: 14-18.
 3. **Kim M, An Y, Chung Y (2015):** Do adenoids regrow after adenoidectomy? *Sleep Medicine Research*, 6 (1): 24-27.
 4. **Taniguchi K, Baba S, Kanemaru A et al. (2021):** Outcomes of adenoidectomy with and without tonsillectomy in patients younger than 2 years with moderate to severe upper airway obstruction. *International Journal of Pediatric Otorhinolaryngology*, 149: 110841. doi: 10.1016/j.ijporl.2021.110841
 5. **Lesinskas E, Drigotas M (2009):** The incidence of adenoidal regrowth after adenoidectomy and its effect on persistent nasal symptoms. *European Archives of Otorhinolaryngology*, 266 (4): 469-473.
 6. **Modi A, Raval J, Aiyer R et al. (2020):** Comparative Study between Conventional Curettage Adenoidectomy Versus Endoscopic Microdebrider Assisted Adenoidectomy: Our Experience. *Indian Journal of Otolaryngology and Head & Neck Surgery*, 20: 1-6.
 7. **Cengiz K, Kumral T, Yildirim G (2013):** Diagnosis of pediatric nasopharynx carcinoma after recurrent adenoidectomy. *Case Rep Otolaryngol.*, 13: 653963. doi: 10.1155/2013/653963
 8. **Grindle C, Murray R, Chennupati S et al. (2011):** Incidence of revision adenoidectomy in children. *Laryngoscope*, 121: 2128-30.
 9. **Lee C, Chang W, Ko J et al. (2017):** Revision adenoidectomy in children: a population-based cohort study in Taiwan. *European Archives of Otorhinolaryngology*, 274 (10): 3627-3635.
 10. **Pagella F, Lizzio R, Pusateri A et al. (2021):** Adenoidectomy: Anatomical variables as predictive factors of intraoperative adenoid residues. *International Journal of Pediatric Otorhinolaryngology*, 140: 110493. doi: 10.1016/j.ijporl.2020.110493
- Ozkiris M, Karacavus S, Kapusuz Z et al. (2013):** Comparison of two different adenoidectomy techniques with special emphasize on postoperative nasal mucociliary clearance rates: coblation technique vs. cold curettage. *Int J Pediatr Otorhinolaryngol.*, 77: 389-393.