

Assessment of the Potential role of Hesperidin as an Antioxidant on the Carbon Tetrachloride -Induced Kidney Damage in Rats

¹Ali Abd Alsalam , ²Fathy M. Elshaer , ³Hamdi Abdou Mansour

¹Department of Pharmacology, Faculty of Medicine, Al-Azhar University, Assiut, Egypt,

²Zoology Department, Faculty of Science, Al-Azhar University, Cairo, Egypt

³Department of Pharmacology, Faculty of Medicine, Al-Azhar University, Cairo, Egypt,

Corresponding Author: Dr.Ali4@yahoo.com

ABSTRACT

Aim of the work-The present work aimed to investigate the ability of Hesperidine (HDN) as an antioxidant to retard development of renal toxicity induced by CCL4 in rat. Hesperidin (HDN), a citrus bioflavonoid, decreases the oxidative stress produced by carbon tetrachloride in rat kidney. Exposure to CCl4 induces acute and chronic renal injuries. The present study was designed to evaluate the protective effect of hesperidin, on rat kidney damaged by CCl4. **Material and methods-**Animals were divided into five groups pretreated with hesperidin (HDN) (100 and 200 mg/kg orally) for 10 days and then challenged with CCl4 (2 ml/kg/s.c.) of in olive oil subcutaneously. Rats were sacrificed by carotid bleeding under ether anesthesia. **Results:** The present results showed that the antioxidant properties of hesperidine might be the main factor responsible for its strong protective action on CCl4-induced nephrotoxicity. **Conclusion-** This study proved that hesperidin has a protective effect on the renal tissue of rat and the degree of improvement varies in intensity according the dose of Hesperidin

Key words: Hesperidin, carbon tetrachloride, kidney, albino rat

INTRODUCTION

Humans are constantly exposed to hazardous pollutants in the environment for example, in the air, water, soil, rocks, diet or work places. Kidney failure is nowadays increasing at an alarming rate. It is therefore a matter of concern to know if kidney can be protected especially in conditions like diabetes mellitus and persons under long drug therapy ⁽¹⁾.

The kidneys serve the body as a natural filter of the blood which removes wastes, which are diverted to the urinary bladder. In producing urine, the kidneys excrete wastes such as urea and ammonia ⁽²⁾.

Oxidative stress, resulting from an imbalance in generation of free radicals and antioxidant defense molecules, affects biological macromolecules causing their structural alterations that lead to cell damage and its death ⁽³⁾. This phenomenon is considered to be a major factor in pathogenesis of a variety of renal diseases. In this regard, reduction of oxidative stress may be a good target for prevention and treatment of renal toxicity ⁽⁴⁾. Considering hazards of treatment failure, drug resistance and heavy costs associated with renal therapy, there is strong interest in study of natural compounds with free radicals scavenging capacity ⁽⁵⁾.

Nephrotoxicity is mostly related to oxidative stress and nowadays much attention has been

made towards the possible kidney protective properties of medicinal plants and hence Flavonoids now have been great attention as they found to have protective effect on kidney ⁽⁶⁾.

Carbon tetrachloride is a colorless liquid, non-flammable and is heavier than air ⁽⁷⁾. Consequently, it has been widely used as a fire extinguisher being useful for fighting fires near electrical equipment because it does not conduct electricity ⁽⁸⁾. Carbon tetrachloride is very toxic and because of this, most of its uses in households and industries have been suspended ⁽⁷⁾.

Hesperidin is a flavanone glycoside named after the term 'hesperidium', referring to citrus fruits which are the main source of hesperidin. Hesperidin and its aglycone are common dietary flavonoids due to being large compounds of citrus fruits (*Alongside naringenin*) and especially the peels and pericarp ⁽⁹⁾.

Hesperidin is a flavonoid diglycoside (two sugars) and flavonoid monoglucosides can be absorbed in the small intestine following hydrolysis by lactase phloridzin hydrolases, or cytosolic β -glucosidases. Rutinoside glycosides (Rhamnose bound to glucose and then bound to the flavonoid) cannot be absorbed in this

manner and must proceed to the colon to be fermented prior to absorption similar to a few phenolic glycosides^(10, 11). Hesperidin appears to be absorbed topically in a manner that is significantly enhanced by menthol from peppermint⁽¹²⁾.

Hesperidine is effectively used as a supplemental agent in the treatment protocols of complementary settings. Its deficiency has been linked to abnormal capillary leakiness as well as pain in the extremities causing aches, weakness and night leg cramps. Supplemental hesperidine also helps in reducing edema or excess swelling in the legs due to fluid accumulation. A number of researchers have examined the antioxidant activity and radical scavenging properties of hesperidine using a variety of assay systems^(13,14).

MATERIALS AND METHODS

Chemicals:

Hesperidin (PubChem CID: 10621) was obtained from Sigma, Aldrich Company; CCL4: was obtained from El-Naser Pharmaceuticals Chemical Company, Egypt. Malondialdehyde and Glutathione reduced kit were obtained from Biochemical Enterprise, Italy, Glutathione reduced kit: and serum creatinine was obtained from km Diamond, USA.

Experimental animals:

40 healthy male albino rats were obtained from the animal house of Faculty of Medicine, Al-Azhar University. Their weight ranged between 180-210 grams each at the beginning of the experiment. Rats were housed in four groups with 10 rats each in clean capacious macrolane cages under standard laboratory conditions, including good aerated room with suitable temperature ($25\pm 5^{\circ}\text{C}$), maintained at good light. Standard rodent food and water were available *ad libitum*.

Experimental design:

In the present study, the animals were divided into the following groups. Each group consisted of 10 rats:

Group 1: Rats received a vehicle for hesperidin (i.e. Carboxy Methyl Cellulose) by oral route for eight days and on the 8th day, they were administered the subcutaneous injection of olive oil⁽¹⁵⁾

Group 2: Rats received vehicle for hesperidin (i.e. Carboxy Methyl Cellulose) by oral route for eight days and on the 8th day, they were

challenged with CCl₄ 2 ml/kg/s.c. (40% v/v in olive oil) on the 8th day interperitoneal⁽¹⁶⁾

Group 3: Rats received hesperidin 100 mg/kg/p.o. daily continuously for 8 days. On the eighth day just after hesperidin treatment they received CCl₄ 2ml/kg/s.c in olive oil (40% v/v in olive oil). hesperidin was further continued for 2 more days⁽¹³⁾

Group 4: Rats received only hesperidin 200 mg/kg/p.o. daily continuously for 8 days. On eight day just after hesperidin treatment they received CCl₄ 2ml/kg/s.c in olive oil (40% v/v in olive oil). hesperidin was further continued for 2 more days⁽¹⁵⁾

Biochemical studies:

48 hours after the last CCl₄ injection, rats were sacrificed and blood samples were collected, centrifuged and the serum from each animal was kept in epindorff tubes in the deep freezer at -80°C until analyzed for determination of the serum levels of the

Melondialdehyde, Glutathione, Superoxide dismutase, and Creatinine.

Histopathological studies:

The control and treated rats were sacrificed and kidney were excised out and immediately fixed in alcoholic Bouin's solution for 24 hours. These tissues were dehydrated in ascending concentrations of ethyl alcohol, cleared in xylol and embedded in paraffin wax. Transverse sections were cut at 5μ and stained with Harri's haematoxylin and eosin. Finally, the slides were microscopically examined and photographed using camera mounted on light microscope.

Statistical analysis: The data recorded were entered to the computer and analyzed by using Statistical Package for the Social Sciences (SPSS) for Windows version 15.0.

RESULTS

The present results are summarized in tables 1-7

1-The effect of hesperidin on CCl₄-induced biochemical changes:

Group 1- Values of the parameters of control group I that received orally 0.5% sodium carboxy methyl cellulose (CMC): The Glutathione level ranged from 4.8-5.3 mg/g. tissue with a mean value of 5.088 ± 0.06 mg/gm .tissue. The superoxide dismutase level ranged from 106.5-110 U/g. tissue with a mean value of 107.888 ± 0.56 U/gm. tissue. The malondialdehyde level ranged from 46.8-55 nmol/gm. tissue with a mean value of 49.013 ± 1.03 nmol/gm. tissue - The superoxide dismutase level ranged from 106.5-110 U/gm

.tissue with a mean value of 107.888 ± 0.56 U/g. tissue, and the serum creatinine level ranged from 0.62 - 1.17 mg/dL, with a mean value of 0.864 ± 0.058 mg/dL

Group 2- Values of the parameters of control group II that received orally 0.5% sodium carboxy methyl cellulose (CMC) (vehicle) with a single injection of CCl₄ intraperitoneally:

The glutathione level ranged from 2.65 - 3.1mg/g. tissue, with a mean value of 2.88 ± 0.048 mg/gm. tissue. The superoxide dismutase level ranged from 88-91 U/gm .tissue with a mean value of 89.688 ± 0.45 U/gm. tissue, the malondialdehyde level ranged from 79-85.5 nmol/gm. tissue with a mean value of 82.763 ± 0.91 nmol/gm. tissue, The serum creatinine level ranged from 1.15 -1.22 mg/dL, with a mean value of 1.063 ± 0.082 mg/dL

Group 3- Values of the parameters of the group III that received orally hesperedin 100mg/kg/day for 10 days with a single injection of CCl₄ intraperitoneally:

The glutathione level ranged from 2.8 -3.4 mg/gm .tissue, with a mean value of 3.09 ± 0.067 mg/gm. tissue. The superoxide dismutase level ranged from 89.5 -92 U/g. tissue with a mean value of 90.863 ± 0.26 U/g. tissue. The malondialdehyde level ranged from 78 -84 nmol/gm. tissue with a mean value of 81.625 ± 0.68 nmol/gm. tissue -The serum creatinine level ranged from 0.8 -1.13 mg/dL, with a mean value of 1.024 ± 0.039 mg/dL

Group 4-Values of the parameters of the group III that received orally hesperedin 200mg/kg/day for 10 days with a single injection of CCl₄ intraperitoneally:

The glutathione level ranged from 4.8 -5.4 mg/gm .tissue with a mean value 5.025 ± 0.072 mg/gm tissue. The superoxide dismutase level ranged from 101 -113 U/gm .tissue with a mean value of 107.013 ± 1.77 U/gm .tissue. The malondialdehyde level ranged from 49 -52.1 nmol/gm .tissue with a mean value of 50.2 ± 0.38 nmol/gm. tissue. The serum creatinine level ranged from 0.66 -1.37 mg/dL with mean value of 0.936 ± 0.09 mg/dL

Histopathological observations

Group 1- Histological examination of the the negative control adult albino rat which were fed 5% carboxymethyl cellulose (as a vehicle) only for 10 days and were injected by olive oil S.C in the 8th day showing severe histopathological lesions in most renal cells represented by severe atrophy and destruction in the glomeruli with

appearance of many pyknotic nuclei, infiltration of polymorph leukocytes, necrotic areas encapsulated by fibrous tissue and leukocytes forming neoplastic cyst. Necrotic renal tubules are also observed (**Figure 1**).

Group 2- Histological examination of the positive control group Which were fed 5% carboxymethyl cellulose (as a vehicle) only for 10 days and were injected by CCl₄ in olive oil(2ml/kg) S.C in the 8th day showing no histopathological lesions were observed this group (**Figure 2**).

Group 3: Histological examination of the rat kidney of rats treated with Hesperidine (HDN) as 100mg/kg in the vehicle for 10 days and were injected by CCl₄ in olive oil (2ml/kg) S.C in the 8th day showed moderate histopathological lesions in most renal cells represented by distorted cubical cells of the distal convoluted tubules and lobulated glomeruli compared to the control positive group with less inflammatory cellular infiltration and more viable cells of the proximal convoluted tubules than the control positive group (**Figure 3**).

Group 4: Histological examination of the rat kidney group treated with Hesperidine (HDN) as 200mg/kg in the vehicle for 10 days and were injected by CCl₄ in olive oil (2ml/kg) S.C in the 8th day showed reduced histopathological lesions in most renal cells especially those of the distal convoluted tubules ,but lobulated or atrophied glomeruliare still detected (**Figure 4**).

DISCUSSION

Flavanoids have main role in the treatment of renal toxicities caused by long usage of antibiotics, immunosuppressant and toxicity related to ccl4. Hence flavonoids can be regarded as the most efficient agents for kidney protection. Renal failure has become a serious problem so it is of prime importance now that it should be controlled by a more authentic and more efficient way i.e.to have proper flavanoids in our diet.

Hesperidin is an abundant flavonoid found in citrus fruit. It is the predominant flavonoid in lemons and oranges. Hesperidin, a citrus bioflavonoid, decreases the oxidative stress produced by carbon tetrachloride in rat liver and kidney ⁽⁶⁾.

Kidney is an important organ for metabolism, detoxification, storage and excretion of xenobiotics and their metabolites and it is especially vulnerable to damage ⁽¹⁷⁾.

In general, a number of chemicals including various environmental toxicants and even clinically useful drugs can cause severe cellular damages in different organs of the body through metabolic activation to highly reactive substances such as free radicals⁽¹⁸⁾. CCl₄ is one of such widely used environmental toxicant to experimentally induce animal models of acute nephrotoxicity⁽¹⁹⁾.

Histopathological studies of Kidney revealed that the acute cellular degeneration or atrophy in the epithelial lining of the renal tubules is due to toxic effect of CCl₄ which may be caused by cell membrane injury or effect on mitochondria, this effect may leads to depletion of adenosine triphosphate (ATP) or defect in sodium-potassium pump, this leads to fluid disturbance in and outside the cell^(20, 21). This lesion may return to cellular degeneration as well as increasing the amount of edematous fluid in the interstitial substance⁽²²⁾.

The present results showed that oral administration of hesperidin (100mg/kg and 200mg/kg) improved renal architecture microscopically in a dose-dependent manner. Hesperidin 100mg/kg showed a slight improvement of the CCl₄-induced damage, while hesperidin 200mg/kg prevents the CCl₄-induced damage in the renal tubules. The results showed no difference in the renal tubules in the CCl₄ treated group which received hesperidin 200mg/kg as compared to the normal control group, However, glomeruli were still atrophied or lobulated. These results are in agreement with those of **Pari et al.**; **Etim et al.** and **Anandan and Subramanian**^(1, 6, 23).

The results of the present study showed insignificant increase of serum creatinine in CCl₄ intoxicated group and results of the present study are in agreement with those of **Zimmerman et al.**⁽²⁴⁾ who did not report any rise in kidney functions levels even after chronic treatment of CCl₄ in nephrectomized rats (uninephrectomy). Increased frequency of glomerulosclerosis and tubulointerstitial alterations was found in rats with reduced renal mass by CCl₄ administration thereby indicating nephrotoxicity only on long-term CCl₄ administration in rats⁽²²⁾.

The results of the present study are in disagreement with those of **Ogawa et al.**⁽²³⁾ who noticed an increase in kidney function in CCl₄-induced nephrotoxicity and **Stephen et al.**⁽²²⁾, who reported that the nephrotoxicity can be detected by kidney functions tests. Case control studies and various documented case reports

increasingly established that hydrocarbon solvents produce renal diseases in humans⁽²³⁾. To assess renal affection by detection of renal functions, serum samples were assayed for serum creatinine⁽²⁴⁾.

Kidney tissue has a great affinity for CCl₄ because of the predominant presence of the cytochrome p450 in the cortex. A previous reports suggested that CCl₄ generates free radicals with the implication of pathological environment by damaging the integrity of cell membranes, elevating thiobarbituric acid, reactive substances (TBARS) level with subsequent necrosis and affecting physical parameters of kidney such as urinary and serum profile⁽²⁵⁾.

Renal sources of reactive oxidative stress (ROS) caused an increase in macrophages, vascular cells, and various glomerular cells. ROS may affect cells of the host organism, especially at sites of inflammation in addition to playing a role in the defense system against other agents. This effect plays a role in a variety of renal diseases such as glomerulonephritis and tubulointerstitial nephritis which can contribute to proteinuria and other conditions⁽²⁶⁾.

The presence of inflammation is well documented factor influencing the development of oxidative stress in dialysis patients⁽²⁷⁾. However the pathology related with renal function failure which is stimulated by CCl₄ remains controversial⁽²⁸⁾.

Kodama et al. and **Prakash et al.**^(29- 34) obtained similar results to our study on the effect of CCl₄ on kidney architecture.

In the present study induction of acute nephrotoxicity in Wistar male albino rats was done by injection of CCl₄ 2 ml/kg/ (40% v/v in olive oil) for a single dose which is well characterized model for acute nephrotoxicity where degenerated glomeruli and lots of pyknotic nuclei were observed. Obliteration of the tubules, inflammatory cell infiltration with damaged cells of the renal tubules were also realized.

These results are in agreement with the results obtained by **Abdel Moneim and Mahmoud**⁽³⁵⁾ who reported that CCl₄ induced nephrotoxicity which can be detected by estimation of oxidation and antioxidation components plus histopathological changes.

The results of the present study are in disagreement with the results obtained by **Zimmerman et al.**⁽²⁴⁾ as they found increased frequency of glomerulosclerosis and tubulointerstitial alterations with reduced renal

mass only on long-term CCl₄ administration in rats.

In conclusion, The results of the present study showed that hesperidin (200 mg/kg) successfully attenuated the nephrotoxic effects of CCl₄ in rats. This protective role of hesperidin may be due to its free radical scavenging potential.

REFERENCES

- Pari L, Karthikeyan, A, Karthika P and Rathinam A (2015):** Protective effects of hesperidin on oxidative stress, dyslipidaemia and histological changes in iron-induced hepatic and renal toxicity in rats. *Toxicology Reports*, 2: 46–55.
- Raghavendra M and Vidya MJ (2013):** Functions of kidney and artificial kidneys. *International Journal of Innovative Research*, 1 (11):1-5.
- Ryter SW, Kim HP, Hoetze A, Park JW, Nakahira K, Wang X and Choi AM. (2007):** Mechanisms of cell death in oxidative stress. *Antioxid. Redox Signal*, 9(1):49-89.
- Flora SJS, Bhadauria S, Kannan GM and Singh N. (2007):** Arsenic induced oxidative stress and the role of antioxidant supplementation during chelation: a review. *J. Environ. Biol.*, 28: 333–347.
- Aggarwal B, Sundaram C, Malani N and Ichikawa H (2007):** Curcumin: the Indian solid gold. *Adv. Exp. Med. Biol.*, 595: 1–75.
- Dahal A and Mulukuri S (2015):** Review article: flavonoids in kidney protection. *World Journal of Pharmacy and Pharmaceutical Sciences*, 4(3): 362-382.
- Etim OE, Akpan EJ and Usoh IF (2008):** Hepatotoxicity of carbon tetrachloride: protective effect of *Gongronema latifolium*. *Pakistan Journal of Pharmaceutical Sciences*. 21(3):268-274.
- The World Book Encyclopedi (1992):** World Book Inc. Chicago. pp: 366-377.
- Kanes K, Tisserat B, Berhow M and Vandercook C (1993):** Phenolic composition of various tissues of rutaceae species. *Phytochemistry*, 32: 967–974.
- Németh K, Plumb GW and Berrin JG (2003):** Deglycosylation by small intestinal epithelial cell β -glucosidases is a critical step in the absorption and metabolism of dietary flavonoid glycosides in humans. *Eur. J. Nutr.*, 42:29–42.
- Jin MJ, Kim U, Kim IS, Kim Y, Kim DH, Han SB, Kim DH, Kwon OS and Yoo HH (2010):** Effects of gut microflora on pharmacokinetics of hesperidine: a study on non-antibiotic and pseudo-germ-free rats. *J. Toxicol. Environ. Health*, 73:1441-1450.
- Wang X, Sakurai T and Chen X, (2008):** Hydrolysis of flavanone glycosides and degradation of the corresponding aglycones from dried immature citrus fruit by human fecal flora *in vitro*. *Planta Med.*, 74(14):1751-1755.
- Jovanovic SV, Steenken S, Tosic M, Marjanovic B and Simic MG (1994):** Flavonoids as anti-oxidants. *J Am Chem Soc.*; 116:4846–4851.
- Suarez Herrera MD and Marhuenda E (1998):** In vitro scavenger and antioxidant properties of hesperidine and neohesperidine dihydrochalcone. *Phytomedicine*:469–473.
- Tirkey N, Pilkhwal S, Kuhad A and Chopra K (2005):** Hesperidin, a citrus bioflavonoid, decreases the oxidative stress produced by carbon tetrachloride in rat liver and kidney. *B.M.C. Pharmacology*, 5:2-7.
- Mandal AK, Sinha J, Mandal S, Mukhopadhyay S and Das N (2002):** Targeting of liposomal flavonoid to liver in combating hepatocellular oxidative damage. *Drug Deliv.*, 9:181-185.
- Omar AMS (2013):** Histopathological and physiological effects of liver and kidney in rats exposed to cadmium and ethanol. *Global Advanced Research Journal of Environment*, 2(3): 93-106.
- Noguchi T, Fong KL, Lai EK, Alexander S S, King MM, Olson L, Poyer JL and Mccay P B (1982):** Specificity of aphenobarbital-induced cytochrome P450 for metabolism of carbon tetrachloride to the trichromethyl radical. *Biochem. Pharmacol.*, 31: 615-624.
- Adewole SO, Salako AA, Doherty OW and Naicker T (2007):** Effect of melatonin on carbon tetrachloride- induced kidney injury in Wistar rats. *African Journal of Biomedical Research*, 10: 153 – 164.
- Guyton AC (2001):** Medical Physiology, W.B. Saunders Company, Philadelphia, p.1152.
- Gunong WF (1983):** Review of Medical Physiology, 11th Edition, Lange Medical Publication, California.
- Balahoroğlu R, Dülger H, Özbek H, Bayram İ and Şekeroğlu MR (2008):** Protective effects of antioxidants on the experimental liver and kidney toxicity in mice. *Eur. J. Gen. Med.*, 5(3):157-164.
- Anandan R and Subramanian P (2012):** Effects of hesperidin on the levels of circulatory lipid peroxidation products and liver marker enzymes in gentamicin treated rats. *J. Pharm. Res.*, 5: 2114-2116.
- Zimmerman SW, Norback DH and Powers K (1983):** Carbon tetrachloride nephrotoxicity in rats with reduced renal mass. *Arch. Pathol. Lab. Med.*, 107:264-269.
- Ogawa M, Mori T, Mori Y, Ueda S, Azemoto R and Makino Y. (1992):** Study on chronic renal injuries induced by carbon tetrachloride: selective inhibition of the nephrotoxicity by irradiation. *Nephron*, 60:68-73.
- Stephen O A, Salako AA, Doherty OW and Naicker T (2007):** Effect of melatonin on carbon tetrachloride- induced kidney injury in Wistar Rats *African Journal of Biomedical Research*, 10:153 – 164.

27. **Ruprah H, Mant T. G. K, Flanagan R J (1985):** Acute carbon tetrachloride poisoning in 19 patients: implications for diagnosis and treatment. *Lancet.*, 1: 1027-1029.
28. **Bhattacharya H, Gomez G D R and Lun L (2005):** Biochemical effects to toxicity of CCl₄ on rosy barbs". *Our Nature*, 3:20-25.
29. **Sahreen S, Siddiq P, Shah N A, Khan M R and Khan RA (2013):** Modulation of carbon tetrachloride-induced nephrotoxicity in rats by n-hexane extract of *Sonchus asper* . *Toxicol. Ind. Health*, 4:80-94.
30. **Ichikawa I, Kiyama S and Yoshioka T (1994):** Renal antioxidant enzymes: their regulation and function. *Kidney Int.*, 45: 1–9.
31. **Samouilidou EC and Grapsa E J (2003):** Oxidative stress markers and C-reactive protein in end-stage renal failure patients on dialysis. *Int. Urol. Nephrol.*, 35 (3): 393-397.
32. **Ogeturk M, Kus I, Colakoglu N, Zararsiz I, Ilhan N and Sarsilmaz M (2005):** Caffeic acid phenethyl ester protects kidneys against carbon tetrachloride toxicity in rats. *J.Ethnopharmacol.*, 97:273-280.
33. **Kodama K, Oguchi K and Tsuji M (1990):** Protective effect of S-adenosyl-L-methionine against CCl₄-induced hepatotoxicity in cultured hepatocytes. *J. Pharmacol.*, 52(2):209-214.
34. **Prakash T, Fadadu S D, Sharma U R, Surendra V and Goli D (2008):** Hepatoprotective activity of leaves of *Rhododendron arboreum* in CCl₄ induced hepatotoxicity in rats. *Journal of Medicinal Plants Research*, 2 (11): 315–320.
35. **Abdel Moneim A E and Mahmoud S M (2013):** The Protective effect of pomegranate (*Punica granatum*) juice against carbon tetrachloride-induced oxidative stress in brain tissue of adult male albino rats. *Life Sci. J.*, 10(1):151-158.

Table 1- The effect of hesperedin treatment on CCl₄-induced changes in oxidants, antioxidants and serum enzymes parameters ,

Parameters		Group			
		Group-I Vehicle treated	Group- II CCL4 treated	Group- III Hesperidine (100mg/kg) + CCL4 treated	Group- IV Hesperidin (200mg/kg) +CCL4 treated
Melondialdehyde (mg/g tissue)	Mean ± S.E	49.013±1.03	82.763±0.91	81.625±0.68	50.2±0.38
Glutathione (mg/g tissue)	Mean ± S.E	5.088±0.06	2.88±0.048	3.09±0.067*	5.025±0.072*
Superoxide dismutase (mg/g tissue)	Mean ± S.E	107.888±0.56	89.688±0.45	90.863±0.26*	107.013±1.77
Serum Creatinine (mg/dL)	Mean ± S.E	0.864±0.058	1.063±0.082	1.024±0.039*	0.936±0.09*

Table 2- Comparison between group I (No SC injection of CCl₄+no HDN administration) and groupIII (SC injection of CCl₄+HDN 100)

	GROUP I CONTROL-VE Vehicle treated	GROUP III Hesperidin(100mg/kg) CCL4 treated
<i>Glutathione</i>	5.088±0.06 mg/g.tissue	3.09±0.067 mg/g.tissue*
<i>Superoxide dismutase</i>	107.888±0.56 U/g.tissue	90.863±0.26 U/g.tissue*
<i>Malondialdehyde</i>	49.013±1.03 nmol/g.tissue	81.625±0.68 nmol/g.tissue*
<i>Serum Creatinine</i>	0.864±0.058 mg/dL	1.024±0.039 mg/dL

* Means statistical significance at P < 0.05 as compared to group I

** means P < 0.001 which indicates high significance as compared to group I.

Table 3 - Comparison between group I (vehicle treated) and group IV (CCL₄+Hesperidine 200mg treated)

	GROUP I CONTROL-VE Vehicle treated	GROUP IV Hesperidine(200mg/kg) + CCL4 treated
<i>Glutathione</i>	5.088±0.06 mg/g.tissue	5.025±0.072 mg/g.tissue
<i>Superoxide dismutase</i>	107.888±0.56 U/g.tissue	107.013±1.77 U/g.tissue
<i>Malondialdehyde</i>	49.013±1.03 nmol/g.tissue	50.2±0.38 nmol/g.tissue*
<i>Serum Creatinine</i>	0.864±0.058 mg/d	0.936±0.09mg/d*

* Means statistical significance at P < 0.05 as compared to group I.

Table 4 - Comparison between group II (SC injection of CCL₄+no HDN administration) and group III (SC injection of CCL₄+HDN 100)

	GROUP II CONTROL+VE CCL₄ treated	GROUP III Hesperidine(100mg/kg) + CCL₄ treated
<i>Glutathione</i>	2.88±0.048 mg/g.tissue	3.09±0.067 mg/g.tissue **
<i>Superoxide dismutase</i>	89.688±0.45 U/g.tissue	90.863±0.26 U/g.tissue**
<i>Malondialdehyde</i>	82.763±0.91 nmol/g.tissue	81.625±0.68 nmol/g.tissue
<i>Serum Creatinine</i>	1.063±0.082mg/dL	1.024±0.039 mg/dL

* Means statistical significance at P < 0.05 as compared to group II

Table 5 - Comparison between group II (SC injection of CCL₄+no HDN administration) and group IV (SC injection of CCL₄+HDN 200)

	GROUP II CONTROL+VE , CCL₄ treated	GROUP IV Hesperidine(200mg/kg) +CCL₄ treated
<i>Glutathione</i>	2.88±0.048 mg/g.tissue	5.025±0.072 mg/g.tissue**
<i>Superoxide dismutase</i>	89.688±0.45 U/g.tissue	107.013±1.77 U/g.tissue**
<i>Malondialdehyde</i>	82.763±0.91 nmol/g.tissue	50.2±0.38 nmol/g.tissue**
<i>Serum Creatinine</i>	1.063±0.082mg/dL	0.936±0.09mg/dL **

* Means statistical significance at P < 0.05 as compared to group II and

** means P < 0.001 which indicates high significance as compared to group II.

Table 6- Comparison between group I (vehicle treated)&group II (CCL₄ treated)

	GROUP I ONTROL-VE Vehicle treated	GROUP II CONTROL+VE, CCL₄ treated
<i>Glutathione</i>	5.088±0.06 mg/g.tissue	2.88±0.048 mg/g.tissue**
<i>Superoxide dismutase</i>	107.888±0.56 U/g.tissue	89.688±0.45 U/g.tissue**
<i>Malondialdehyde</i>	49.013±1.03 nmol/g.tissue	82.763±0.91 nmol/g.tissue**
<i>Serum Creatinine</i>	0.864±0.058 mg/dL	1.063±0.082mg/dL***

* Means statistical significance at P < 0.05 as compared to group I ,

** means P < 0.001 which indicates high significance as compared to group I.

***P < 0.0001 which indicates very high significance as compared to group I

Table 7- Comparison between group III (CCL₄+hesperidin 100 mg treated) and group IV (CCL₄+Hesperidine 200 mg treated)

	GROUP III Hesperidin 100mg/kg)+ CCL₄ treated	GROUP IV Hesperidin (200mg/kg) + CCL₄ treated
<i>Glutathione</i>	3.09±0.067mg/g.tissue	5.025±0.072 mg/g.tissue**
<i>Superoxide dismutase</i>	90.863±0.26 U/g.tissue	107.013±1.77 U/g.tissue**
<i>Malondialdehyde</i>	81.625±0.68 nmol/g.tissue **	50.2±0.38 nmol/g.tissue**
<i>Serum Creatinine</i>	1.024±0.039 mg/dL	0.936±0.09mg/dL

* Means statistical significance at P < 0.05 as compared to group III .

** means P < 0.001 which indicates high significance as compared to group III.

Kidney tissue of the -group 1-control negative

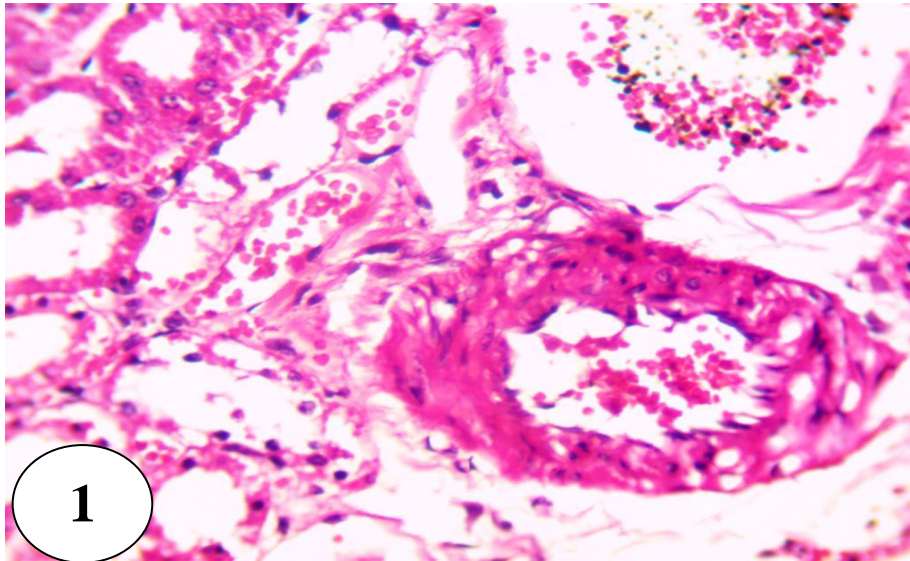


Fig.1: A photomicrograph of magnified section of kidney cortex of a rat of the negative control adult albino rat which were fed 5% carboxymethyl cellulose (as a vehicle) only for 10 days and were injected by olive oil S.C in the 8th day showing severe histopathological lesions in most renal cells represented by severe atrophy and destruction in the glomeruli with appearance of many pyknotic nuclei, infiltration of polymorph leukocytes, necrotic areas encapsulated by fibrous tissue and leukocytes forming neoplastic cyst. Necrotic renal tubules are also observed (H&E x400).

Kidney tissue of the -group 2-control positive

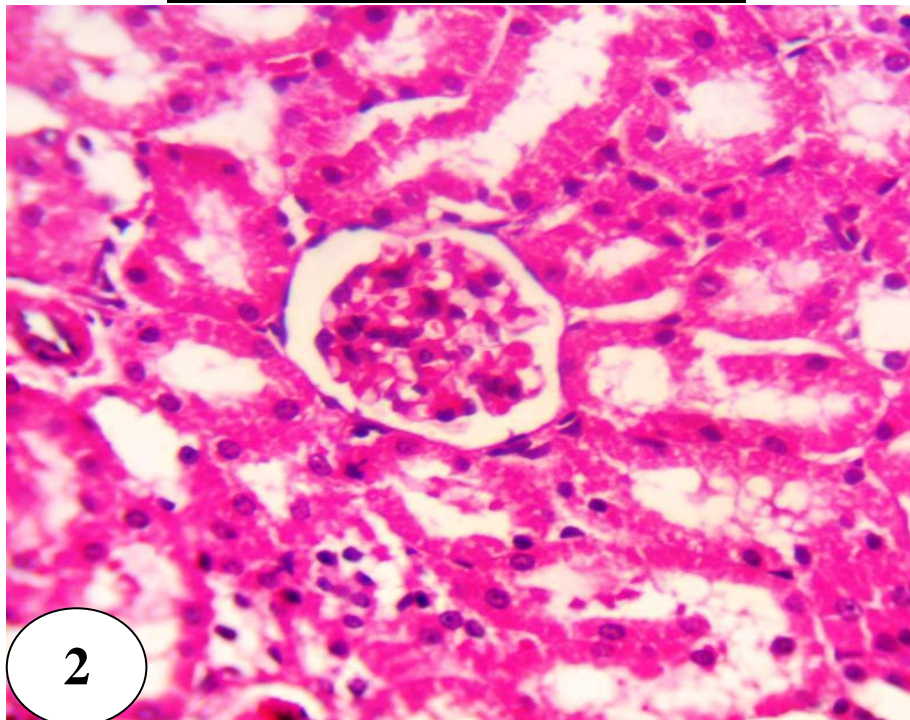


Fig.2: A photomicrograph of magnified section of kidney of Group 2 control +ve) Which were fed 5% carboxymethyl cellulose (as a vehicle) only for 10 days and were injected by CCl₄ in olive oil(2ml/kg) S.C in the 8th day showing no histopathological lesions were observed this group (H&E x400).

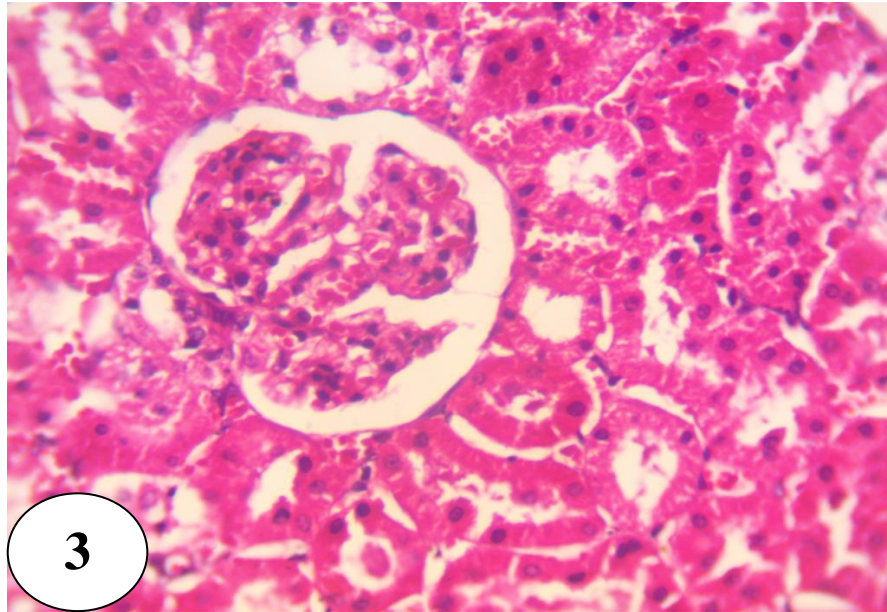


Fig.3: A photomicrograph of kidney cortex of a rat Group 3 treated with Hesperidine (HDN) as 100mg/kg in the vehicle for 10 days and were injected by CCl₄ in olive oil (2ml/kg) S.C in the 8th day showed moderate histopathological lesions in most renal cells represented by distorted cubical cells of the distal convoluted tubules and lobulated glomeruli compared to the control positive group with less inflammatory cellular infiltration and more viable cells of the proximal convoluted tubules than the control positive group (H&E x400).

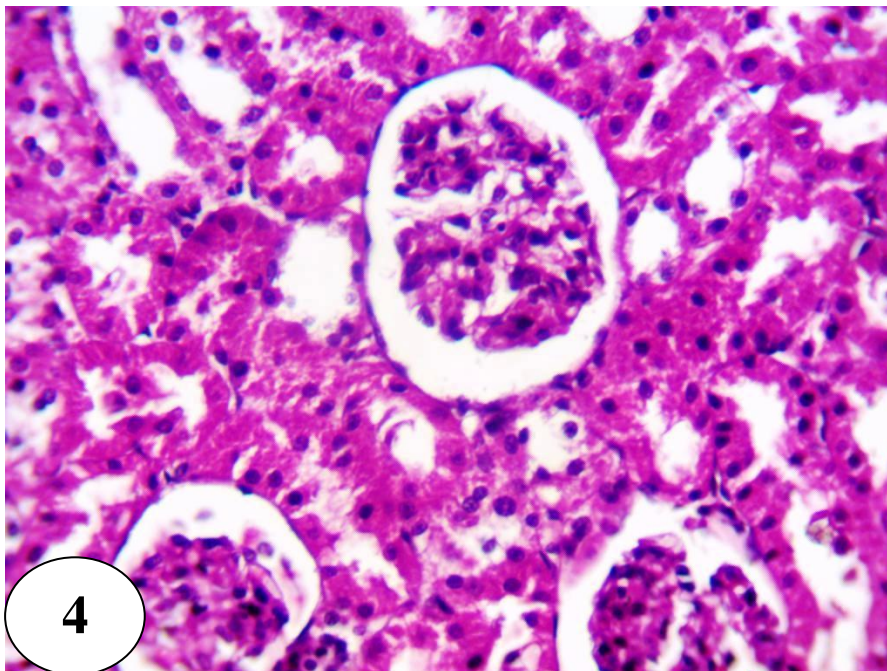


Fig.4: A photomicrograph of kidney cortex of a rat Group 4 treated with Hesperidine (HDN) as 200mg/kg in the vehicle for 10 days and were injected by CCl₄ in olive oil (2ml/kg) S.C in the 8th day showed reduced histopathological lesions in most renal cells especially those of the distal convoluted tubules ,but lobulated or atrophied glomeruli are still detected (H&E x400).